



Australian Government
Rural Industries Research and
Development Corporation

Equine Laminitis

Current Concepts

by Chris Pollitt
08/062



RIRDC Innovation for rural Australia



Australian Government

**Rural Industries Research and
Development Corporation**

Equine Laminitis

Current Concepts

by Christopher C. Pollitt

May 2008

RIRDC Publication No 08/062

RIRDC UQ-118A

© 2008 Rural Industries Research and Development Corporation.
All rights reserved.

ISBN 1 74151 651 X
ISSN 1440-6845

Equine laminitis – Current Concepts

Publication No. 08/062
Project No. RIRDC UQ-118A.

The information contained in this publication is intended for general use to assist public knowledge and discussion and to help improve the development of sustainable regions. You must not rely on any information contained in this publication without taking specialist advice relevant to your particular circumstances.

While reasonable care has been taken in preparing this publication to ensure that information is true and correct, the Commonwealth of Australia gives no assurance as to the accuracy of any information in this publication.

The Commonwealth of Australia, the Rural Industries Research and Development Corporation (RIRDC), the authors or contributors expressly disclaim, to the maximum extent permitted by law, all responsibility and liability to any person, arising directly or indirectly from any act or omission, or for any consequences of any such act or omission, made in reliance on the contents of this publication, whether or not caused by any negligence on the part of the Commonwealth of Australia, RIRDC, the authors or contributors.

The Commonwealth of Australia does not necessarily endorse the views in this publication.

This publication is copyright. Apart from any use as permitted under the *Copyright Act 1968*, all other rights are reserved. However, wide dissemination is encouraged. Requests and inquiries concerning reproduction and rights should be addressed to the RIRDC Publications Manager on phone 02 6271 4165.

Researcher Contact Details

Professor Chris Pollitt
Professor of Equine Medicine
School of Veterinary Science
The University of Queensland
St Lucia, Brisbane, Queensland
AUSTRALIA

Email: c.pollitt@uq.edu.au
Web: www.laminitisresearch.org

Mobile: 0419 721 682
Fax: 07 3365 2351

In submitting this report, the researcher has agreed to RIRDC publishing this material in its edited form.

RIRDC Contact Details

Rural Industries Research and Development Corporation
Level 2, 15 National Circuit
BARTON ACT 2600
PO Box 4776
KINGSTON ACT 2604

Phone: 02 6271 4100
Fax: 02 6271 4199

Email: rirdc@rirdc.gov.au
Web: <http://www.rirdc.gov.au>

Published in May 2008
Printed by Union Offset, Canberra

Foreword

The horse industry makes a significant economic and cultural contribution to Australia, and the maintenance of horse health and welfare is a primary concern of owners, trainers and veterinarians alike. Laminitis is a painful and devastating disease that can cripple a horse and end its productive life. There has been a considerable amount of research over recent years to try to understand laminitis, but scientists have struggled to reconcile the wide range of apparently unrelated factors which can trigger the condition.

This report describes four research projects that initially focussed on the developmental and acute stages of laminitis. The research teams involved in these projects included microbiologists, molecular biologists, pathologists, electron microscopists, physiologists and endocrinologists, and this unique critical mass has enabled significant contributions to the understanding of laminitis. As new knowledge accrued a successful preventive strategy, employing distal limb cryotherapy, was developed that is now the only scientifically proven laminitis preventive.

The importance of this report is that it provides an overview of laminitis for horse owners, veterinarians and scientists. It describes the anatomy, physiology and ultrastructure of the horse's foot to form a basis for understanding the complex pathology that underpins the disease. It describes the radiology of the horse's foot and introduces the new technique of retrograde venography.

This report, an addition to RIRDC's diverse range of over 1800 research publications, forms part of our Horse R&D Program, which aims to assist in developing the Australian horse industry and enhancing its export potential.

Most of our publications are available for viewing, downloading or purchasing online through our website:

- downloads at www.rirdc.gov.au/fullreports/index.html
- purchases at www.rirdc.gov.au/eshop

Peter O'Brien

Managing Director

Rural Industries Research and Development Corporation

Acknowledgments

The author gratefully acknowledges the hard work and cheerful collaboration of the post graduate students and colleagues whose names appear in the following list of laminitis research publications and whose research has thus contributed to the production of this book.

Contents

Foreword.....	iii
Acknowledgments.....	iv
Executive Summary	x
1. Introduction	1
1.1 The Problem of Laminitis.....	1
1.2 Laminitis Research	2
1.3 Key Points	2
2. The Horse's Foot	3
2.1 Foot structure and function.....	4
2.2 Hoof growth	5
2.3 Hoof wall tubules	7
2.4 The corium	8
2.4.1 The coronary corium	9
2.4.2 The lamellar corium - distal phalanx attachment apparatus	9
2.5 Key Points	10
3. Lamellar Anatomy	11
3.1 The lamellae of the inner hoof wall.....	11
3.2 Secondary epidermal lamellae.....	12
3.3 The basement membrane.....	12
3.4 Hemidesmosomes.....	13
3.5 Basal cell cytoskeleton	14
3.6 Hoof wall growth	15
3.7 Lamellar remodeling enzymes	17
3.8 Lamellar metabolism.....	18
3.9 Key Points	18
4. Laminitis in Perspective.....	19
4.1 The laminitis literature	19
4.2 The developmental phase	19
4.3 The acute phase	19
4.4 The chronic phase.....	20
4.5 The Obel grades of lameness.....	21
4.6 Laminitis is a sequel to an event remote from the foot	21
4.7 Grass founder	22
4.8 Grain founder	22
4.9 Alimentary carbohydrate overload model	22
4.10 Use of Virginiamycin to prevent laminitis	24
4.11 Lamellar blood flow etiology	24
4.12 Vasoconstriction theories	24
4.13 Vasodilation theories.....	24
4.14 Vasodilation is associated with laminitis	25
4.15 Key Points	26
5. Laminitis: Current Concepts.....	27
5.1 Introduction	27
5.2 The laminitis process.....	27
5.3 A histological grading system for laminitis.....	29
5.3.1 Grade 1 histological laminitis.....	29
5.3.2 Grade 2 histological laminitis.....	31
5.3.3 Grade 3 histological laminitis.....	32
5.4 Lamellar blood vessels	33
5.5 Laminitis ultrastructure	34
5.6 An enzymatic theory of laminitis	35
5.7 Laminitis <i>in vitro</i>	36

5.8 Laminitis and metalloproteinase enzyme activity	37
5.9 Laminitis causes increased gene transcription of lamellar enzymes	38
5.10 Metalloproteinase inhibitors.....	38
5.11 The search for natural laminitis trigger factors	39
5.12 Key Points	39
6. Insulin and laminitis.....	40
6.1 Changes in insulin metabolism as a trigger for laminitis	40
6.2 Equine metabolic syndrome	40
6.3 Equine Cushing's disease.....	41
6.4 Hyperlipaemia	42
6.5 Supporting limb laminitis	42
6.6 Key Points	42
7. The Clinical Signs of Laminitis	43
7.1 Acute laminitis	43
7.2 Early chronic laminitis	45
7.2.1 Coronary band changes	45
7.2.2 Sole changes.....	45
7.2.3 Hoof wall changes.....	46
7.2.4 Hoof wall lamellar changes.....	47
7.3 Severe chronic laminitis	48
7.4 Conclusions	53
7.5 Key Points	54
8. Radiology of laminitis	55
8.1 Radiographic technique.....	55
8.2 Radiology of acute/early chronic laminitis.....	56
8.3 The rate at which the HDPD increases correlates with the severity of the acute lesion.....	57
8.4 Key points	60
9. Venography of laminitis.....	61
9.1 Introduction	61
9.2 Venographic technique.....	63
9.3 Venography of acute/early chronic laminitis	65
9.4 Digital radiography and venograms	68
9.5 Key Points	68
10. Laminitis Medical Therapy	69
10.1 Laminitis therapy.....	69
10.2 Cryotherapy	69
10.3 Cryotherapy: potential mechanisms for preventing lamellar damage	70
10.4 Efficacy of continuous distal limb cryotherapy for the prevention of acute laminitis	71
10.4.1 Experimental data.....	71
10.4.2 Clinical data.....	72
10.4.3 Application methods.....	73
10.5 Management practices to avoid pasture associated laminitis.	74
10.6 Pasture factors	74
10.7. Horse factors.....	75
10.8 Endotoxaemia therapy	76
10.9 Vasodilator therapy	76
10.10 Free radical scavengers	76
10.11 A recommended treatment strategy	77
10.12 Key Points	77

11. Therapeutic Shoeing.....	78
11.1 Introduction	78
11.2 Mechanical support of the distal phalanx	78
11.3 Foam sole support	78
11.4 The Steward Clog.....	80
11.5 Digital support shoes	82
11.6 The heart-bar shoe (HBS).....	82
11.7 Construction of the heart-bar shoe	83
11.8 Heel elevation.....	85
11.9 The Equine Digit Support System.....	86
11.10 Heart-bar support shoe	87
11.11 Hoof wall resection	89
11.12 Deep flexor tenotomy	90
11.13 Key Points	90
12. Prognosis and Future Directions.....	91
12.1 Future Directions.....	92
12.2 Key Points	92
13. References	93
Appendix 1 Farrier Supplies	96
Clarke Horseshoes Pty Ltd.....	96
Combined Farrier Supplies.....	96
Grinter Wholesale Trading Pty Ltd.....	96
Hooftech Pty Ltd	96
Independent Farrier Supplies Pty Ltd.....	96
O’Dwyer Horseshoe Aust Pty Ltd.....	96
Saddlery Wholesalers Pty Ltd	96
Stockmans Supplies Pty Ltd.....	96
Appendix 2	97
RMAX (manufacturer of beaded polystyrene foam products).....	97
Addresses of suppliers:.....	97
Halas Dental Ltd (Coltene Lab Putty).....	97
Addresses and phone/fax numbers of suppliers:	97
Cryotherapy Supplies	97
Grazing Muzzle	97
Veterinary Drugs	97
Appendix 3	98
Publications and presentations associated with this research.....	98
Books and chapters in books	100

Table of figures

Figure 1-1	The gait of a horse with severe laminitis.	1
Figure 2-1	The three bones of the digit are viewed obliquely from the dorsal surface.	3
Figure 2-2	Diagram of a sagittal section of the horse's foot.	4
Figure 2-3	Diagram of the anatomy of the hoof wall.	4
Figure 2-4	Basal cell proliferation in the coronary band.	5
Figure 2-5	The growth zones of the proximal hoof wall (highlighted in red).	6
Figure 2-6	The growth zones (highlighted in red) of the distal wall, white line and sole.	6
Figure 2-7	Transverse section of a pigmented hoof wall (unstained).	7
Figure 2-8	Diagram of the coronary band.	9
Figure 2-9	Diagram of the key structures of the hoof lamellar-distal phalanx attachment apparatus.	10
Figure 3-1	Hoof with its contents removed to show the lamellae of the inner hoof wall.	11
Figure 3-2	The epidermal lamellae of the inner hoof wall.	12
Figure 3-3	The basement membrane at the dermo-epidermal junction.	13
Figure 3-4	Hemidesmosomes at the dermo-epidermal junction.	14
Figure 3-5	Diagram of hemidesmosome, the key structure attaching epidermal basal cells to the basement membrane.	14
Figure 3-6	Diagram of the cytoskeleton of an epidermal basal cell.	15
Figure 3-7	Diagram of hoof wall growth.	16
Figure 3-8	Micrograph showing immunolocalisation of matrix metalloproteinase (MMP-2) in the hoof wall lamellae.	17
Figure 4-1	A horse with acute laminitis shifting weight from one foot to the other.	20
Figure 4-2	Proppase of the distal phalanx through the sole of the foot.	20
Figure 4-3	Sagittal section of a foot with severe chronic laminitis and a large lamellar wedge.	21
Figure 4-4	Micrograph of the leaking hindgut of a horse developing carbohydrate overload laminitis.	23
Figure 4-5	Mean temperatures (\pm standard error) of hooves from laminitis positive, laminitis negative and untreated control horses.	25
Figure 5-1	Micrograph of normal hoof lamellae stained to highlight the basement membrane.	28
Figure 5-2	Grade 1 histological laminitis (H&E stain).	29
Figure 5-3	Grade 1 histological laminitis (PAS stain).	30
Figure 5-4	Grade 2 histological laminitis (PAS stain).	31
Figure 5-5	Grade 3 histological laminitis (immunostain).	32
Figure 5-6	Grade 3 histological laminitis (immunostain).	33
Figure 5-7	Transmission electron micrograph of lamellar SEL at the onset of acute laminitis.	34
Figure 5-8	Transmission electron micrograph of SEL tip at the onset of acute laminitis.	35
Figure 5-9	Zymography of normal lamellar explants.	37
Figure 5-10	Graphs showing MMP-2 gene expression (left) and zymogram of laminitis affected tissue (right).	38
Figure 6-1	Chronically foundered pony showing the typical cresty neck of Equine Metabolic Syndrome. Photo: Don Walsh.	40
Figure 6-2	Ponies with Equine Cushing's Disease fail to shed their hair coats (hirsutism).	41
Figure 7-1	Laminitis stance: forefeet.	43
Figure 7-2	The laminitis gait.	44
Figure 7-3	Coronary band changes due to severe chronic laminitis.	45
Figure 7-4	Sagittal section of the foot of the mare in Figure 7.3.	46
Figure 7-5	Chronically foundered pony with "Aladdin's slipper" feet.	46
Figure 7-6	Kinked, displaced, hoof wall tubules due to severe chronic laminitis.	47
Figure 7-7	Photomicrograph of left fore hoof lamellae 7 days after laminitis induction.	48
Figure 7-8	Venogram of foot with severe chronic laminitis: Case study "Grace".	49
Figure 7-9	Histology of normal coronary band veins (A) and veins affected by severe chronic laminitis (B).	49
Figure 7-10	Computed tomography (CT) arteriograms vs. venograms of the front feet of a horse (Case study "Grace") with severe chronic laminitis.	50
Figure 7-11	The coronary cushions of normal vs. chronic laminitis feet.	50
Figure 7-12	Normal (A) compared to severe, chronic laminitis (B) toe and terminal wall tubules. Normal tubules are straight, parallel and growing downwards in the direction of the arrow.	51
Figure 7-13	The foot of a chronically foundered horse with the hoof removed.	52
Figure 7-14	The distal phalanx of the same chronically foundered horse in Figure 7.13.	52
Figure 7-15	The foot of a horse with severe chronic laminitis of long standing.	53
Figure 8-1	Lateromedial radiograph of a normal foot.	55

Figure 8-2	Horse standing on boxes to align x-ray beam with distal phalanx.	56
Figure 8-3	Severe chronic laminitis: lateromedial radiograph.	56
Figure 8-4	Dissection of the dorsal hoof wall affected by severe acute (early chronic) laminitis.	57
Figure 8-5	Radiograph of a foot with severe, chronic laminitis of 4 weeks duration (same foot as in Figure 8.3).	58
Figure 8-6	Radiographs of normal (A) and chronic laminitis (B) distal phalanx.	59
Figure 8-7	Proximodorsal-palmarodistal ('standing') view of a foot with severe chronic laminitis.	59
Figure 9-1	Lateral venogram of a normal foot made with digital equipment.	61
Figure 9-2	Dorsopalmar venogram of a normal foot made with digital equipment.	62
Figure 9-3	Venogram technique.	63
Figure 9-4	Venogram technique.	64
Figure 9-5	Normal venogram of an adult Standardbred gelding.	65
Figure 9-6	Venogram of the same adult Standardbred gelding in Figure 9.5 made 5 days after acute laminitis developed.	66
Figure 9-7	Venogram of the same adult Standardbred gelding in Figures 9.5 and 9.6 made 28 days after acute laminitis developed.	67
Figure 9-8	Sagittal section (A) and digital venogram (B) of normal toe superimposed (C) to show relationship between distal phalanx and the veins of the dorsal sole and terminal papillae.	68
Figure 10-1	Single limb cryotherapy trial.	71
Figure 10-2	The cryotherapy apparatus consisted of a wooden bath holding water to a level just below the carpus.	73
Figure 10-3	Grazing muzzles limit grass and thus WSC intake by horses at pasture.	75
Figure 11-1	Application of a foam sole support pad.	79
Figure 11-2	Foam sole support pad taped in place to the sole of a foundered foot.	79
Figure 11-3	The foam sandwich that is taped together to form a laminitis sole support pad.	79
Figure 11-4	A home made wooden version of the Steward Clog.	80
Figure 11-5	The two components of Coltene lab putty (appendix 2), a silicone dental impression material, are thoroughly mixed and while still soft applied to the cleaned sole.	81
Figure 11-6	The clog showing the surface depression created to accommodate a dropped sole.	81
Figure 11-7	The heart-bar shoe.	83
Figure 11-8	Fitting the heart-bar shoe (A).	84
Figure 11-9	Fitting the heart-bar shoe (B).	85
Figure 11-10	The Equine Digital Support System.	86
Figure 11-11	Fitting the EDSS Natural Balance Shoe.	87
Figure 11-12	Hand forged heart-bar support shoe.	88
Figure 11-13	Silicone rubber cast of the palmar sole, bars and frog.	88
Figure 11-14	Hoof resection of the coronet and distal toe.	89
Figure 11-15	Foot of the same horse in Fig 11.11 10 weeks after coronary band and toe hoof resection.	89

Executive Summary

What the report is about/aims

Laminitis is caused by failure of the distal phalanx (coffin bone or third phalanx) to remain attached to the lamellae that line the inside of the hoof. Specialist intervention is required in the treatment of laminitis, but the response to therapy can be unpredictable. For care-givers, laminitis is the source of much disappointment and frustration as many horses and ponies endure prolonged suffering and yet still face euthanasia when existing treatment options fail. The aim of the laminitis research projects, sponsored over the last nine years by RIRDC, was to conduct research that paved the way to a better understanding of laminitis and to more successful treatments of horses suffering from the disease. This report details a breakthrough in laminitis prevention that is the first such strategy to be scientifically validated both experimentally and clinically. The report also contains “state of the art” information on foot anatomy, pathology, prevention and treatment that will help the reader understand laminitis and thus make better decisions for the animals in their care. New discoveries about how laminitis is triggered lay the foundation for the development of new, targeted treatment regimens.

Who is the report targeted at

This report will inform horse owners, veterinarians, technicians, animal scientists, farriers, trainers and the horse industry in general about the new laminitis preventive strategy and how and when to implement it. It contains guidelines for the therapeutic shoeing of existing cases of laminitis and suggestions for managing animals at risk of developing the disease. The report is written in non technical language; scientific reports are listed for those requiring more detailed information.

Background

Laminitis is the most serious disease of the equine foot and causes pathological changes in anatomy that lead to long lasting, crippling changes in function. It is the second biggest killer of all horse breeds after colic. Due to both its devastating nature and lack of effective therapies, equine laminitis has been listed as a priority for equine research by numerous equine organizations and funding agencies including the RIRDC. The pathophysiology of laminitis has been unclear and controversial for several decades, which is most likely the reason for the overall failure of the majority of drugs that have been introduced to treat the disease. Data generated by RIRDC sponsored laminitis research suggest that the primary triggering event is uncontrolled matrix metalloproteinase (MMP) activation and inhibiting this, to prevent/treat the disease, as we proposed in 1998, has been the focus of this project.

Methods used

The methods used in the RIRDC laminitis projects range from basic clinical observations to the use of most sophisticated molecular genetic probes available. Images were obtained by light microscopy, immuno-fluorescence microscopy, electron microscopy, digital radiography and computed tomography (CT) scanning. Laminitis source material came from natural field cases as well as a small number of experimental cases induced under strict ethical guidelines. A hoof explant protocol was developed that enabled the study of laminitis in the laboratory *in vitro*. Double blind assessment of data by independent observers, rigorous statistical analyses and validation by up to three independent methods ensured correct interpretation of experimental results.

Results/key findings

The *in vitro* model for laminitis using hoof explants, followed by zymographic analysis of enzymes, showed that activation of MMP-2 and MMP-9, by laminitis or chemically, resulted in separation of hoof epidermal and dermal lamellae. Increased gene transcription of MMP-2, MMP-9 and MMP-14 was present during laminitis. The presence of an MMP inhibitor, BB-94, blocked the activity of the MMPs *in vitro* a result highlighting the potential such drugs have as preventive and treatment agents of the future. A sugar-like ingredient in grass called fructan was able to initiate laminitis experimentally thus explaining why pastures high in fructan may sometimes precipitate the disease. In the horse's hindgut, the presence of excess fructan produces an environment that favours the rapid proliferation of Gram-positive bacteria that produce lactic acid and a range of toxins. Factors present

in the supernatant of cultures of these bacteria activated MMP-2 and caused lamellar separation *in vitro* indicating that in addition to intrinsic trigger factors a microbial influence may also play a role in laminitis development.

Horses and ponies affected by Equine Metabolic Syndrome are often obese, have cresty necks and increased adipose tissue deposits in the withers and dorsal area of the back. Plasma insulin concentrations above 100 μ IU/ml indicate insulin resistance (hyperinsulinaemia) and a high risk of laminitis. Insulin alone, when administered in excess to normal ponies, caused laminitis. Management strategies that control insulin resistance and carbohydrate intake decrease the likelihood of laminitis

Early clinical signs of laminitis include shifting weight from one foot to the other, high hoof temperatures for a prolonged time and bounding pulses in the digital arteries. After the development of more extensive lamellar pathology, foot pain increases. Its severity is proportional to the extent of displacement of the distal phalanx within the hoof capsule. A characteristic stance and gait is adopted by the horse to minimize the pain in its feet. Chronic laminitis is marked by persistent lameness and anatomical disintegration of the hoof that includes changes to the coronary band, the development of a dropped sole and deformed hoof growth. Radiographic and venographic examination of the feet should be performed as soon as clinical signs of laminitis appear and during the course of treatment. Inward growing tubular hoof is destructive and contributes to rotation and lysis of the distal phalanx.

Radiographs that supply information on the position of the distal phalanx and hoof distal phalangeal distance (HDPD) should be obtained with careful radiographic technique to allow early diagnosis and treatment. The rate at which the HDPD increases and the appearance of a radiolucent line beneath the inner hoof wall are indicators of the severity of the lamellar pathology. When the distal phalanx sinks rapidly into the hoof capsule, without rotation, the cases are labelled “sinkers” and have catastrophic outcomes. With increasing chronicity, the degree of palmar rotation and pathology of the distal phalanx should be determined radiographically.

Venography is possible because there are no valves in the veins of the horse’s foot. Performing a venogram is relatively simple, but requires practise and good radiographic technique. Venograms provide more information than plain radiographs especially if performed sequentially. Venograms diagnose venous filling problems due to progressive pathological changes in tubular hoof wall and sole growth.

Implications and recommendations for horse care-givers

The new knowledge about laminitis, contained in this report, will help equine care-givers to better understand the disease and make rational, informed decisions regarding prevention and treatment and if necessary euthanasia. Vigorous treatment of the primary inciting disease is of paramount importance. The diagnosis of toxæmia and septicaemia is associated with a high risk of developing laminitis and requires the initiation of medical therapy and mechanical support for the distal phalanx before the appearance of clinical signs of hoof pain. Inflammation and foot pain can be reduced with anti-inflammatory drugs, however their effect is only palliative and will not stop the development of laminitis. Cryotherapy is a proven preventive for horses at risk of developing laminitis, while vasodilator therapy and forced exercise are contraindicated. The administration of mineral oil or activated charcoal may be beneficial in cases of laminitis developing after ingestion of excess grain.

Effective mechanical support, using frog/sole support devices, should be provided early to a horse developing laminitis to improve the outcome of the disease. Cooperative liaison between horse owner, veterinarian and farrier is required for correct application of therapeutic shoes. A supportive sole cast, made using a two-part silicone based impression material, provides additional support to the back part of the foot. Strategic proximal and distal toe hoof wall resection reverses the abnormal hoof growth due to chronic laminitis.

Recovery from laminitis is unpredictable, but generally the prognosis is directly proportional to the extent of displacement of the distal phalanx and the resultant lamellar pathology that occurs. The

return to a normal-looking hoof takes time and prolonged aftercare will often be required. Few horses return to their former athletic soundness after chronic laminitis.

Research at the Australian Equine Laminitis Research Unit (AELRU) is devoted to discovering the mechanism by which the hoof lamellae separate, because prevention of this terrible disease represents a better option than trying to repair the gross anatomical dislocations once they have occurred. Much progress has been made and the research team is ready to embark on preventive and treatment modalities based on the new knowledge gained by the RIRDC sponsored laminitis research of the last nine years.

1. Introduction

In the normal horse or pony the distal phalanx (coffin or pedal bone) is attached to the inside of the hoof by a tough, but flexible, suspensory apparatus. The surface of the inner hoof wall is folded into leaf-like lamellae (laminae) to increase the surface area of this suspensory apparatus. A horse has laminitis when these lamellae suddenly fail. Without the distal phalanx properly attached to the inside of the hoof, the weight of the horse and the forces of locomotion drive the bone down into the hoof capsule. Important arteries and veins are sheared and crushed and the corium of the coronet and sole is damaged. There is unrelenting pain in the feet and a characteristic lameness (**Figure 1.1**).



Figure 1-1 *The gait of a horse with severe laminitis.*

When a horse develops laminitis the front feet are usually the most severely affected. It is extremely painful for the horse to load the toes of the front feet. If forced to walk (Obel III grade lameness) it will bring its hind legs well under and half rear before stepping forward in front. The posterior phase of the foreleg stride is thus very much shortened.

1.1 The Problem of Laminitis

Laminitis is the most serious disease of the equine foot and causes pathological changes in anatomy that lead to long lasting, crippling changes in function (chronic laminitis or founder). It is the second biggest killer of horses after colic. In the USA National Animal Health Monitoring System (NAHMS) report of the year 2000, 13% of all horse establishments (excluding racetracks) had a horse with laminitis in the previous year and 4.7% of these died or were euthanased. Laminitis has a developmental phase during which lamellar pathology is triggered. This precedes the appearance of the foot pain of laminitis. The developmental period lasts 40 - 48 h in the case of laminitis caused by excessive ingestion of soluble, non-structural carbohydrates, such as starch or fructan. Sometimes no developmental phase can be recognized; the horse or pony is discovered with painful laminitis with no apparent ill health or inciting problem occurring beforehand. This appears to be the case when the

blood concentration of insulin is abnormally high. Many people own and care for horses all their lives and never encounter a horse with laminitis. However, when it does strike, laminitis can be heartbreaking. The pain and suffering are relentless and sometimes euthanasia is the only responsible option for an owner, despite the stoic ability of many horses to live on as cripples. Formulating an effective management plan for a horse with laminitis is one of the most difficult tasks a horse owner can be confronted with. The owner, in consultation with a veterinary clinician and farrier, will have to decide if the investment of money, time and energy is worthwhile keeping in mind the pain that the horse must endure during the process. After months of treatment and the expenditure of perhaps thousands of dollars, the horse in question may still be suffering severely. The clinical signs, the extent and severity of lamellar pathology and the response to therapy vary unpredictably between individual horses and this makes a rational treatment strategy, with an accurate prognosis, difficult to formulate. Severe damage to the internal anatomy of the hoof occurs, out of sight, within the space of a few hours and the severity and extent of this initial damage is the single most important factor influencing the final outcome.

1.2 Laminitis Research

Scientific understanding of laminitis is incomplete and the horse owner often becomes committed to the symptomatic treatment of a chronic condition that inexorably deteriorates. This lack of understanding of the processes involved is frustrating to the horse owner and veterinarian alike, and of little use to the horse. Over the last nine years, the RIRDC horse programme has made understanding laminitis and seeking improved treatment strategies a priority. This report is the result of nine years continuous RIRDC funding to the Australian Equine Laminitis Research Unit (AELRU) based in the School of Veterinary Science at The University of Queensland. It describes laminitis in the most up to date way possible, although there are still large gaps in our knowledge. To understand what goes wrong with an organ, it is essential to first learn about its normal structure and function. Thus, the first part of this publication details what is already known about lamellar anatomy and presents the results of research carried out at the AELRU on the structure and function of the normal horse's foot. This is followed by a description of the developmental mechanism of laminitis that has been elucidated from our findings. Finally, a review of first aid measures for the foundering horse is presented and then ways and means of rehabilitation. The hope is that a better understanding of laminitis will lead to a more unified approach and rational treatment, by owners, veterinarians and farriers alike.

1.3 Key Points

- Laminitis is caused by failure of the attachment of the distal phalanx to the lamellae on the inside of the hoof.
- The disease causes pathological changes in hoof anatomy that cause crippling pain and a characteristic lameness.
- Specialist intervention is required in the treatment of laminitis, but the response to therapy can be unpredictable.
- Research that paves the way to a better understanding of laminitis may lead to more successful treatment of horses suffering from the disease.

2. The Horse's Foot

The horse's foot is, without doubt, a miracle of bioengineering (Pollitt 1992, 1995; Pollitt 1998; Pollitt 2004). Domestic horses, despite being relatively large animals (Thoroughbreds and Australian Stockhorses weigh around 450kg), can nevertheless move with great speed and agility. They make contact with the ground via a hoof that encases a single finger or toe bone, on the end of each of the four limbs (digitigrade). This is quite different from plantigrade people who walk on the bones of the hock (the human ankle is the anatomical equivalent of the horse's hock). The horse's terminal finger bone (or toe bone in the rear limbs) is called the distal phalanx and is encased in a tough, horny capsule, the equivalent of our fingernail. It is more precise to say that the horse makes contact with the ground standing on just four modified finger (or toe) nails. This characteristic makes the soliped horse (and the other Equidae) unique in the animal kingdom. The tough, hoof capsule protects the softer, more sensitive, structures within (**Figure 2.1**) and allows the horse to gallop over dry, rocky terrain (just like we can if our feet are protected in a tough leather or rubber outer casing).

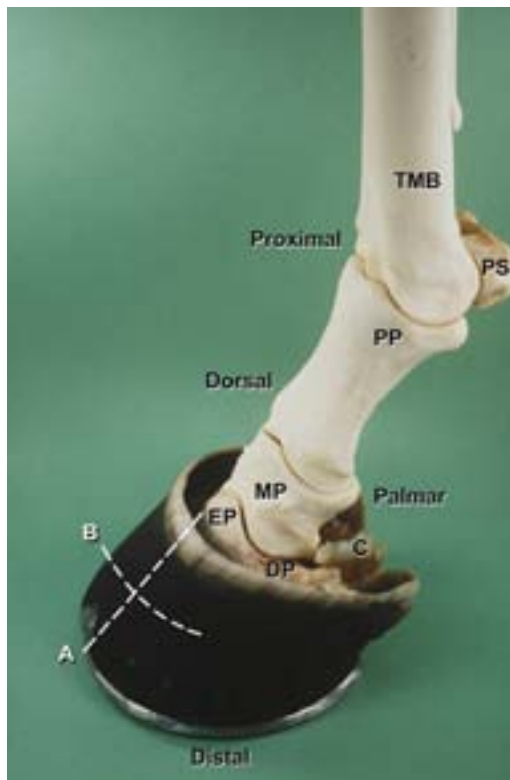


Figure 2-1 *The three bones of the digit are viewed obliquely from the dorsal surface.*

The proximal phalanx (long pastern bone) forms two articulations. Above, it articulates with the third metacarpal bone (cannon bone) and the paired proximal sesamoid bones to form the high-motion metacarpophalangeal joint (fetlock joint) and below it articulates with the middle phalanx (short pastern bone) to form the low-motion proximal inter-phalangeal joint (pastern joint). The middle phalanx articulates below with the distal phalanx (coffin bone) and the distal sesamoid (navicular bone) to form the distal interphalangeal or coffin joint. The prominent, pyramid-shaped, extensor process is where the important extensor tendon inserts on the distal phalanx. The cartilages of the distal phalanx (ungual cartilages) originate on the lateral and medial borders of the bone and are palpable above the coronet of the hoof wall. The dotted line through B = plane of transverse sections, the dotted line through A = plane of longitudinal (sagittal) sections, TMB = third metacarpal bone, PS = proximal sesamoid bones, PP = proximal phalanx, MP = middle phalanx, DP = distal phalanx, EP = extensor process, C = cartilage of distal phalanx.

Having single digits, encased in tough hooves, on the end of relatively light-weight limbs, has undoubtedly bestowed speed and versatility to horses. However, this ability comes at a price. Immobility and crippling result if the attachment mechanism, between the hoof lamellae and the distal phalanx, fails. Considerable selection pressure against laminitis must exist among wild equids, as a foundered animal would quickly attract the attention of predators. In fact, it can be argued that laminitis is a disease resulting from the association of horses and humans, as it is commonly the artificial environment under which horses are kept that results in the development of the disease. This applies not only to the starch laden grains but also to carbohydrate rich pastures, selected to maximize sheep and cattle production, that our horses consume. Equids are normally mobile and athletic, but when they develop laminitis and become crippled we realise, belatedly, how dependent they are on an intact, functional, pain-free hoof lamellar distal phalanx suspensory mechanism.

2.1 Foot structure and function

Some knowledge of the structure and function of the normal horse's foot is necessary in order to understand the complexities of equine laminitis. This and the following chapter describe the findings of research conducted at the AELRU into the structure/function relationships of the normal foot.

Figure 2.2 and 2.3 are diagrams of the horse's foot in sagittal and transverse sections. The reader is urged to study these diagrams before reading on because they show most of the important anatomical structures and introduce terms that will be used throughout this publication.

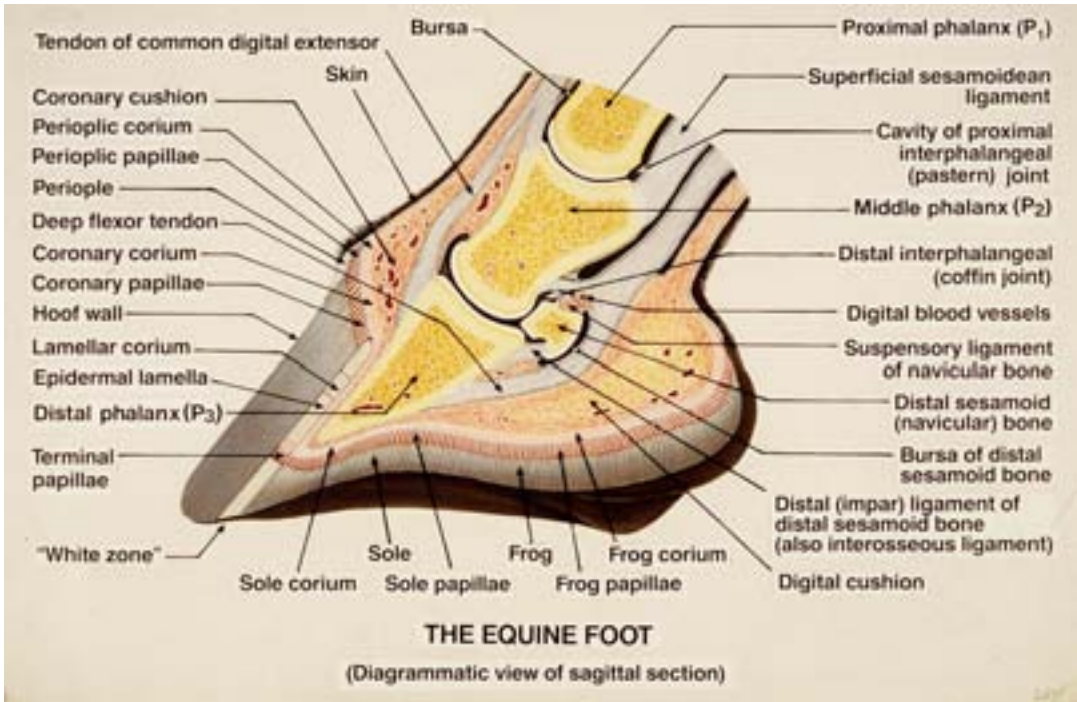


Figure 2-2 Diagram of a sagittal section of the horse's foot.

The lamellar hoof of the inner hoof wall is attached via connective tissue to the dorsal surface of the distal phalanx. Tubular hoof of the wall, white zone, sole and frog is associated with dermal papillae. Design: Chris Pollitt. Art: John McDougall.

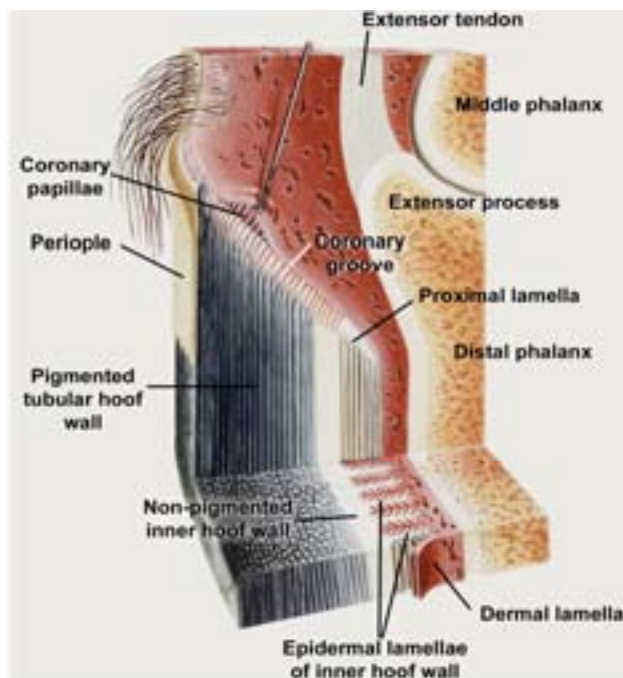


Figure 2-3 Diagram of the anatomy of the hoof wall.

Tubular and intertubular hoof wall is formed at the top of the hoof by the constant proliferation of the epidermal basal cells of the coronary band. The surface area of the inner hoof wall is expanded by the provision of 550-600 epidermal lamellae. The dermal lamellae interdigitate with the epidermal lamellae and are firmly attached to each other. The tough connective tissue of the dermal lamellae attaches to the periosteum of the distal phalanx and thus suspends the distal phalanx to the inside of the hoof wall. Design: Chris Pollitt. Art: John McDougall.

2.2 Hoof growth

The hoof wall, sole and frog grow throughout the life of the horse. Continual regeneration of the hoof wall occurs at the coronary band where hoof germinal cells (epidermal basal cells) produce populations of daughter cells (keratinocytes or keratin producing cells) which mature and keratinise, continually adding to the top of the hoof wall (the proximal hoof wall) and incrementally increasing hoof wall length. The same process occurs in the sole and frog at approximately the same rate.

To study hoof wall growth we developed an improved method of detecting cell proliferation using the thymidine analogue 5-bromo-2'-deoxyuridine (BRdU), which is incorporated into the DNA of replicating cells (Daradka and Pollitt 2004). This technique allowed us to show the precise location of basal cells undergoing mitosis in the proximal hoof wall, lamellae and sole. BRdU injected intravenously into living horses was incorporated into all cells undergoing mitosis during a one-hour study period. Histological sections (biopsies) of hoof tissue stained immunohistochemically, using monoclonal antibodies against BRdU, showed a high rate of basal cell mitosis in the coronary band zones that produce tubular hoof (**Figure 2.4**) in the proximal lamellar zone, the white zone and sole tubular hoof.

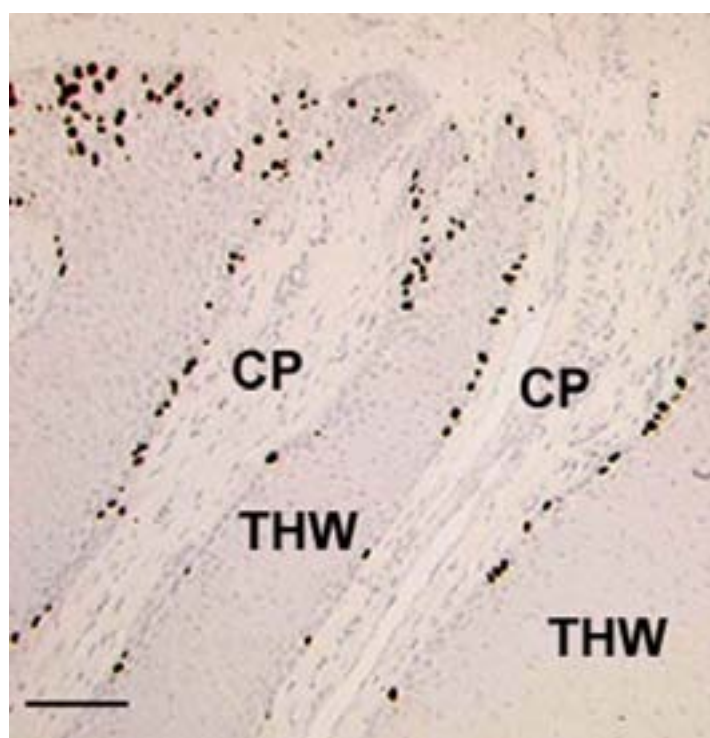


Figure 2-4 Basal cell proliferation in the coronary band.

Longitudinal section of proximal hoof wall (coronary band) immunostained for BRdU that was injected intravenously into a normal horse 60 minutes previously. The positive, brown staining cells are basal cells that incorporated BRdU as they underwent mitosis during the previous 60 minutes. Both the tubular and intertubular hoof show a high rate of basal cell mitosis. In the space of 60 minutes 12% of all coronary band basal cells have proliferated and it is estimated that all basal cell proliferate every 8 hours. CP = coronary papilla. THW = tubular hoof wall. Bar = 100 μ m.

There was no evidence of basal cell proliferation in the majority of the lamellar region. Thus we can say with confidence that the growth zones are confined to the top (proximal) (**Figure 2.5**) and bottom (distal) regions of the hoof wall as well as the sole (**Figure 2.6**). Any damage to these regions (such as occurs with chronic laminitis) will have serious ramifications to future foot health.

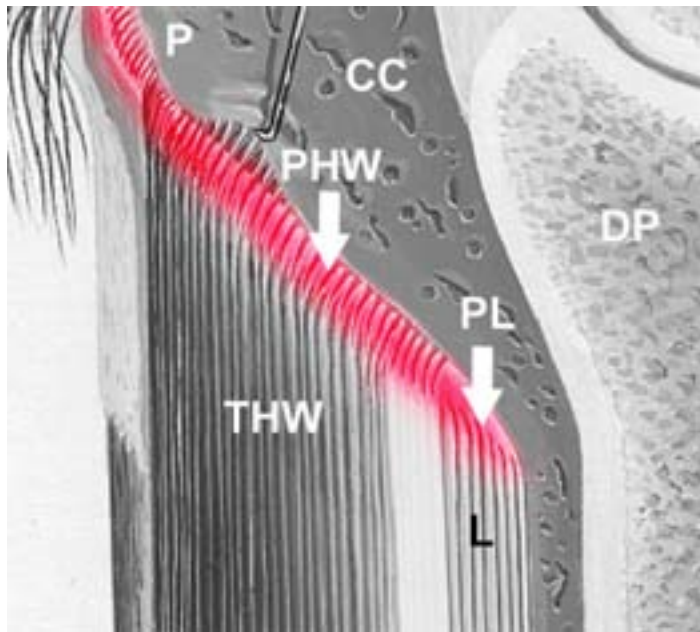


Figure 2-5 The growth zones of the proximal hoof wall (highlighted in red). Basal cells of the tubular hoof wall and periople proliferate non-stop throughout the life of the horse. The proximal lamellae also proliferate at a rate similar to the hoof wall proper, but the rate is near zero in the lamellar regions below this. CC = coronary corium. DP = distal phalanx. P = periople. PHW = proximal hoof wall. PL = proximal lamellae. THW = tubular hoof wall. L = lamellae.

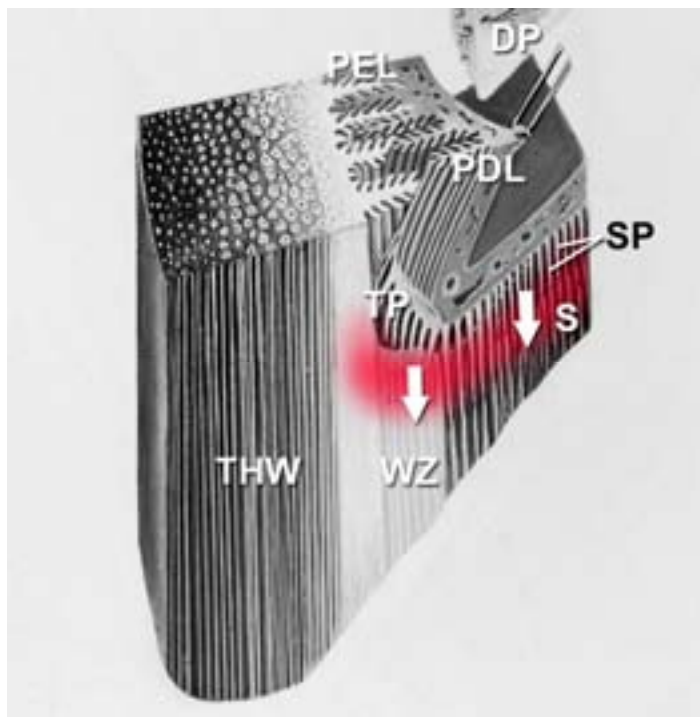


Figure 2-6 The growth zones (highlighted in red) of the distal wall, white line and sole. Basal cells of the tubular distal hoof wall, white zone and sole also proliferate non-stop throughout the life of the horse. The near zero proliferation of the epidermal lamellae increases abruptly adjacent to the sole. DP = distal phalanx. PEL = primary epidermal lamella. PDL = primary dermal lamella. THW = tubular hoof wall. DP = distal phalanx. TP = terminal papillae. S = sole. SP = sole papillae.

We estimate that each basal cell (or keratinocyte) of the coronary band, white line, sole and frog divides every 8 hours, every day of the horse's life, producing daughter cells that mature and keratinise. In the dorsal hoof wall they undertake a journey, up to 8 months in duration, in the direction of the ground surface.

2.3 Hoof wall tubules

Maturing hoof wall keratinocytes, become organised into thin, elongated cylinders or tubules. In cross-section the keratinocytes of individual hoof wall tubules are arranged around a central hollow medulla in non-pigmented concentric layers (Figure 2.7). Each hair-like tubule is continuous, from its origin at the coronary band all the way to the ground surface (a distance of 5-15 cm depending on the breed). The keratinocytes between the hoof wall tubules mature into inter-tubular hoof thus forming a keratinised cellular matrix in which tubules are embedded.

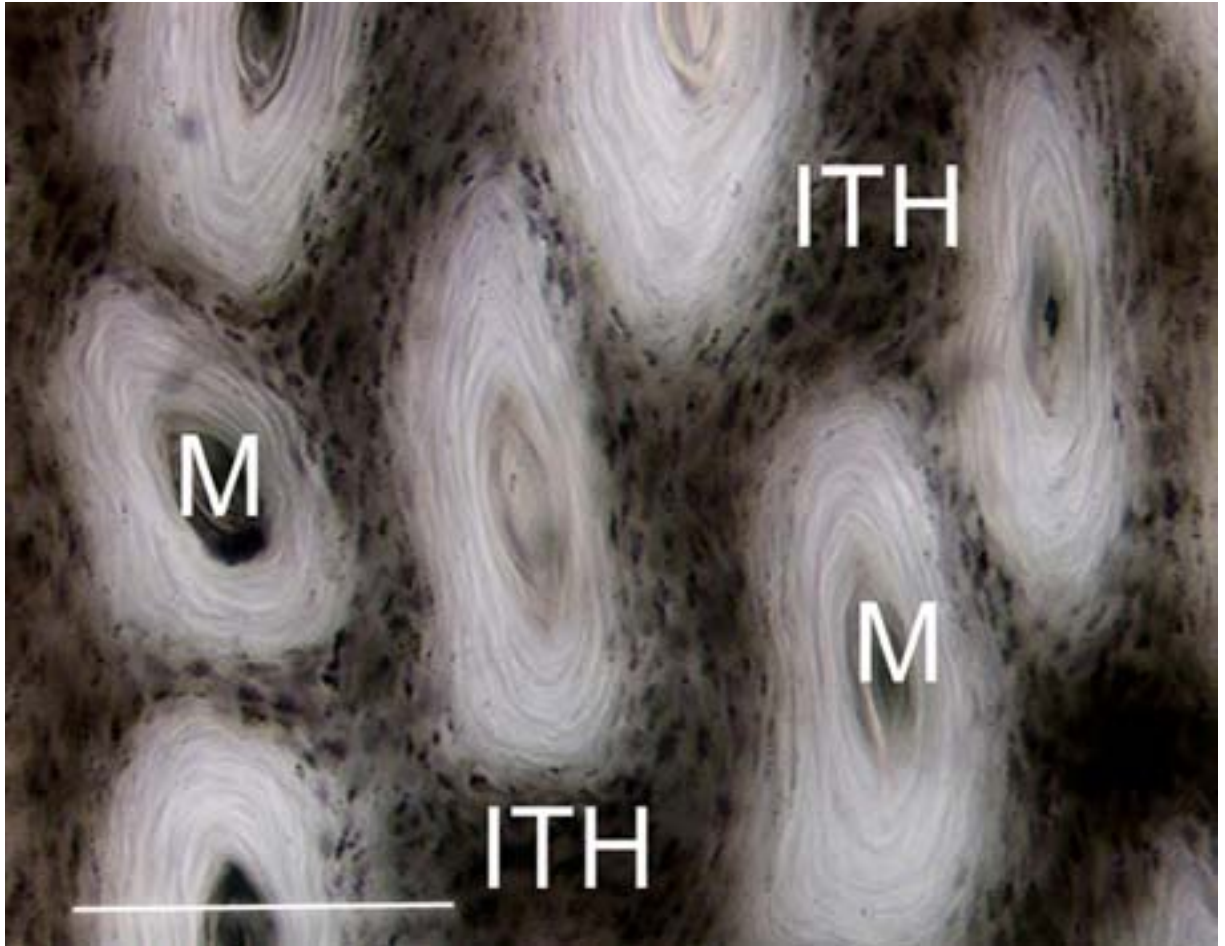


Figure 2-7 Transverse section of a pigmented hoof wall (unstained).

The intertubular hoof (ITH) is heavily pigmented and is the strongest component of the hoof wall. In contrast, the tubules of the hoof wall are unpigmented and have a hollow, central medulla (M) around which are arranged concentric layers of mature keratinocytes. Bar = 50 μ m.

The intertubular horn is formed at right angles to the tubular horn and bestows on the hoof wall the unique property of a mechanically stable, multi-directional, fibre-reinforced composite. Interestingly, hoof wall is stiffer and stronger at right angles to the direction of the tubules; a finding at odds with the usual assumption that tubules are aligned to the ground reaction force that is transmitted proximally up the hoof wall parallel to the tubules. The hoof wall appears to be reinforced by the tubules, but it is the intertubular material that accounts for most of its mechanical strength, stiffness and fracture toughness. The tubules are 3 times more likely to fracture than intertubular horn.

The stratum medium is considered to have an anatomical design that confers strength in multiple directions (anisotropic). Unlike bone, which is a living tissue and remodels to become stronger along lines of stress, the stratum medium is non-living tissue, but is anatomically constructed to resist stress in every direction and to never require remodeling. During normal locomotion the stratum medium only experiences one-tenth of the compressive force required to cause its structural failure. The basal

cell daughters, whether destined to be tubular or intertubular hoof, do not keratinise immediately. As the distance between basal cells and their daughters increases (each generation is pushed further away from the basal cell layer by the production of successive generations), the intracellular skeleton of the maturing cells becomes denser (by the manufacture of more intermediate filaments composed of various keratin molecules). Thus by increasing the number of desmosomes, stronger attachment zones are formed between the cell membranes of adjoining keratinocytes. Desmosomes are points of intercellular contact, which function like spot-welds between adjacent cells. Within the cell, keratin intermediate filaments also attach to the desmosomes to form the three-dimensional internal skeleton (the cytoskeleton) of the cell. Thus the keratinocytes transform, becoming sturdier and more durable to stress and strain. The final stage of keratinocyte maturation is abrupt. The cell nucleus fragments and disappears and the cell is declared officially dead. Granular, densely staining material (membrane-coating granules) migrates through the cytoplasm to be deposited on the outside of the cell as an intercellular cement substance. At this late stage of keratinocyte maturation, the cell loses its nucleus (becomes anuclear), and the cytoplasm is densely packed with tough keratin filaments that interconnect with each other and to the desmosomes. Thus, the cell membrane of each cell becomes firmly cemented to its neighbour. Finally, the keratin filaments are embedded in a dense, amorphous matrix rich in sulphur containing amino acids (but not keratin), to form the mature corneocyte. The fully keratinised cells (anuclear corneocytes) of the tubular and intertubular hoof, cemented firmly to each other, form a continuum; the tough yet flexible *stratum medium* of the hoof wall. Mature corneocytes, firmly cemented together, form a tough, protective barrier preventing the passage of water and water-soluble substances inwards and the loss of body fluids, imparted by the highly vascular dermis, outwards. In addition to acting as a permeability barrier, hoof wall corneocytes, arranged in their specialised tubular and intertubular configuration, have the crucial job of ultimately supporting the entire weight of the horse.

The tubules of the equine hoof wall are not arranged randomly. The tubules of the *stratum medium* are arranged in four distinct zones based on the density of tubules in the intertubular horn. The zone of highest tubule density is the outermost layer and the density declines stepwise towards the internal lamellar layer. The tubule density gradient across the wall appears to be a mechanism for smooth energy transfer, from the rigid (high tubule density) outer wall to the more plastic (low tubule density) inner wall, and ultimately to the distal phalanx. The gradient in tubule density mirrors the gradient in water content across the hoof wall and together these factors represent an optimum design for equine hoof wall. Tubule zonation is also a crack-stopping mechanism. The zones confer on the hoof wall the design properties of a laminated composite; the interface between zones absorbs energy and prevents the propagation of cracks towards sensitive inner structures. In addition, the anisotropy (stronger in one direction) of the *stratum medium* ensures that cracks, when they occur, propagate from the bearing surface upwards, parallel with the tubules, i.e. along the weakest plane. They do not extend to the innermost layers of the hoof wall because in this region the relatively high water content confers high crack resistance. The hoof wall also has a powerful dampening function on vibrations generated when the hoof wall makes contact with the ground during locomotion. It is able to reduce both the frequency and maximal amplitude of the vibrations. By the time the shock of impact with the ground reaches the first phalanx around 90% of the energy has been dissipated, mainly at the lamellar interface.

2.4 The corium

The highly vascular corium or dermis (often referred to as the “quick”) underlies the hoof wall and consists of a dense matrix of tough, connective tissue (tendon-like collagen I) interspaced with a network of arteries, veins and capillaries, and sensory and vasomotor nerves. All parts of the corium, except for the lamellar corium, have papillae that fit tightly into the holes in the adjacent hoof. The lamellar corium has dermal lamellae that interlock with the epidermal lamellae of the inner hoof wall and bars. The corium provides the hoof with nourishment and its dense matrix of connective tissue connects the basement membrane of the dermal-epidermal junction to the periosteal surface of the distal phalanx and thus suspends the distal phalanx from the inner wall of the hoof capsule.

2.4.1 The coronary corium

The coronary corium fills the coronary groove and blends with the lamellar corium of the inner hoof wall. Its inner surface is firmly attached to the extensor tendon and the cartilages of the distal phalanx. Thus, wherever the distal phalanx goes, the coronary band goes with it. This fact becomes important when laminitis allows a downward displacement of the distal phalanx. Collectively, the coronary corium and the germinal epidermal cells that rest upon its basement membrane are known as the coronary band. A feature of the coronary corium is the large number of hair-like papillae projecting from its surface. In life each tapering papilla fits snugly into a hole on the surface of the epidermal (hoof wall) coronary groove (**Figure 2.8**). Each papilla contains arteries, veins and capillaries and is responsible for nurturing an individual hoof wall tubule. The same arrangement applies to the papillae of tubular hoof of the white line, sole and frog.

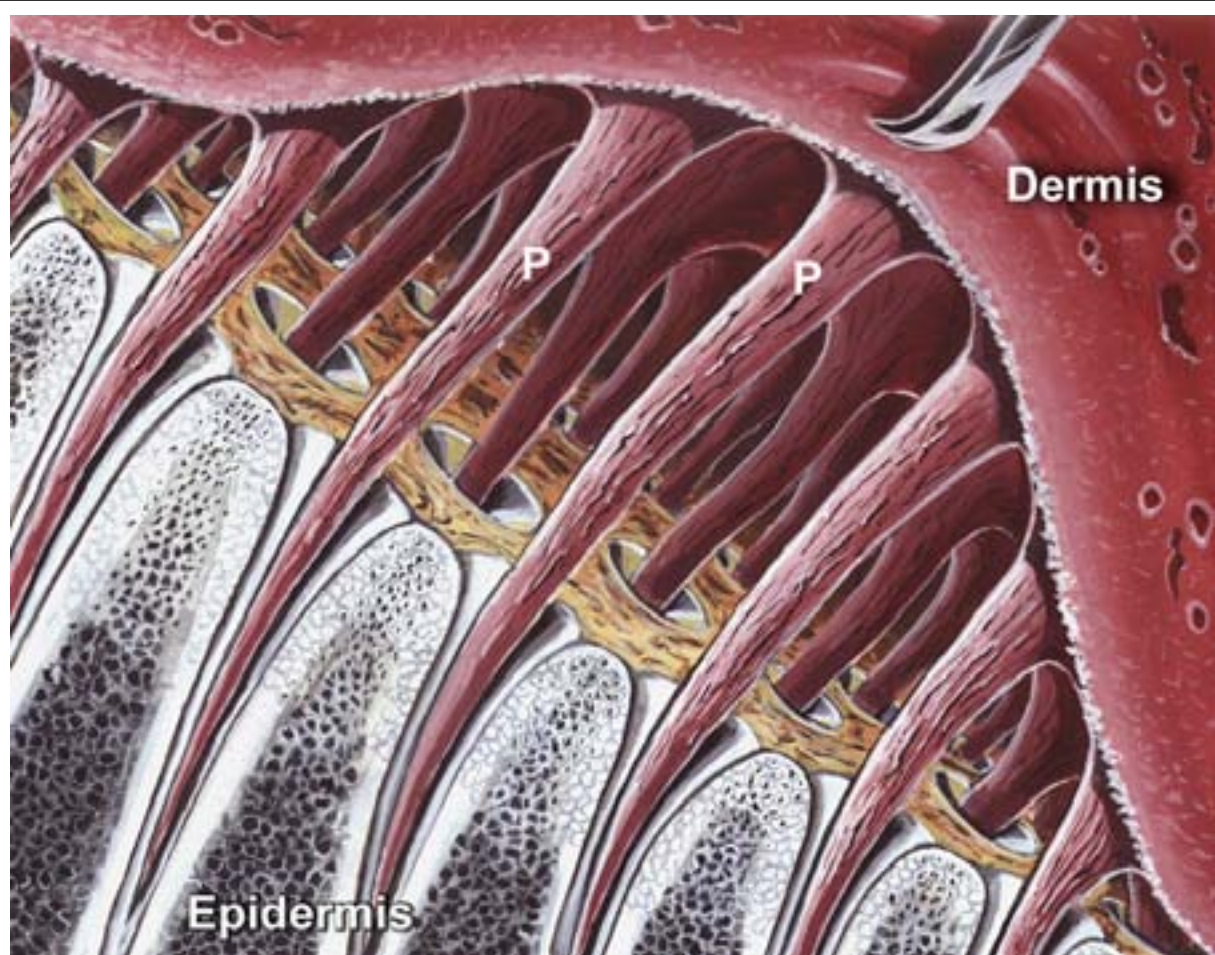


Figure 2-8 Diagram of the coronary band.

An artificial separation has been made through the dermal/epidermal junction to show the relationship between the two anatomical compartments. Each dermal papilla (P) fits into a socket in the coronary groove of the epidermal hoof wall and is responsible for the maintenance of a single epidermal hoof wall tubule. In life, the arteries, veins and capillaries of each papilla supply the nutrients and gaseous exchange required for the continual growth and maintenance of a single hoof tubule. Design: Chris Pollitt. Art: John McDougall.

2.4.2 The lamellar corium - distal phalanx attachment apparatus

In the day-to-day life of a horse, the attachment between hoof and bone is problem free. The enormous loads and the amount of distortion and elastic recoil that the lamellar layer experiences during each phase of the stride are taken for granted. It is the principal shock absorber of the lower limb. **Figure 2.9** is a diagram showing the key structures of the hoof lamellar-distal phalanx attachment apparatus.

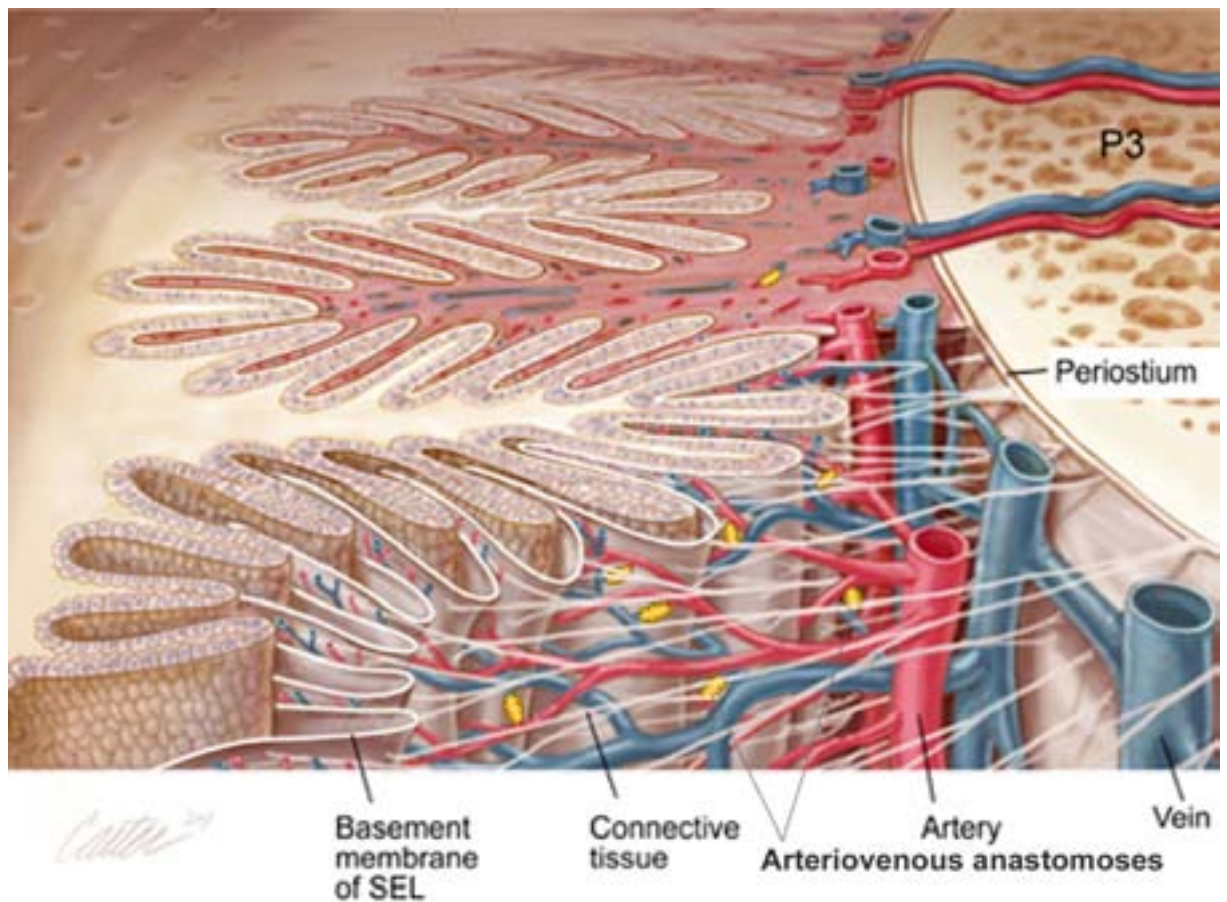


Figure 2-9 Diagram of the key structures of the hoof lamellar-distal phalanx attachment apparatus.

The lamellae of the inner hoof wall interdigitate with dermal lamellae at the basement membrane zone. Connective tissue attaches the distal phalanx (P3) to the inner surface of the basement membrane. The basement membrane is shown artificially detached to reveal the living basal cells of the secondary epidermal lamellae beneath (Pollitt 2004). Design: Chris Pollitt. Art: Kip Carter

2.5 Key Points

- The weight of a horse is supported by modified fingernails (hooves) which encase the horse's terminal finger bones (distal phalanges).
- The constant growth of the hoof wall originates at the coronary band with the division of keratinocytes and organisation of maturing keratinocytes into the tubular and intertubular hoof of the *stratum medium*.
- The corium consists of a dense matrix of tough, connective tissue containing blood vessels and nerves. The coronary corium has papillae that provide nourishment to the hoof wall tubules.
- The lamellar corium has dermal lamellae that interdigitate with the epidermal lamellae of the inner hoof wall and bars, thus providing a connection between the hoof wall and distal phalanx.

3. Lamellar Anatomy

3.1 The lamellae of the inner hoof wall

The innermost layer of the hoof wall and bars of horses and ponies is named the lamellar layer after the 550-600 epidermal lamellae (primary epidermal lamellae) that project from its surface in parallel rows (Figure 3.1).




Figure 3-1 Hoof with its contents removed to show the lamellae of the inner hoof wall.

This pigmented hoof capsule, shown with the contents removed, has a portion of the wall cut away to show the inner structures the hoof capsule. The cut at the toe shows the curve of the coronary groove (CG), the pigmented stratum medium of the hoof wall proper, and the non-pigmented inner hoof wall (stratum internum) which bears the epidermal lamellae (L). The hoof wall cut in transverse section shows the lamellae (arrowed) lining the non-pigmented inner hoof wall. At the top of the hoof wall, on the outer edge of the coronary groove, is the soft, non-pigmented, flexible periople (P) which expands at the heels to form the bulbs of the heels. At the butress of the heels, the lamellae of the inner hoof wall are reflected inwards, towards the frog, to form the bars (B) The surfaces of the concave coronary groove, the sole and the frog are dotted with numerous small holes for the dermal papillae.

In common with all epidermal hair and horn-like structures, the lamellae of the inner hoof wall are avascular and depend on capillaries in the adjacent dermis (or more specifically, the lamellar corium) to supply nutrients. The epidermal cells adjacent to the dermis (sometimes referred to as the basal cell layer, germinal cell layer or *stratum germinativum*) are very important as it is these cells that must

remain attached to the connective tissue of the distal phalanx. As their anatomical name suggests, the lamellar basal cells are expected to be a germinative or proliferative cell layer, but interestingly, this is not the case with the basal cells of the lamellae of the equine inner hoof wall. They do not proliferate to any great extent, in sharp contrast to the epidermal basal cells of the coronet and sole that proliferate continuously to form the tough, but flexible hoof wall, white line, sole and frog, respectively. Therefore the primary function of the lamellar basal cells is to suspend the distal phalanx within the hoof capsule. They only proliferate when the hoof wall is injured and healing is required.

3.2 Secondary epidermal lamellae

Microscopic examination of the inner hoof wall shows that the surface area of the lamellar region is further expanded by the addition of secondary lamellae upon each primary lamella. There are about 150-200 secondary lamellae (**Figure 3.2**) along the length of each of the 550-600 primary lamella. The tips of the lamellae (both primary and secondary) all point towards the distal phalanx indicating the direction of the tension to which the lamellar suspensory apparatus is subject. The surface area of the equine inner hoof wall has been calculated to average just under one square metre, which is a considerable increase over bovine hooves that lack secondary lamellae.




Figure 3-2 *The epidermal lamellae of the inner hoof wall.*

The epidermis of the inner hoof wall is arranged into rows of primary (PEL) and secondary lamellae (SELS). The secondary epidermal lamellae are all approximately the same length and connect at their bases to the primary lamella at an oblique angle. They orientate towards the dorsal surface of the distal phalanx which is out of picture to the right. In life the spaces between the epidermal lamellae are occupied by a complementary arrangement of dermal lamellae.

3.3 The basement membrane

At the interface of the lamellar epidermis and dermis is a tough, unbroken sheet of connective tissue called the basement membrane (**Figure 3.3**). This key structure is the bridge attaching the basal cells of the lamellar hoof epidermis on one side and the tough connective tissue (tendon-like collagen I) on the upper surface of the distal phalanx on the other (Pollitt 1994). The basement membrane is constructed of a unique, fibrillar collagen called type IV collagen. Woven into the mat-like type IV collagen framework is laminin, one of several basement membrane glycoproteins. It forms receptor sites and ligands for a complex array of growth factors, cytokines, adhesion molecules and integrins that together direct the functional behaviour of the epidermis. Without an intact, functional basement membrane, the lamellar epidermis, to which it is normally firmly attached, falls into disarray.

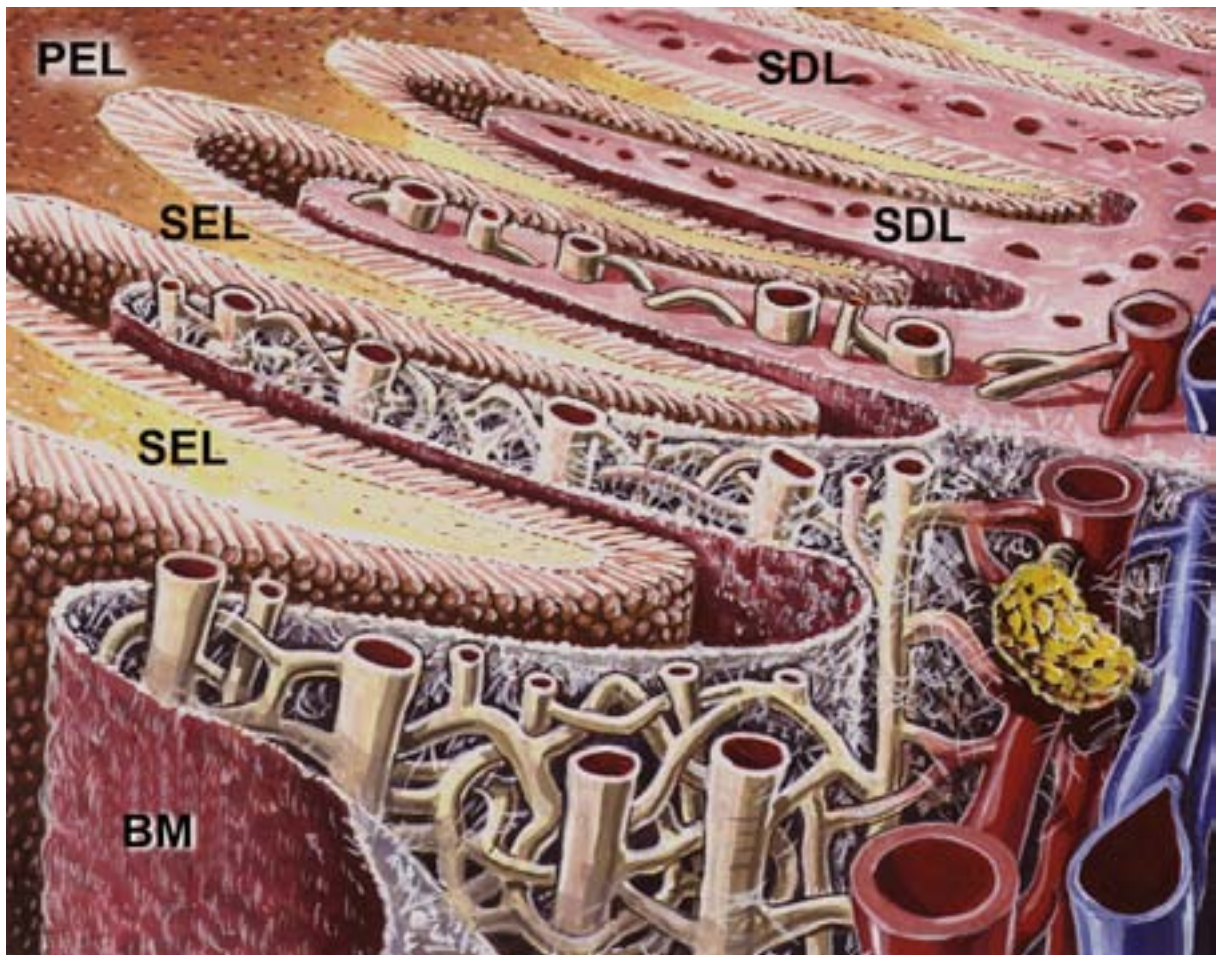


Figure 3-3 The basement membrane at the dermo-epidermal junction.

At the interface of the lamellar epidermis and dermis is the basement membrane (BM), a tough, unbroken sheet of connective tissue that bridges the basal cells of the secondary lamellae (SELs) on one side and the tough connective tissue of the secondary dermal lamellae (SDLs) on the other. The dermal connective tissue of the SDLs is ultimately embedded on the surface of the distal phalanx. Diagram design: Chris Pollitt. Art: John McDougall.

3.4 Hemidesmosomes

The lamellar basement membrane is attached to the base of epidermal basal cells at discrete sites called hemidesmosomes (French and Pollitt 2004b). Hemidesmosomes resemble “spot-welds” or rivets on sheet metal and are attachment discs that serve to keep the sheet of basement membrane firmly adhered to all the basal cells of the lamellar hoof. Each hemidesmosome is constructed of several proteins that stain darkly when viewed with the transmission electron microscope (**Figure 3.4**).

Bridging the gap between the dense plaque of the hemidesmosome and the basement membrane proper (the *lamina densa*) are numerous sub-microscopic anchoring filaments. Each filament consists of a single glycoprotein molecule called laminin-5 that is unique to hemidesmosomes. An additional protein called BP-180 may also be part of the anchoring filament. If either the anchoring filaments or the hemidesmosomes are damaged, and made to disappear, the basement membrane separates from the basal cell. Significantly, for students of laminitis, both laminin-5 and BP-180 are substrates of connective tissue enzymes called matrix metalloproteinases or MMPs (**Figure 3.5**).

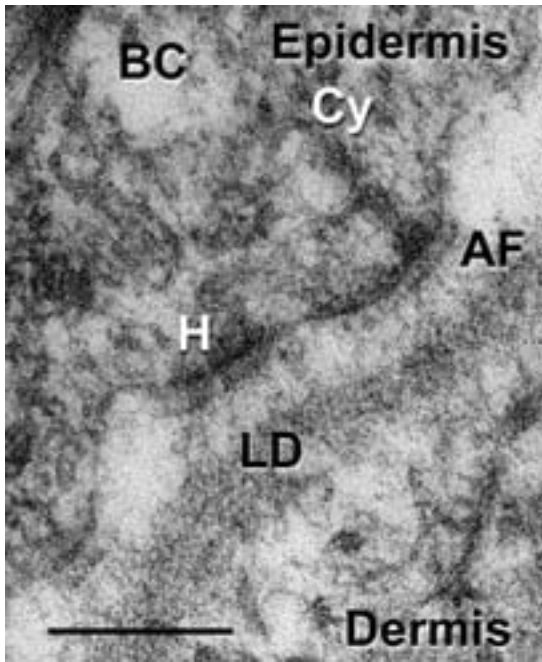


Figure 3-4 Hemidesmosomes at the dermo-epidermal junction.

The electron dense lamina densa (LD) is the major structural component of the basement membrane. Hemidesmosomes are attachment discs that serve to keep the lamina densa of the basement membrane firmly adherent to all the basal cells (BC) of the lamellar hoof. Each hemidesmosome is constructed of several proteins that stain darkly when viewed with the transmission electron microscope. The internal skeleton or cytoskeleton (Cy) of the basal cell is constructed of fine keratin filaments that attach to the intracytoplasmic dense plaque of all hemidesmosomes and interconnect to desmosomes and the nucleus. Bridging the gap between the dense plaque of the hemidesmosome (H) and the lamina densa are numerous submicroscopic anchoring filaments (AF). Each filament consists of a single glycoprotein molecule called laminin-5 that is unique to hemidesmosomes. Bar = 10 nm

3.5 Basal cell cytoskeleton

Within the cytoplasm of each basal cell is a criss-crossing network of fine protein filaments (intermediate filaments) that make up the internal skeleton (cytoskeleton) of the cell. The cytoskeleton bestows rigidity and the correct shape to the cell. All of the cellular organelles (mitochondria, Golgi apparatus, endoplasmic reticulum), as well as the all-important nucleus, are suspended and fixed to the three-dimensional lattice of the cytoskeleton.

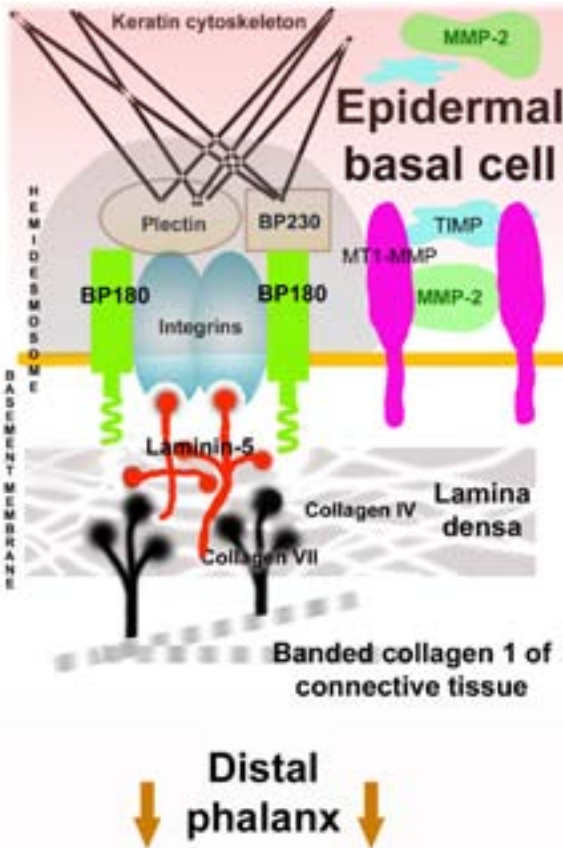


Figure 3-5 Diagram of hemidesmosome, the key structure attaching epidermal basal cells to the basement membrane

Hemidesmosomes firmly anchor the basal cells of the secondary epidermal lamella to the basement membrane. The portion of the hemidesmosome in the cytoplasm of the basal cell consists of a plaque (the intracytoplasmic plaque) that contains plectin and integrin. The keratin intermediate filaments of the cytoskeleton connect to plectin which in turn is connected to molecules of integrin that connect to anchoring filaments of laminin 5. The anchoring filaments are in turn embedded in the lamina densa of the basement membrane. Basal cells also contain matrix metalloproteinases (MMPs) as well as TIMP their natural inhibitor.

Where the cytoskeleton approaches the base of the cell adjacent to the basement membrane, it is woven into the disc of the hemidesmosome. Where the cytoskeleton approaches the inner side and top walls of the cell, adjacent to the neighboring basal cells and parabasal cells, it is woven into the discs of the desmosomes. Thus the cytoskeleton forms a direct line of communication between neighboring cells, the basement membrane and the exterior. If damage should occur to the hemidesmosomes, desmosomes or the basement membrane, the basal cell cytoskeleton collapses and the basal cell is cut-off from the information that controls its normal and proper function (**Figure 3.6**).

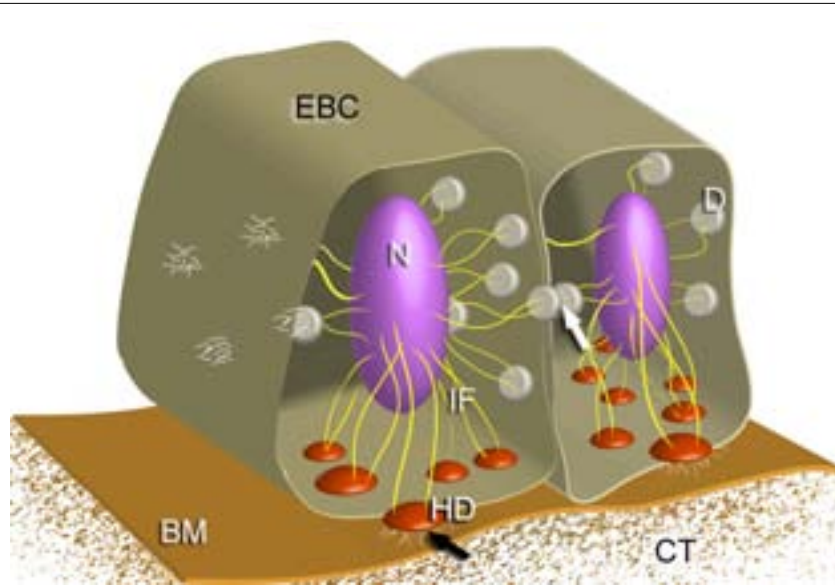


Figure 3-6 Diagram of the cytoskeleton of an epidermal basal cell.

Epidermal basal cells (EBC) are subject to tension and distortion, and criss-crossing their cytoplasm is a network of tough, rope-like, filamentous keratin proteins or intermediate filaments (IF), forming an internal cell skeleton or cytoskeleton. The principal function of the cytoskeleton is structural - to reinforce the cell from within and provide mechanical support to the cell membrane

and the nucleus (N). It keeps the cell in the correct shape, the nucleus in the correct position and distributes tensile forces so that the forces are distributed amongst all the cells providing rigidity and strength to the tissue. Intermediate filaments are organised in the cytoplasm as a network that extends in three-dimensions from the nucleus to the inner surface of the cell membrane. An intermediate filament cytoskeleton is especially important where cells are grouped together to form tissues and when a layer of cells is in contact with a basement membrane (BM). The intermediate filaments are anchored to the cell membrane at specialised junction sites called desmosomes (D) and hemidesmosome (HD). Desmosomes anchor neighbouring cells to each other (white arrow) and hemidesmosomes attach the base of the cell firmly to the underlying basement membrane (black arrow). Thus the intermediate filaments of one cell are directly connected to the intermediate filaments of neighbouring cells by desmosomes and to the underlying connective tissue (CT) via hemidesmosomes.

3.6 Hoof wall growth

The hoof wall grows throughout the life of the horse. Continual regeneration of the hoof wall occurs at the coronary band where epidermal basal cells undergo mitosis, producing populations of daughter cells that mature, keratinise and harden, continually adding to the hoof wall at the coronet. This is to make good the continual loss of hoof wall occurring at the ground surface. The primary epidermal lamellae are part of the hoof wall and grow downwards with it. The keratinized axis of each primary lamella slides past the cells of the secondary epidermal lamellae that do not move because of their commitment to suspending the distal phalanx. The basal cells of the lamellae must remain attached to their underlying basement membrane if the hoof distal phalanx attachment mechanism is to function properly (Figure 3.7).

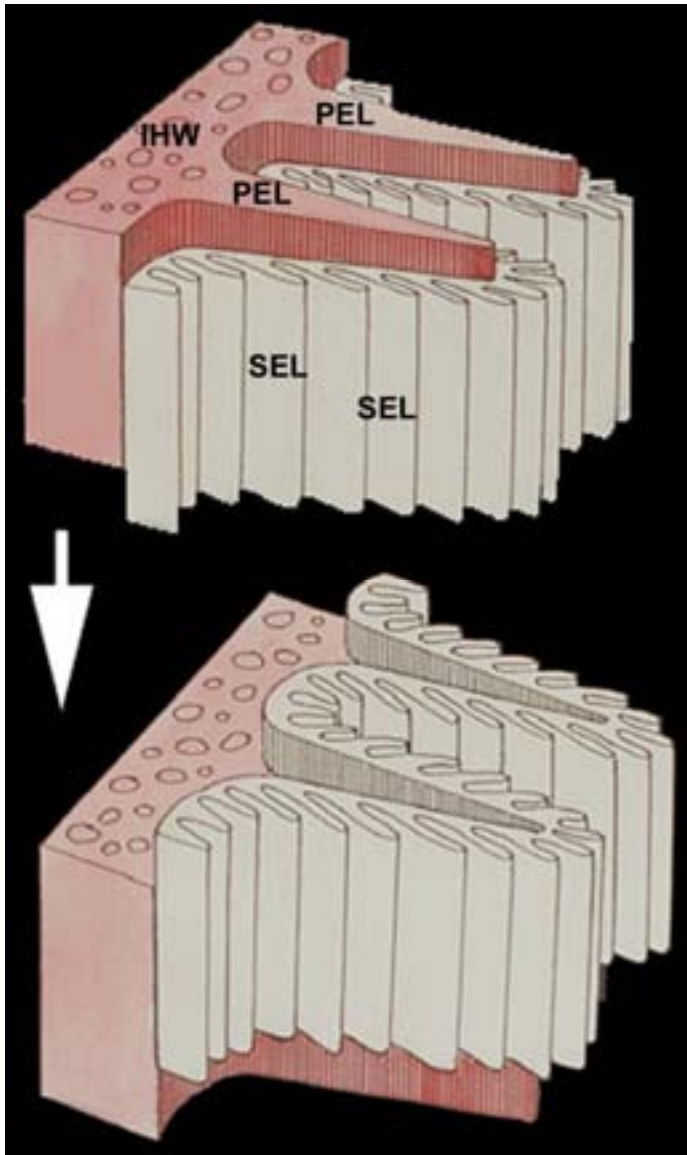


Figure 3-7 Diagram of hoof wall growth.

The hoof wall grows throughout the life of the horse. At the ground surface the distal rim of the wall is lost to wear and abrasion or, if the horse is shod, by periodic removal by a farrier. Continual loss requires continual regeneration and this occurs at the coronary band where the epidermal germinal cells produce populations of new cells which, as they mature, are added to the proximal hoof wall. The primary epidermal lamellae are part of the hoof wall and their loss at the ground surface is also accounted for by epidermal proliferation on the inner shoulders of the coronary groove. Because the germinal cells of the epidermal lamellae must remain attached to their basement membrane (to maintain the hoof distal phalanx attachment) it is assumed that the primary epidermal lamellae remodel past the stationary cells of the secondary epidermal lamellae in a staggered sequence of detachment and reattachment. Only a small percentage of the cells are detached at any one time (rather like a ratchet) so that the distal phalanx never loses its suspensory attachment to the inner hoof wall. IHW = inner hoof wall. PEL = primary epidermal lamella. SEL = secondary epidermal lamella.

3.7 Lamellar remodeling enzymes

The cells of the lamellar epidermis remodel and continually upgrade their spatial organization by the tightly controlled production (Kyaw-Tanner and Pollitt 2004) of a class of zinc-containing enzymes known as matrix metalloproteinases (MMPs). Two members of the MMP family (MMP-2 and MMP-14) are present in normal hoof wall lamellae (**Figure 3.8**).

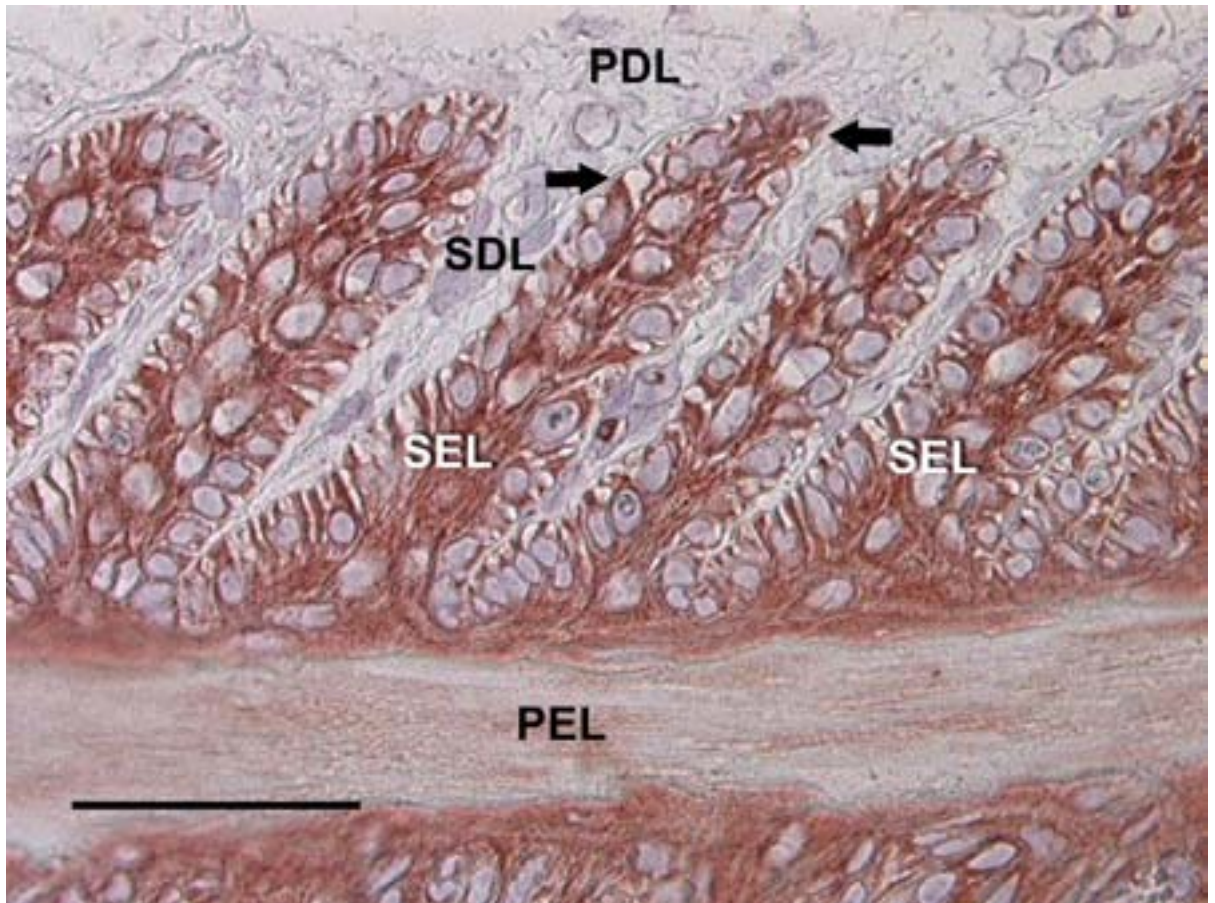


Figure 3-8 Micrograph showing immunolocalisation of matrix metalloproteinase (MMP-2) in the hoof wall lamellae

The brown staining cytoplasm shows where anti MMP-2 antibodies have reacted with MMP-2 protein, resident in the cells. Most of the SEL basal and parabasal cell cytoplasm contains MMP-2 reflecting the high requirement for remodeling in this tissue. MMP positive cytoplasm is closely associated with the basement membrane (arrows). The PELs however stain lightly for MMP-2 suggesting a relatively low rate of remodeling. Controlled MMP activity allows the movement of the various classes of epidermal cells between the lamellar basement membrane, the secondary epidermal lamellae (SEL) and primary epidermal lamellae (PEL). MMPs are manufactured and secreted as inactive proenzymes and are only activated to allow the nips and tucks required for continual growth and movement within the lamellae. Bar = 50 μ m.

Controlled MMP activity allows the movement of the various classes of epidermal cells between the lamellar basement membrane, the secondary epidermal lamellae and primary epidermal lamellae. MMPs are manufactured and secreted as inactive proenzymes, and are only activated to allow the nips and tucks required for continual growth and movement within the lamellae. When activated, locally produced inhibitors (tissue inhibitors of metalloproteinases or TIMPs) promptly inhibit MMP. In normal hoof lamellae harmony prevails. However, with their large surface area and their all-important function of suspending the distal phalanx, the hoof lamellae can be likened to a loaded gun. The protein constituents of the basement membrane (type IV collagen and laminin) as well as

hemidesmosome anchoring filaments (laminin-5), are known substrates of MMP-2 and MMP-14. We believe that the disorganisation of the epidermal cells of the secondary epidermal lamellae, the wholesale separation of basal cells from the basement membrane, and the lysis of basement membrane that occurs early in the pathology of most forms of laminitis, are caused by uncontrolled, excessive MMP activation.

3.8 Lamellar metabolism

Despite much speculation regarding insulin resistance, glucose metabolism and their links to laminitis there is little information regarding if, where and how glucose is consumed by the living cells of the equine hoof. To address this we investigated if glucose is consumed by the equine hoof and if glucose uptake into hoof epidermal cells is insulin dependent (Wattle and Pollitt 2004). Blood glucose concentrations were recorded in seven adult horses by simultaneously taking samples from three blood vessels; an artery, the jugular vein, and a digital vein at the level of the pastern of one of the front legs. Antibody towards glucose transport proteins (GLUTs) and the insulin receptor was used for immunolocalisation of these proteins in the gluteus muscle and in the feet of 7 horses. We found that the foot of a horse consumes more glucose than its head. The insulin independent GLUT1 was the major epidermal cell glucose transporter of the hoof. In contrast to the gluteus muscle, hoof lamellae do not rely on insulin for glucose uptake. Thus in terms of metabolic activity the division of the hoof into sensitive and insensitive layers is no longer tenable. Glucose supplies the energy essential to maintain the integrity of the equine hoof epidermal/dermal interface. We also measured the lactate concentrations in the same blood samples. The amount of lactate generated by the foot exceeded that of the head indicating that the foot is not only capable of anaerobic metabolism but depends on it to produce energy. Biochemical staining for lactate dehydrogenase showed a strong reaction in the lamellar basal cell layer. Thus lamellar tissues appear to be anaerobic and may be quite indifferent to the oxygen (but not the glucose) status of their blood supply. This argues against theories that rely on lamellar hypoxia to explain laminitis pathogenesis.

3.9 Key Points

- *The primary epidermal lamellae that line the inner hoof wall function to secure the distal phalanx within the hoof capsule. Secondary epidermal lamellae, located along the length of each primary lamella, increase the surface area to provide better attachment.*
- *The basement membrane connects the basal cells of the secondary epidermal lamellae and the connective tissue of the secondary dermal lamellae at specialised junction sites called hemidesmosomes.*
- *Anchoring filaments, consisting of laminin-5, bridge the gap between the hemidesmosomes and the basement membrane.*
- *Lamellar basal cells consume glucose via glucose transporter proteins without the involvement of insulin.*

4. Laminitis in Perspective

4.1 The laminitis literature

Much has been written on the subject of laminitis. There are records dating back to ancient times and the disease is probably as old as mankind's dual historical association with horses and grain over the last 2000-3000 years. There is no human medical equivalent to laminitis and veterinary science has been left on its own to elucidate the mechanism of this disease. The closest disease parallel is perhaps the obscure human disease epidermolysis bullosa where autoantibodies interfere with basement membrane attachment proteins and cause sheets of skin to separate along the dermo-epidermal junction. As humans walk on padded hock joints and don't rely on hooves, in principle still skin-like structures, we can be forgiven for missing the pathological link (if there is one). Laminitis does not appear to fit into any familiar, disease-causing pattern, despite, as you will read below, years of trying to fit this very square peg into several round holes. It is easy to describe the signs of laminitis and diagnose it once it has occurred. This is not the problem. What is required is an understanding of the disease process so that preventive, even curative, strategies can be developed. This is the only hope for horses and laminitis.

Once the lamellar foundations have been significantly damaged, the continuous physiological strain on the hoof dermo-epidermal junction makes repair virtually impossible. Laminitis appears to be less of a disease, but more of a natural process gone wrong. Rather like the workings of the worst malignant cancer; a process that still defeats the best medical minds of human medicine.

The laminitis research conducted during the last decade at the AELRU of School of Veterinary Science at The University of Queensland, with the help of RIRDC funding, was undertaken in the context of scientific dogma, much of it published in textbooks and journals and accepted as fact. This chapter reviews some key points of laminitis knowledge to put the current work of the Australian Equine Laminitis Research Unit in an historical perspective.

4.2 The developmental phase

A 30-40 hour developmental phase, during which lamellar separation is triggered, precedes the appearance of the foot pain of laminitis. During the developmental phase, and prior to the clinical appearance of foot pain, the horse or pony usually experiences a problem with one or more of the following organ systems: gastrointestinal, respiratory, reproductive, renal, endocrine, musculoskeletal, integumentary and immune. Multi-systemic aberrations in organs anatomically remote from the foot result in the lamellar tissues of the feet being exposed to factors that lead to separation and disorganisation of lamellar anatomy. The exact nature of the laminitis trigger factors, apparently reaching the lamellar tissues via the circulation, has yet to be fully elucidated.

Sometimes no developmental phase is recognised; the horse or pony is discovered in the acute phase with no apparent ill health or inciting problem occurring beforehand. The intramuscular injection of potent, long-acting, corticosteroid preparations for the treatment of skin disease may precipitate iatrogenic (man-made) acute laminitis.

4.3 The acute phase

The developmental phase merges into the acute phase of laminitis when the first signs of foot pain appear (Figure 4.1). The acute phase lasts from the onset of clinical foot pain and lameness at the walk and trot, to the time when there is clinical evidence of displacement of the distal phalanx within the hoof capsule. Some fortunate horses experience the foot pain of acute laminitis, but do not develop distal phalanx displacement and appear to make a complete recovery.

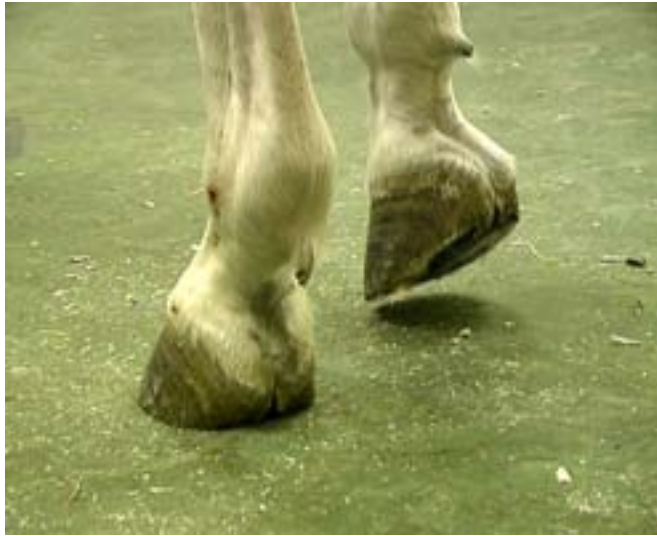

Figure 4-1 *A horse with acute laminitis shifting weight from one foot to the other. Laminitis usually affects the forefeet more severely than the hind; presumably because the forequarters carry a greater proportion of the horse's weight (about 65%). Often the hind feet appear to be spared completely. The shifting weight behaviour of horses with laminitis is undoubtedly performed to relieve pain. The common explanation is that when the pain in one foot becomes unbearable the foot is lifted off the ground. Pain then mounts in the weigh-bearing foot until the horse feels compelled to relieve it by shifting weight to the other foot.*

4.4 The chronic phase

After the acute phase, if the horse does not die from the disease process inciting the development of laminitis, it will develop some degree of downward displacement of the distal phalanx within the hoof capsule, the hallmark of chronic laminitis. Early displacement of the distal phalanx within the hoof capsule can be detected with good quality radiographs. The chronic phase can last indefinitely with clinical signs ranging from persistent, mild lameness, continued severe foot pain, further degeneration of lamellar attachments, to penetration of the sole of the hoof by the distal phalanx (Figure 4.2),

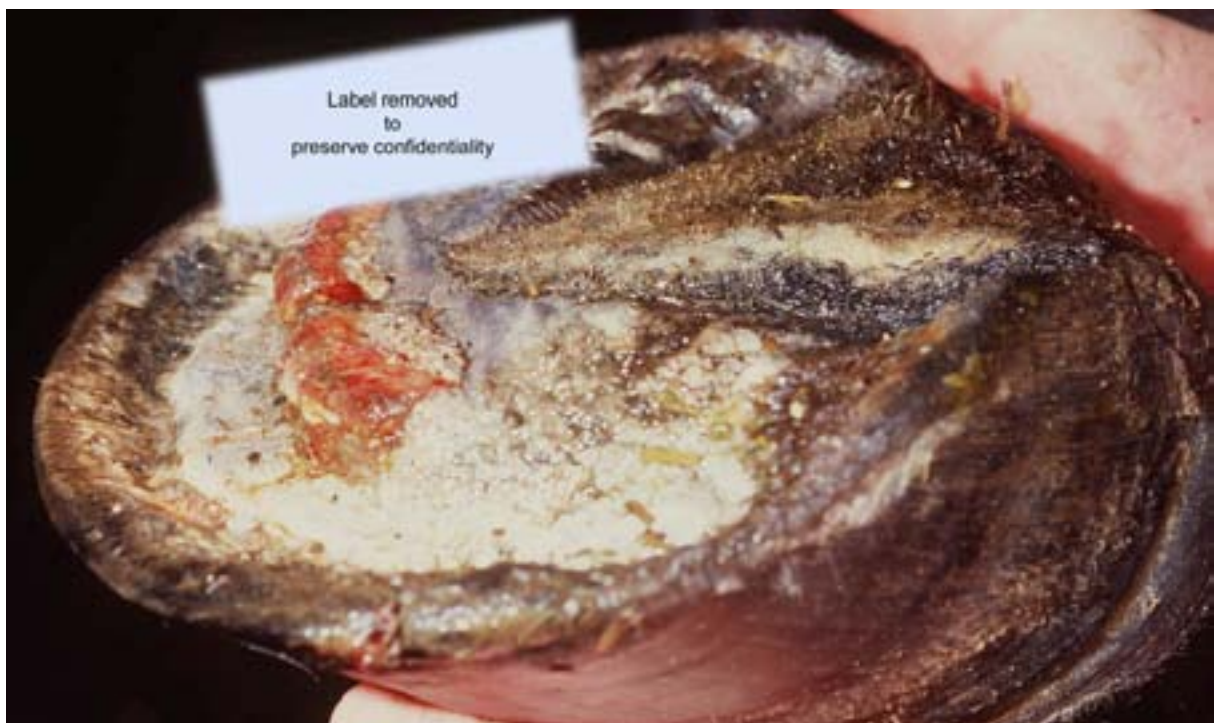


Figure 4-2 *Prolapse of the distal phalanx through the sole of the foot.*

After giving birth to her foal this 17-hand Warmblood mare failed to pass the foetal membranes and developed acute severe metritis (infection of the uterus). Two days of septicaemia and fever followed and the mare then began to show the clinical signs of laminitis. Within 20 days the tip of the third phalanx was protruding through the sole of the foot.

recumbency, hoof wall deformation, osteomyelitis of the distal phalanx and even sloughing of the hooves. With increasing chronicity, the hoof wall and the distal phalanx lose their normal parallel arrangement and become increasingly separated by a wedge of keratinised material called the lamellar wedge. The distal phalanx rotates and is no longer in line with the proximal and middle phalanges (the long and short pastern bones) (Figure 4.3).

It is important to realise that the process initiating the destruction of the lamellar attachment apparatus begins to operate during the developmental phase, before foot pain, the first clinical sign of laminitis, appears. During the developmental phase, the specific problems of the horse often have to be attended to urgently (e.g. colitis, retained placenta, pleuropneumonia and rhabdomyolysis) and unfortunately the feet may not enter into the therapeutic equation until the signs of foot pain appear. By the time foot pain is apparent, lamellar pathology is underway. In other words, foot pain is the clinical sign that lamellar disintegration is occurring. To wait and see if foot pain is the sequel to a metabolic crisis is to miss the opportunity to prevent or at least ameliorate lamellar pathology.

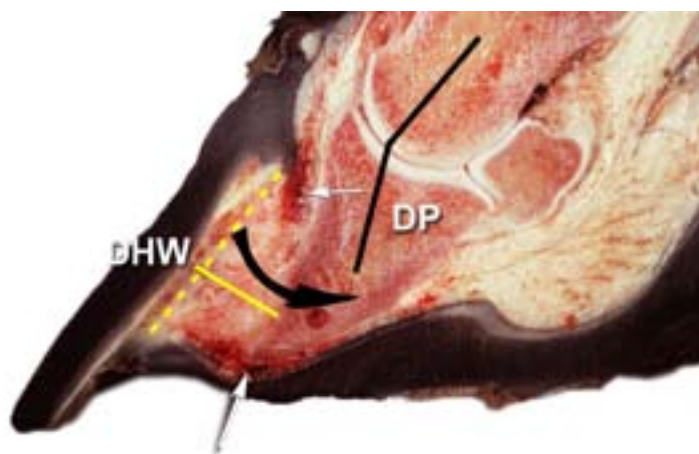


Figure 4-3 *Sagittal section of a foot with severe chronic laminitis and a large lamellar wedge.*

A feeding mistake caused this 2-year old Thoroughbred racehorse to founder. The attachment between the distal phalanx (DP) and the dorsal hoof wall (DHW) has failed and hoof and bone are now widely separated (compare with Fig 2.2). The dotted yellow line shows the original position of the distal phalanx. The solid black line shows that the distal phalanx has rotated (in the direction of the curved

black arrow) off the normally straight axis of the proximal and middle phalanges. The material now between the inner hoof wall and the bone is abnormal and consists of epidermal tissue proliferating to form a weak, disorganised mass called the lamellar wedge (yellow line). The descent of the unattached distal phalanx into the hoof capsule has distorted the growth of the proximal hoof wall tubules and caused the sole to become convex instead of concave (dropped sole). Two dark haemorrhagic zones (white arrows) show the sites of greatest pressure and trauma.

4.5 The Obel grades of lameness

In 1948, the pioneering Swedish veterinarian Nils Obel graded the lameness associated with overt laminitis according to its clinical severity (Obel 1948). Horses with Obel grade I laminitis shift weight from one foot to the other, but will move relatively freely. With Obel grade II laminitis, the lameness is more obvious, especially when turning, and the gait is stilted and shuffling. One foot can be lifted without causing extreme discomfort in the contralateral foot. In Obel grade III laminitis, the horse is reluctant to move and resists any attempt to lift a foot because of the pain this will induce in the contralateral foot. Obel grade IV laminitis is the most severe grade and the horse is immobile and often recumbent. There is a good correlation between Obel grade lameness and the severity of lamellar histopathology. The clinical significance of this will be discussed later.

4.6 Laminitis is a sequel to an event remote from the foot

Laminitis can result from a variety of seemingly unrelated pathological events occurring elsewhere in the body. However, most often, the pathology involves the gastrointestinal tract. Excess consumption of grain or carbohydrate rich pasture, duodenitis/proximal jejunitis, colitis, the acute abdomen of colic, and acute febrile diarrhoea can all precipitate laminitis. Non-gastrointestinal causes such as retained placenta, septic metritis, pneumonia/pleuritis can also cause laminitis and have septicæmia and

endotoxemia in common with gastroenterological causes of laminitis. Horses that severely “tie-up” (develop severe rhabdomyolysis) may also develop laminitis, for reasons that are currently unexplained. Alimentary carbohydrate overload laminitis, commonly called “grain founder,” has become one of the better understood mechanisms of laminitis. It can be induced experimentally and has become a model with which to study laminitis.

4.7 Grass founder

Ponies, and occasionally horses, will develop laminitis or “grass founder” while grazing on pasture. Under certain conditions of climate, a soluble sugar called fructan may reach very high concentrations in the stem of grass (up to 50% dry matter). When consumed, fructan (or oligofructose) is rapidly fermented by hindgut microorganisms, triggering a gastrointestinal disturbance that somehow leads to laminitis. Mammals have no enzyme to digest fructan, so when consumed it passes undigested into the caecum where it undergoes rapid microbial fermentation causing a population explosion of hindgut streptococci. This hypothesis is supported from practical experience with a patented formulation of the antibiotic virginiamycin (Founderguard, Virbac Australia). When fed to horses Founderguard specifically knocks out hindgut streptococci. Without these bacteria in the hindgut excess pasture fructan can be consumed safely without the risk of laminitis. When given to grass fed ponies (four days ahead of access to the risky pasture) Founderguard prevents laminitis in situations where the risk of laminitis is normally high.

4.8 Grain founder

In field cases, grain founder occurs following the consumption of excessive amounts of grain, either from accidental access by the horse or by a misguided, intentional, dietary increase by its keeper. Although the amount of grain required to induce laminitis varies between individuals, the consumption of 5-8 kg of wheat grain by the average 400-450kg horse causes faecal acidity (pH 4-5 instead of the normal 6.8-7.5), lactic acidemia, profuse watery diarrhoea and fever, all of which are associated with laminitis. The likelihood of laminitis following grain consumption correlates directly with the starch content of the grain, the amount which passes undigested to the hindgut and the rate at which the undigested carbohydrate is fermented. The type of grain and the manner in which it is processed in the stomach and small intestine are also important in determining the amount of starch that passes undigested to the hindgut. Grains such as wheat, sorghum, corn and barley are considered to be most dangerous with respect to the risk of laminitis. The feeding of oats is relatively safe. Gorging on bread can result in significant amounts of readily fermentable carbohydrate passing to the hindgut and is also a recorded cause of laminitis.

4.9 Alimentary carbohydrate overload model

Much of what we know about laminitis and the metabolic events surrounding it has been derived from studies on horses that have been experimentally dosed with excess soluble carbohydrate (the alimentary carbohydrate overload model). The diet of horses in their natural state is grass and legume based and consists mainly of complex, structural carbohydrates in the form of cellulose, hemicellulose and lignin or non-structural carbohydrates (NSC) in the form of sugars, fructans or starch. The structural carbohydrates and fructans are indigestible to mammals without the aid of active microbial hindgut fermentation and a large portion of the equine abdomen is occupied by the caecum and colon where complex carbohydrates and fructans are fermented to absorbable end products.

Domestic horses and ponies sometimes encounter large quantities of starch and fructan in their diet when they consume cereal grain or the sward of certain cultivated pastures. Pony breeds, having evolved metabolic adaptations for survival in harsh, low nutrient environments, are particularly prone to laminitis, if given unrestricted access to cultivated pasture. Most of the consequences of carbohydrate overload occur after the arrival of the carbohydrate in the hindgut and relate to the rapid proliferation of hindgut bacteria flourishing in the presence of excess substrate.

Upon mixing with the normally neutral caecal contents, excess starch or fructan undergoes rapid fermentation to lactic acid. With the arrival of more and more substrate, fermentation continues and

the unnaturally acidic conditions favour the rapid proliferation of the Gram positive bacteria *Streptococcus bovis* and *Streptococcus equinus* (Milinovich et al. 2007; Milinovich et al. 2006). This results in very acidic conditions in the hindgut with pH as low as 4. Two isomers of lactic acid, D- and L-lactate, are produced in almost equal proportions by bacterial fermentation in the equine hindgut. However, only L-lactate is produced by the metabolic activities of mammals, so the concentration of D-lactate in venous blood can be used as an accurate indicator of bacterial lactic fermentation in the hindgut (van Eps and Pollitt 2006).

Low pH in the large intestine initiates a series of secondary events that often, but not always, culminate in laminitis. One of the most important consequences is the death and lysis of large numbers of bacteria and the release of the toxic components of their cell walls and genetic material (endotoxins, exotoxins and microbial DNA). Toxins absorbed from the gut into the bloodstream during developmental laminitis and toxæmia following alimentary carbohydrate overload creates a very severe illness for the horse. Interestingly, experimental administration of endotoxin itself has never been able to cause laminitis. In addition, endotoxæmia can be effectively controlled by a range of drugs (e.g. polymyxin B, flunixin meglumine [Finadyne]) and laminitis develops regardless of their use.

As early as 24 hours after carbohydrate overload, the epithelial cells lining the caecum undergo degenerative changes and the bowel becomes leaky. By 48-72 hours there is widespread desquamation and sloughing of caecal epithelial cells sufficient to allow passage of lactic acid, toxins and laminitis trigger factors into the circulation (**Figure 4.4**). The consequences can be catastrophic. About 10-15% of horses die from cardiovascular shock after the accidental consumption of excess grain. High heart rates, rapid breathing, fever, sweating, colic, diarrhoea and depression are the signs of horses battling grain overload. Just when the horse turns the corner and responds to treatment and the severity of the clinical signs decreases, the signs of foot pain appear; laminitis has arrived on the scene.

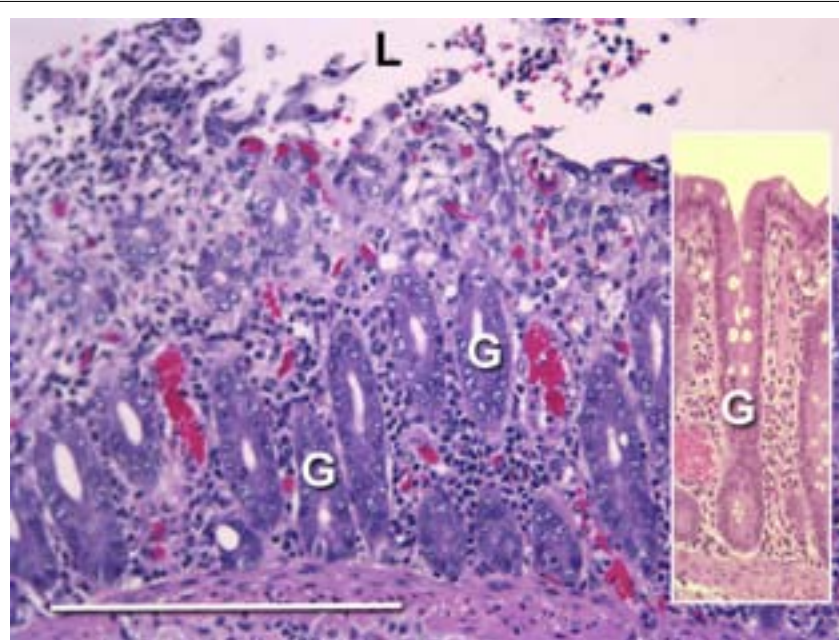


Figure 4-4 Micrograph of the leaking hindgut of a horse developing carbohydrate overload laminitis.

The hindgut lumen normally has an intact layer (the mucosal barrier) of tightly joined epithelial cells covering its surface (inset). This prevents harmful bacteria and their toxins from being absorbed into the circulation. The hindgut wall is glandular and the cells of the mucosal barrier line both the glands (G) and the lumen (L) of the bowel. During colitis the mucosal barrier is

damaged providing a pathway for laminitis trigger factors to enter the circulation and eventually cause laminitis when they reach the feet. H&E stain. Bar = 100 µm.

4.10 Use of Virginiamycin to prevent laminitis

The bacteria responsible for lactic acid production, as a result of carbohydrate overload are sensitive to a range of antibiotics. The laminitis inducing effect following carbohydrate overload does not occur if the activities of the bacteria are controlled. Virginiamycin, in the patented formulation Founderguard (Virbac Australia), administered at 5g/kg body weight, 4 days before carbohydrate overload, prevented laminitis and D-lactic acid production in all cases (Pollitt 1996). The correct formulation of virginiamycin is important for the active ingredient to enter and mix properly with the caecal and colonic digesta. Unfortunately, virginiamycin has to be present in the caecum before the arrival of carbohydrate for laminitis prevention to occur. When virginiamycin was administered 6-8h after dosing with carbohydrate, laminitis did occur. For this reason Founderguard is considered a useful laminitis prophylactic for horses and ponies with a high carbohydrate intake, but has little value therapeutically.

4.11 Lamellar blood flow etiology

Despite decades of research, the exact cause of the failure of the lamellar suspensory mechanism is still being debated by veterinary scientists. A common explanation is that lamellar blood flow is somehow compromised during the developmental phase of laminitis and this causes ischaemic (blood supply failure) necrosis of lamellar tissues. Without oxygen and the supply of the energy required to maintain adhesion between lamellar epidermal cells and their basement membrane, the structure fails. Plausible as this idea seems, the laminitis literature is quite divided on the subject of sublamellar perfusion. Is laminitis caused by dilation or constriction of lamellar blood vessels? Are the lamellae perfused or not prior to the appearance of lamellar pathology?

4.12 Vasoconstriction theories

Studies of horses with acute laminitis, made using X-rays and radiopaque dyes (similar to the technique used in humans to determine the amount of tissue muscle damage after heart attacks and strokes) showed that the blood supply to the lamellar region was indeed compromised (Coffman *et al.* 1970). However, the decreased lamellar perfusion observed was based on blood vessel studies made when clinical laminitis was already underway. The vessel constriction and reduced digital blood flow demonstrated was likely the result of lamellar injury rather than the cause of it.

Other studies used small radioactive particles that lodged in the lamellar capillaries of normal horses causing the feet to become strongly radioactive. The radioactivity was detected using a gamma camera by the technique known as scintigraphy. When horses have laminitis, the capillary sized particles no longer lodge in the foot and bypass the lamellar circulation. Vascular shunts between arteries and veins are present in the lamellar circulation and it was because these structures were open that the particles bypassed the capillary circulation. The technique showed that a decrease in lamellar capillary perfusion was present in horses with acute laminitis. The question that was not answered was “did the vascular shunting cause the laminitis?” Many have been satisfied that this was the case, but the evidence needs closer scrutiny. The experiments were performed after lamellar pathology had occurred and therefore cannot be used to imply pathogenesis. During the experiments, foot blood flow actually increased during the developmental phase, until just prior to the onset of clinical laminitis (Hood 1978).

4.13 Vasodilation theories

In contrast to the popular vasoconstriction/ischaemia theories, experiments that measured digital blood flow directly during developmental and acute laminitis showed that blood flow actually increased (vasodilation) prior to the development of laminitis foot pain. Many researchers do not support lamellar ischaemia as a primary cause of laminitis. Noninvasive, scintigraphic studies of the digital circulation show a statistically significant elevation of sublamellar blood flow prior to lameness (Trout *et al.* 1990).

4.14 Vasodilation is associated with laminitis

To determine if it was lamellar vasoconstriction or vasodilation which preceded laminitis, lamellar hoof temperature was measured continuously in horses at risk of developing laminitis in a variety of clinical situations (Pollitt and Davies 1998). Variations in hoof temperature were assumed to signify fluctuations in lamellar blood flow. The unambiguous presence or absence of laminitis was based on histopathological grading of lamellar tissues of horses that were euthanased for humane reasons. Analysis of mean hoof temperature graphs showed that the 6 horses judged laminitis positive had experienced a period of prolonged digital vasodilation during the developmental phase. The 8 laminitis negative horses experienced no such period of vasodilation and had hoof temperatures never significantly above that of normal horses. Despite the horses appearing equally ill with similar clinical signs of fever, gut stasis (paralytic ileus), diarrhoea, elevated heart rate and low faecal pH, the only parameter which significantly differentiated the laminitis positive from laminitis negative horses, during the developmental phase was foot temperature. Thus for laminitis to occur, a period of sublamellar vasodilation during the developmental phase had occurred (**Figure 4.5**). If the digital circulation was vasoconstricted during this period then laminitis did not occur.

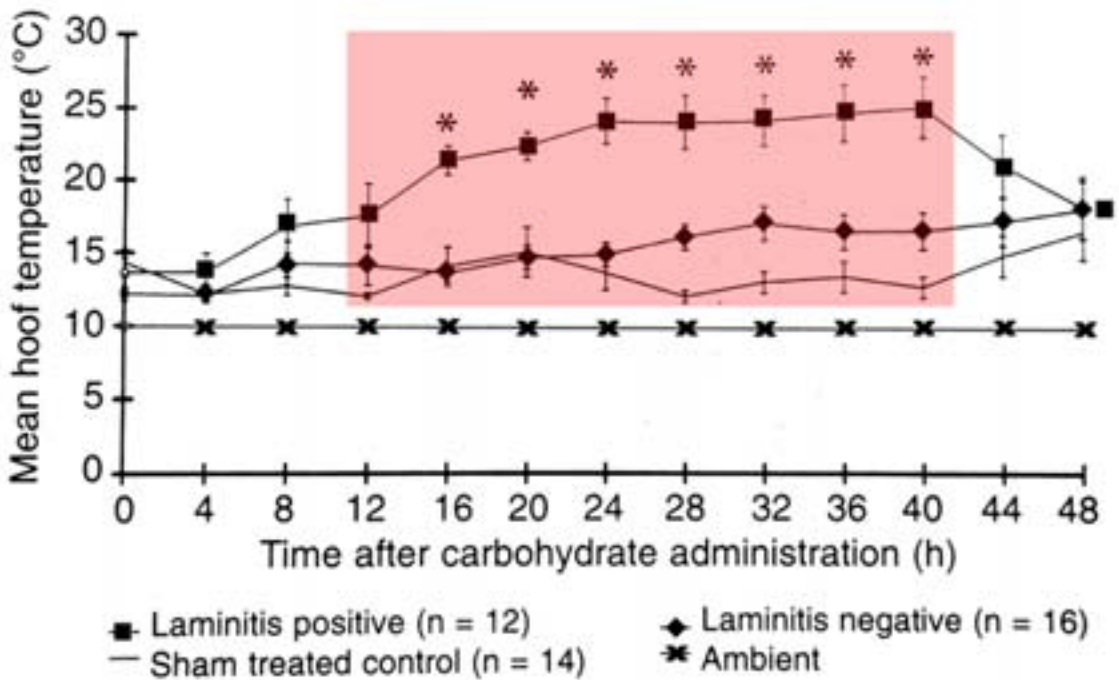


Figure 4-5 Mean temperatures (\pm standard error) of hooves from laminitis positive, laminitis negative and untreated control horses.

All horses that passed through the laminitis development phase (pink box) with significantly (*) hot, vasodilated feet developed laminitis. Horses that kept their feet cool did not have laminitis at the end of the development period. The control horses had foot temperatures similar to the laminitis negative horses. All horses were housed in a climate controlled laboratory with an ambient temperature set at 10°C . The results suggested that a period of sublamellar vasodilation was required before laminitis would occur.

It was assumed that the period of increased digital perfusion in laminitis positive horses, concomitant with the severe metabolic crisis brought on by alimentary carbohydrate overload, metritis/retained placenta or pleuropneumonia exposed lamellar tissues to a concentration of blood borne factors sufficient to trigger lamellar separation. A hypothesis that lamellar separation could occur if uncontrolled MMP activation damaged the lamellar basement membrane was developed. Evidence that metalloproteinase production increased and metalloproteinase activation occurred was required for this theory to be validated.

4.15 Key Points

- A problem with one or more of the major organ systems produces trigger factors that cause lamellar separation during the developmental phase of laminitis. The appearance of clinical foot pain and lameness marks the start of the acute phase of laminitis.
- Acute laminitis usually progresses to chronic laminitis with downward displacement of the distal phalanx within the hoof capsule causing varying degrees of lameness (Obel grading) depending on the extent of the lamellar pathology.
- Disturbances of the gastrointestinal tract are commonly involved in the pathology of laminitis. These problems are often caused by the consumption of excess starch or fructan when animals consume large amounts of grain or have unlimited access to pasture, respectively.
- In the caecum, the presence of excess starch or fructan produces an environment that favours the rapid proliferation of Gram-positive bacteria that produce lactic acid and causes the release of endotoxin from Gram-negative bacteria.
- Control of lactic acid-producing bacteria by virginiamycin, administered prior to carbohydrate overload, prevents laminitis and D-lactic acid production by bacteria.
- A period of sub-lamellar vasodilation occurs during the developmental phase in horses that become laminitic, raising the possibility of blood borne laminitis trigger factors.

5. Laminitis: Current Concepts

5.1 Introduction

The prefix of the word *laminitis* correctly identifies the laminae, or more correctly, lamellae of the inner hoof wall as the focus of laminitis pathology. The suffix *-itis* implies a role for inflammation. The hoof wall lamellae are certainly inflamed in the acute phase. Tissue damage has occurred; there is pain, redness and swelling beneath the hoof wall. The mystery is why?

In acute laminitis, the tissue suspending the distal phalanx from the inner hoof wall fails, specifically at the junction between the connective tissue of the dermis or corium (the bone side) and the basal cell layer of the epidermal lamellae (the hoof side). This junction, the basement membrane zone, appears to be the weak link in an otherwise robust and reliable structure. In acute laminitis there is wholesale epidermal cell detachment from, and lysis of, the lamellar basement membrane and this leads to failure of the lamellar anatomy and, ultimately, failure of the suspensory attachment between hoof and distal phalanx. There is a good correlation between the grade of severity, as seen with the microscope (histopathology), and the degree of lameness (using the Obel grading system) shown by the horse (Pollitt 1996). Thus, when the horse first starts to show the foot pain of laminitis, it means that the anatomy of the hoof wall lamellae is being destroyed. The worse the lameness, the worse the damage. Any activity that places stress on an already weakened lamellar attachment apparatus (such as forced exercise) will cause further damage and is contraindicated. The use of nerve blocks to eliminate pain will encourage locomotion and do more damage.

5.2 The laminitis process

The spectacular disintegration of the lamellar attachment apparatus, initiated during the developmental phase of laminitis, renders a normally robust and trouble-free epidermal/dermal system useless in a relatively short period of time. Logic indicates that somehow this normally tightly-controlled, metabolic process is thrown into disarray to cause the lamellar specific lesion during the laminitis developmental period. Our evidence suggests that it is the enzymatic remodelling of the epidermal lamellae, assumed to be essential if the continually proliferating hoof wall is to move past the stationary distal phalanx, that is activated beyond control to destroy the lamellar attachment apparatus. The enzymes that destroy the key components of the lamellar attachment apparatus are metalloproteinase -2 and metalloproteinase -14 (MMP-2 and MMP-14). These enzymes are also found in a wide range of other remodelling tissues such as bone, joints and endometrium, as well as in metastasizing malignant tumours (**Figure 3.8**). An additional metalloproteinase, MMP-9, is also present in laminitis affected tissue but this seems to be derived from white blood cells that have been attracted to the lamellar zone during laminitis development (Black *et al.* 2006).

Normal MMP activity is constantly responding to the stresses and strains of equine life as well as to constant growth. When called for, sufficient MMP is manufactured locally to release epidermal cell to cell, and cell to basement membrane attachment, as required, maintaining the correct shape and orientation of the lamellae. From time to time, injury to the basement membrane would require its lysis and reconstruction. The controlled release of specific MMP inhibitors keeps the remodelling process in equilibrium. The hoof lamellae and the hoof itself slowly migrate past the stationary basement membrane that is firmly attached to the connective tissue covering the upper surface of the distal phalanx.

The sequences of microscopic events that initiate laminitis follow a consistent pattern and the stages of histological laminitis can be identified according to the degree of severity of these changes. It was therefore possible to develop a grading system for the histopathology of laminitis, based on changes to several key parameters of hoof lamellar anatomy. At the AELRU, we created a laminitis assessment system, initially by staining lamellar tissues with haematoxylin and eosin (H&E) and periodic acid Schiff (PAS) and later with immunohistochemical methods using basement membrane (BM) specific antibodies (Pollitt 1996; Pollitt and Daradka 1998). Making the basement membrane clearly visible led to the realization that laminitis was essentially a basement membrane lesion.

The normal anatomical characteristics that are assessed before allocating a laminitis grade to a section of lamellar hoof tissue are as follows. The tips of the secondary epidermal lamellae (SELs) are always rounded (club-shaped) and never tapered or pointed. The basal cell nuclei are oval in shape with the long axis of the oval at a right angle to the long axis of the secondary epidermal lamella. These parameters can be satisfactorily assessed using routine haematoxylin and eosin (H&E) staining of sections. The basement membrane penetrates deeply into the crypts between the SELs and outlines the wafer thin, but connective tissue filled, secondary dermal lamellae. The basement membrane is tightly adherent to the basal cells of each SEL. The PAS stain show this best (**Figure 5.1**).

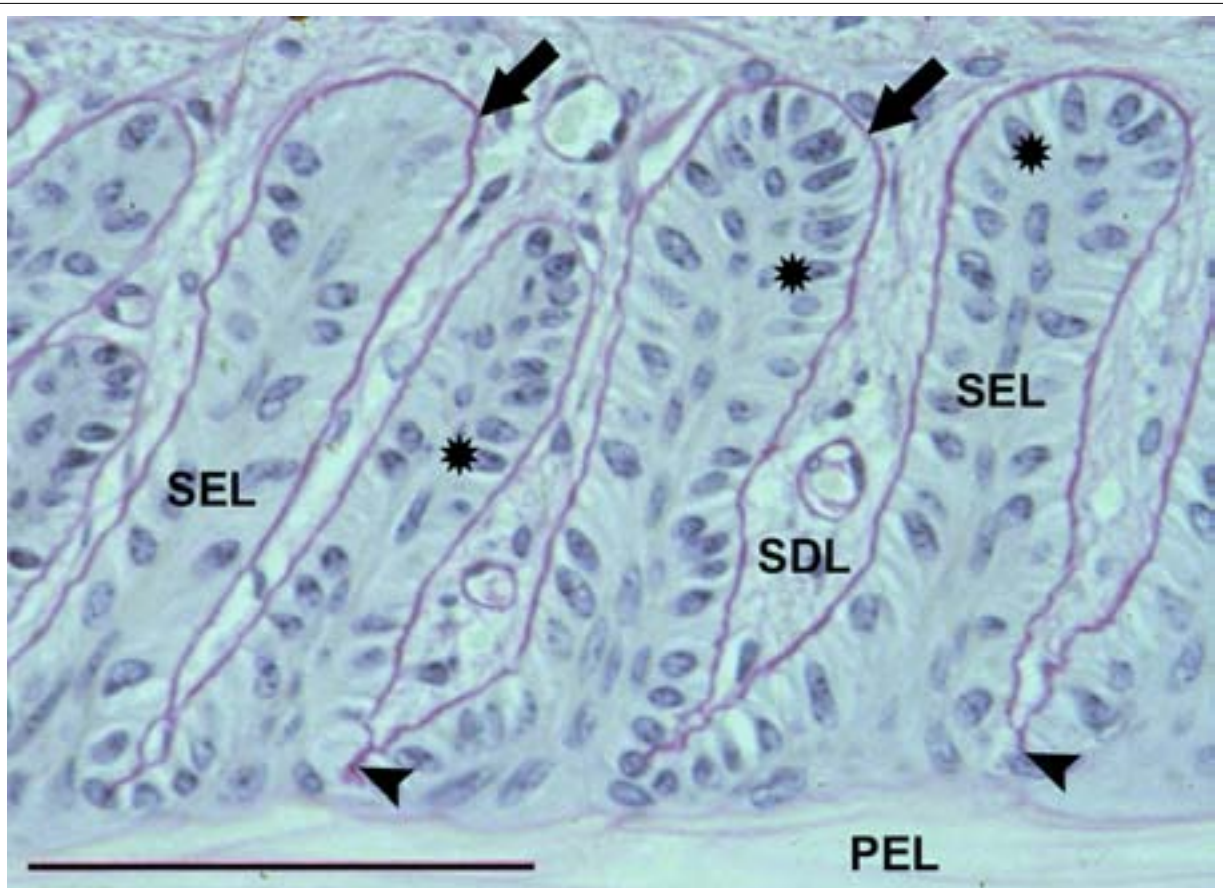


Figure 5-1 Micrograph of normal hoof lamellae stained to highlight the basement membrane

The basement membrane (arrowed) of each secondary epidermal lamella (SEL) shows as a dark, magenta line closely adherent to the SEL basal cells. Between the bases of each SEL the BM penetrates deeply (arrowheads) and is close to the anuclear, keratinised, primary epidermal lamella (PEL). The SEL tips are rounded (club-shaped). The basal cell nuclei are oval in shape (stars) and positioned away from the BM at the apex of each cell. The long axis of each basal cell nucleus is at right angles to the long axis of the SEL. The secondary dermal lamellae (SDL) are filled with connective tissue, even at their very tips, between the SEL bases. These parameters of hoof lamellar anatomy form the basis of the histological grading system of laminitis histopathology. Stain = PAS. Bar = 10 μ m.

The microanatomy of lamellar basal cells is similar when ultrathin sections are studied with the transmission electron microscope (TEM). The difference is that the magnified basement membrane and the hemidesmosomes can be observed with great clarity. The number of hemidesmosomes can be counted and the distance between the basal cell and the lamina densa can be measured (French and Pollitt 2004b).

5.3 A histological grading system for laminitis

5.3.1 Grade 1 histological laminitis

As the developmental phase ends and the acute phase begins, the lamellar basal and parabasal cells lose their normal shape and appear to slide over one another. The basal cell nuclei become rounded instead of oval and take up an abnormal position in the cytoplasm of the cell, close to the basement membrane (**Figure 5.2**). This was the first change detectable and occurred as early as 18h in a series of lamellar hoof biopsies taken as laminitis developed. With H&E staining SELs appear stretched, long and thin, with tapering, instead of club-shaped, tips.

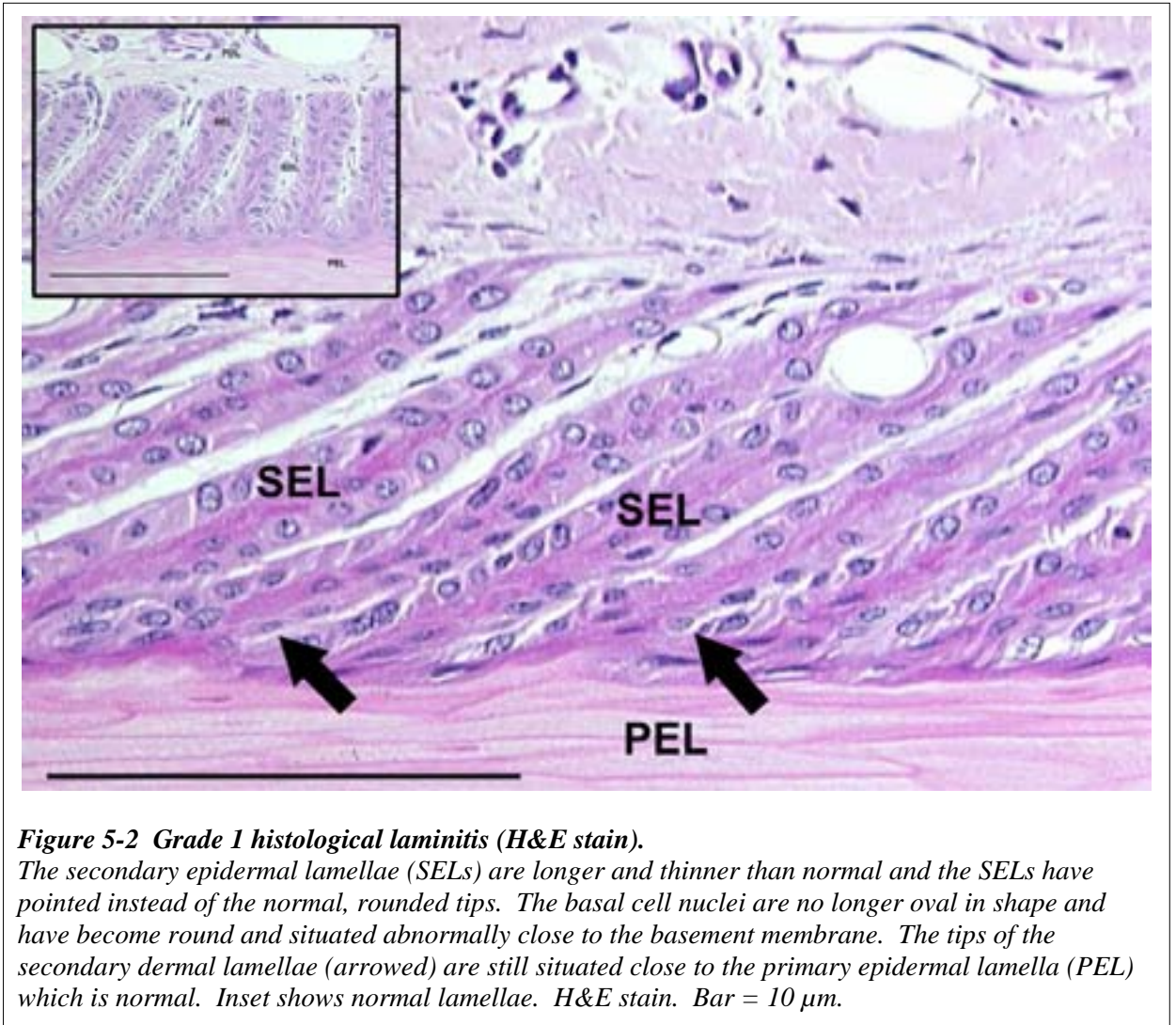


Figure 5-2 Grade 1 histological laminitis (H&E stain).

The secondary epidermal lamellae (SELs) are longer and thinner than normal and the SELs have pointed instead of the normal, rounded tips. The basal cell nuclei are no longer oval in shape and have become round and situated abnormally close to the basement membrane. The tips of the secondary dermal lamellae (arrowed) are still situated close to the primary epidermal lamella (PEL) which is normal. Inset shows normal lamellae. H&E stain. Bar = 10 μ m.

At this early stage the BM between the SEL bases is still in its normal position, close to the primary epidermal lamella. In other words the tips of the secondary dermal lamellae (arrowed in Fig 5.2) have not shifted and are still situated close to the primary epidermal lamella (PEL) which is normal. Using special connective tissue stains such as the periodic acid Schiff (PAS) stain shows that the BM separation is in fact occurring particularly at the tapered tips of the SELs where teat-shaped bubbles of loose BM form (Figure 5.3). This is only detectable by light microscopy if lamellar tissues are processed with PAS stain.

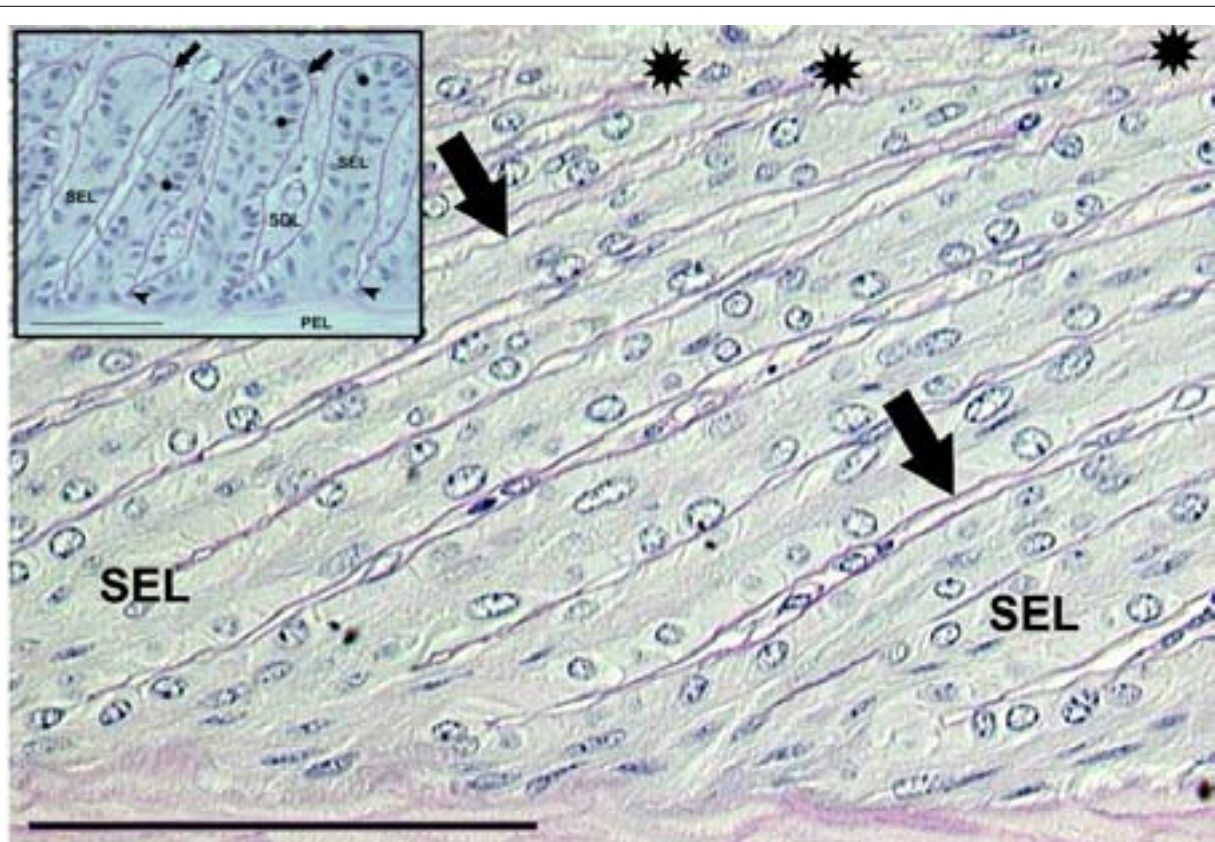

Figure 5-3 Grade 1 histological laminitis (PAS stain).

Micrograph showing hoof lamellar tissues stained to highlight the basement membrane. The basement membrane (arrowed) is stained dark magenta. At the now tapered tips of the secondary epidermal lamellae (SELs) the basement membrane has lifted away (stars) from the underlying basal cells. Between the SEL bases the BM is in its normal position, close to the primary epidermal lamella (PEL). Inset shows normal lamellae. PAS stain. Bar = 10 μm.

5.3.2 Grade 2 histological laminitis

With the BM no longer tethered to the basal cells, it slips further away with each cycle of weight bearing by the horse. The lamellar basement membrane begins to disappear initially at the bases of the SELs (**Figure 5.4**). The BM retracts from between the SELs and takes with it the connective tissue. The BM-free epidermal cells appear not to be undergoing necrosis or apoptosis, at least initially, and clump together to form amorphous, BM-free masses, on either side of the lamellar axis.

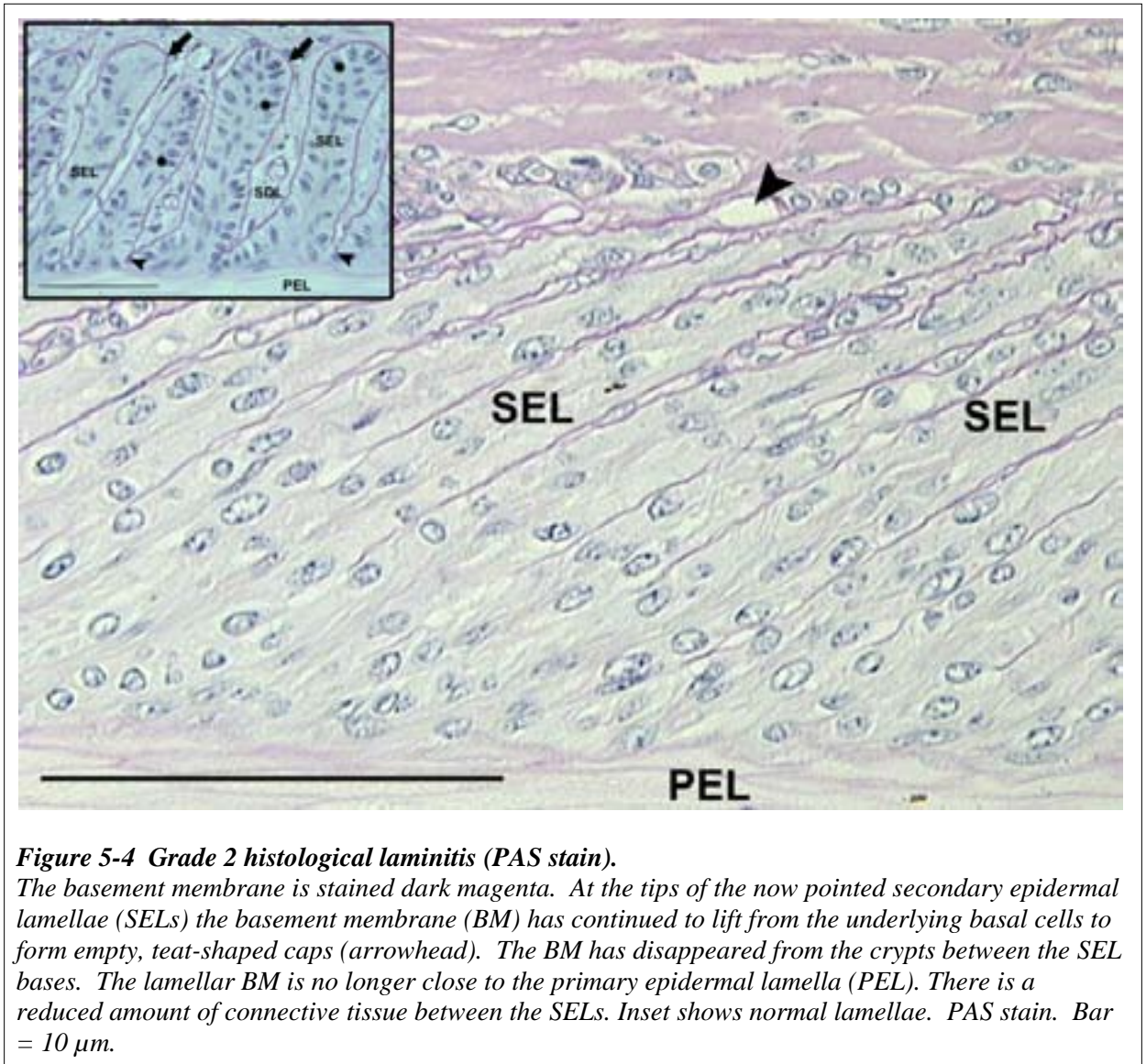


Figure 5-4 Grade 2 histological laminitis (PAS stain).

The basement membrane is stained dark magenta. At the tips of the now pointed secondary epidermal lamellae (SELs) the basement membrane (BM) has continued to lift from the underlying basal cells to form empty, teat-shaped caps (arrowhead). The BM has disappeared from the crypts between the SEL bases. The lamellar BM is no longer close to the primary epidermal lamella (PEL). There is a reduced amount of connective tissue between the SELs. Inset shows normal lamellae. PAS stain. Bar = 10 μm.

5.3.3 Grade 3 histological laminitis

In laminitis, the worse case scenario is a rapid and total BM separation from all the epidermal lamellae. Horses with grade 3 histological laminitis show severe clinical signs and are very lame. Sheets of BM peel away to form aggregations of loose, isolated BM in the connective tissue adjoining the lamellae. The epidermal lamellar cells are left as isolated columns with no connection whatsoever with the dermal connective tissue (**Figure 5.5**). The lamellar tips slide away from their basement membrane connective tissue attachments, at first microscopically, but as the degree of separation increases the distance between hoof and distal phalanx becomes measurable in millimetres (**Figure 5.6**). This is manifest clinically as the “sinker”, the worst possible situation for a horse with laminitis.

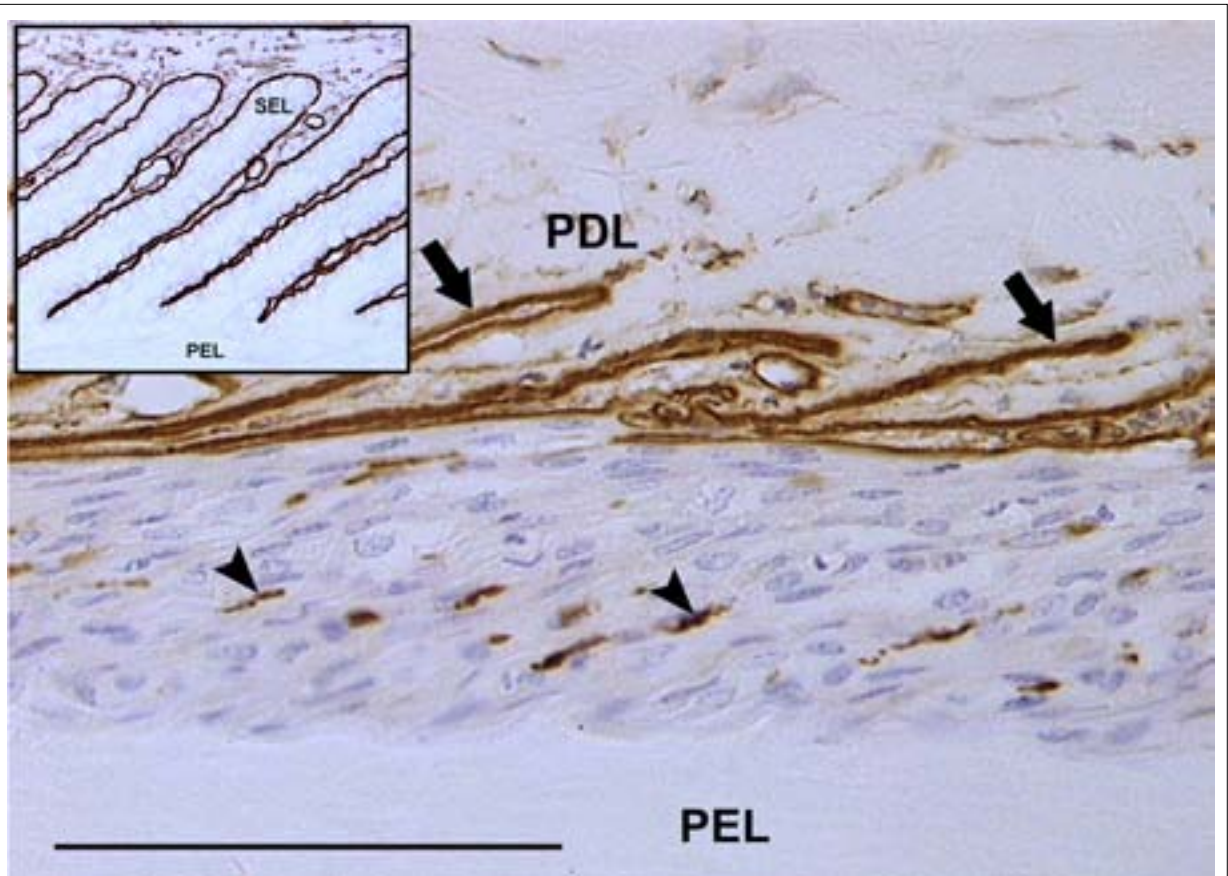


Figure 5-5 Grade 3 histological laminitis (immunostain).

Only remnants (arrowheads) of the basement membrane remain between the now disorganised secondary epidermal lamellae. Most of the lamellar epidermal cells have coalesced into an amorphous mass no longer effectively attached to any connective tissue. The remainder of the lamellar BM lies free, in strands (arrowed), among the connective tissue of the primary epidermal lamella (PDL). Type IV collagen immunostain. Inset shows normal lamellae. Bar = 10 μ m

Since the BM is the key structure bridging the epidermis of the hoof to the connective tissue of the distal phalanx, it follows that the wholesale loss and disorganization of the lamellar BM inexorably leads to the failure of hoof anatomy so characteristic of equine laminitis.

Loss of anchoring filament protein has been confirmed recently using immunohistochemistry. Preliminary results using antibody to laminin-5 (the major anchoring filament protein) show that laminin-5 is cleaved at the stage when the BM is lifting off the lamellar basal cells (French and Pollitt 2004a). Uncontrolled activation of lamellar MMP is the likely cause of the anchoring filament destruction.

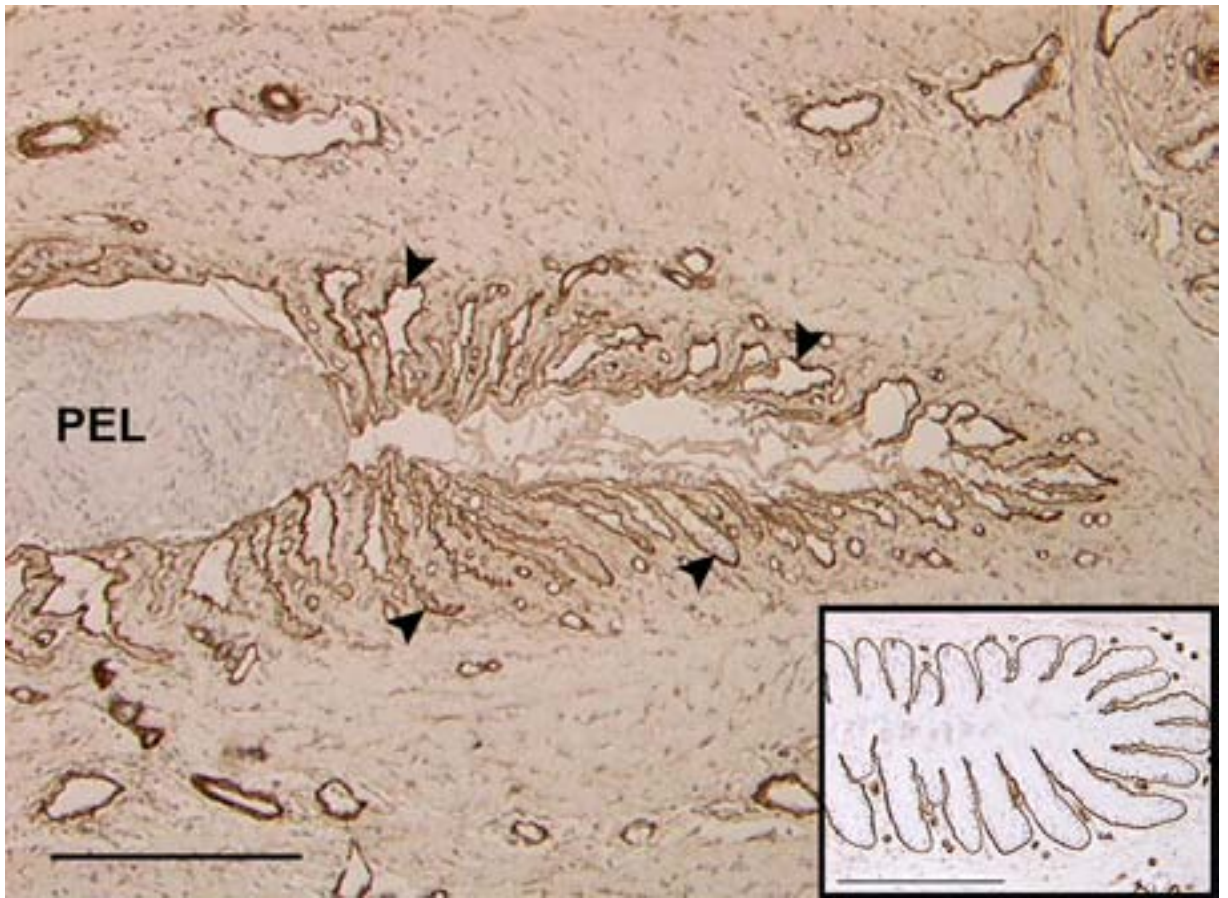


Figure 5-6 Grade 3 histological laminitis (immunostain).

The basement membrane of a lamellar tip is highlighted by type IV collagen immunostaining. The tip of the primary epidermal lamella (PEL) has completely detached from its basement membrane. The PEL basal cells are now an unattached, amorphous mass. Collapsed tubes of basement membrane, now empty of epidermal cells, are still attached to connective tissue (arrowheads). The PEL has already moved 0.03 mm from its dermal compartment and soon the distance will be measured, using a tape measure, on a radiograph. The inset shows a normal, immunostained lamellar tip. Type IV collagen immunostain. Bars = 100 μ m.

5.4 Lamellar blood vessels

Laminitis also affects the anatomy of lamellar capillaries. As the BM and the connective tissue between the SELs disappears so do the capillaries; they become obliterated, compressed against the edges of the primary dermal lamellae. Without capillaries in the lamellar circulation, blood bypasses the capillary bed through dilated arteriovenous shunts, and dramatically changes the nature of the foot circulation. A bounding pulse is detectable by finger palpation of the digital arteries. It also explains why the radioactive, capillary-sized particles (described in Chapter 4) bypassed the circulation at the beginning of the acute phase. The phenomenon of vascular shunting is now placed after the triggering of MMP production and occurs as a consequence of it.

5.5 Laminitis ultrastructure

Examination of laminitis tissues with the electron microscope confirms the existence of lysis and separation of the lamellar basement membrane (**Figure 5.7**). Importantly, the greater magnification shows widespread loss of basal cell hemidesmosomes (HDs) and contraction of the basal cell cytoskeleton away from the inner cell surface (French and Pollitt 2004b; Nourian *et al.* 2007). Electron microscopy shows why the BM separates from the feet of the basal cells. The anchoring filaments that bridge the gap between the hemidesmosome and the lamina densa of the BM are no longer present. When the numbers of HDs in the BM zone are counted there is a significant correlation between HD density and clinical severity of laminitis.

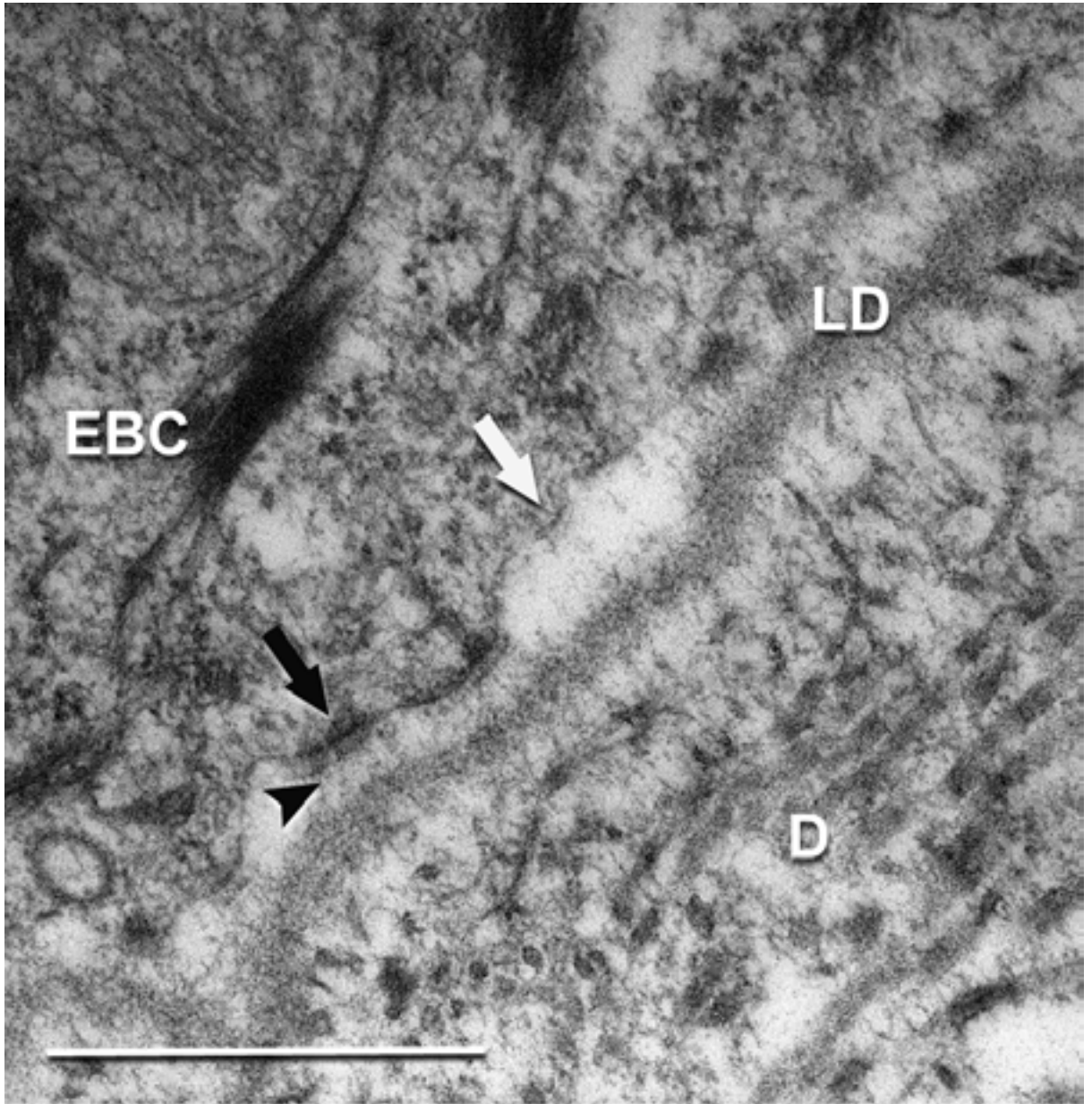


Figure 5-7 *Transmission electron micrograph of lamellar SEL at the onset of acute laminitis. Normal looking hemidesmosomes (dark arrow) still have anchoring filaments (arrowhead) attaching the lamellar epidermal basal cell (EBC) to the lamina densa (LD) of the basement membrane. As laminitis progresses hemidesmosomes fade and disappear (white arrow) and critically, anchoring filaments disconnect allowing BM separation to commence. Bar = 200 nm. D = dermis.*

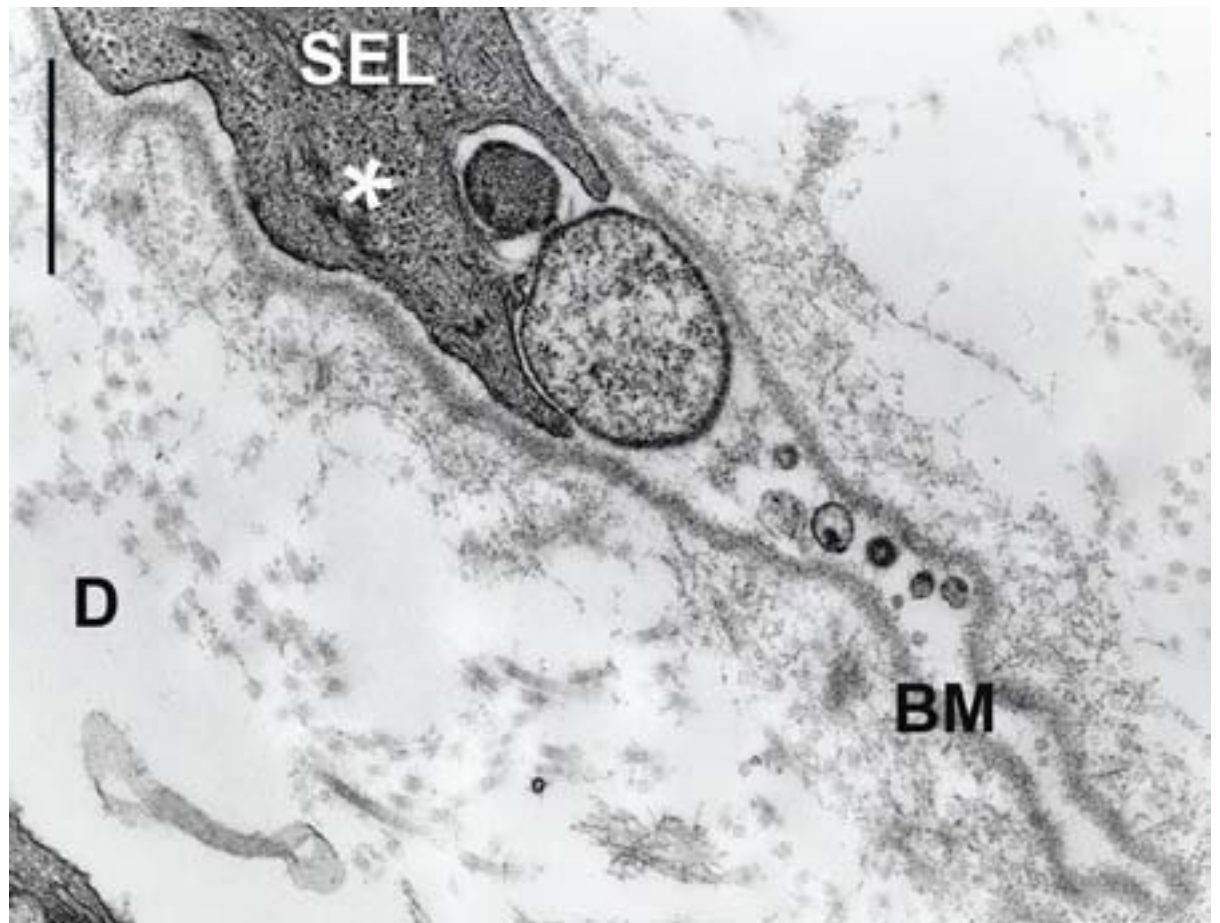

Figure 5-8 *Transmission electron micrograph of SEL tip at the onset of acute laminitis. The BM has separated from the attenuated, pointed SEL tip and formed a typical, empty BM enclosed bubble. There are few recognizable hemidesmosomes and only fragments of cytoskeleton (asterisk). Bar = 200 nm. D = dermis, SEL =secondary epidermal lamella.*

5.6 An enzymatic theory of laminitis

The enzymatic theory of laminitis, based on lamellar MMP activation, challenges the alternative view that laminitis develops because the flow of blood is impeded to cause ischaemic necrosis of epidermal lamellae (Kyaw-Tanner and Pollitt 2004). Furthermore epidermal cell necrosis, intravascular coagulation and oedema are not recognised in the AELRU laboratory in sections made from tissues in the early stages of laminitis (Croser and Pollitt 2006). The vessels in the primary dermal lamella, even the smallest, are predominantly open, without evidence of micro-vascular thrombi (blood clots). The gross anatomical appearance of freshly dissected laminitis tissue is one of dryness. Sometimes the lamellae just peel apart.

How do the trigger factors of laminitis reach the lamellae? There is now strong evidence, from three independent international laboratories, that the foot circulation during the developmental phase of laminitis is vasodilated. Laminitis does not occur if the foot is in a state of vasoconstriction during the developmental phase, suggesting that the trigger factors will only cause laminitis if they reach the lamellar tissues at a high enough concentration and over a long enough time period.

What are the trigger factors? Since the carbohydrate overload model of laminitis is characterised by endotoxin production it would seem a reasonable presumption that endotoxaemia should play a key role in initiating laminitis pathology. Tumour necrosis factor (TNF) along with other cytokines, such as interleukin, is expressed by mononuclear phagocytes within minutes of exposure to endotoxin. The

cytokine cascade originating from an inflamed leaky bowel is responsible for most of the pathological effects of endotoxaemia. However, laminitis has never been triggered by the experimental administration of endotoxin into the bloodstream or the peritoneal cavity and TNF is not increased; the actual trigger factors of laminitis remain unidentified. What appears certain in the light of recent research is that the lamellar disintegration of laminitis is mediated by the inappropriate release and activation of excess MMP. But what triggers MMP release and activation?

5.7 Laminitis *in vitro*

To answer this vital question it was necessary to develop an *in vitro* model for laminitis to enable us to study a range of putative trigger factors under controlled laboratory conditions. We were able to establish a test for separation of the dermal and epidermal lamellae using small explants of tissue taken from the inner hoof wall of normal, freshly killed, abattoir horses. After incubation for 48 h in tissue culture medium, in the presence of the laminitis trigger factor under investigation, each explant was subjected to tension. The force required to separate epidermal from dermal lamellae was recorded. When dermal-epidermal lamellar separation occurred readily (as occurs in field cases of laminitis) we considered the tissue to have developed *in vitro* laminitis. Lamellar explants can be cultured for up to 7 days in normal medium and no lamellar separation occurs. It is virtually impossible to separate normal lamellar explants. Normal explants resist a separating force of 900 grams. When a chemical known to activate metalloproteinases (we use a non-physiological MMP activator, the organo-mercurial compound, aminophenylmercuric acetate or APMA), was added to the explant tissue culture medium, the explants separated when only a small separating force was applied. In fact a dose-response curve between the force required to separate explants and the concentration of metalloproteinase activator, can be constructed.

All explant tissues were fixed in formalin and examined histologically for evidence of separation. Histological sections showed a clear zone of complete separation between the basement membrane and the basal cells of the epidermal lamellae (**Figure 5.9**). This is a characteristic of *in vitro* laminitis and resembles the basement membrane lesion of natural *in vivo* laminitis. The model has become a potent tool that enables our laboratory to screen a large number of potential, natural, laminitis trigger factors without having to perform experiments with live horses (Mungall *et al.* 2001). The presence or absence of MMP activation in the explant tissue culture medium was detected zymographically using gelatin polyacrylamide electrophoresis (**Figure 5.9**). Analysis of the culture medium from normal hoof explants shows that explants produce two MMPs (gelatinases) of molecular weight 92 and 72 kDa (Mungall and Pollitt 1999). A small amount of the active forms of the MMP-2 is also present in normal horses. Incubation of normal hoof explants with APMA results in the activation of MMP-9 and MMP-2.

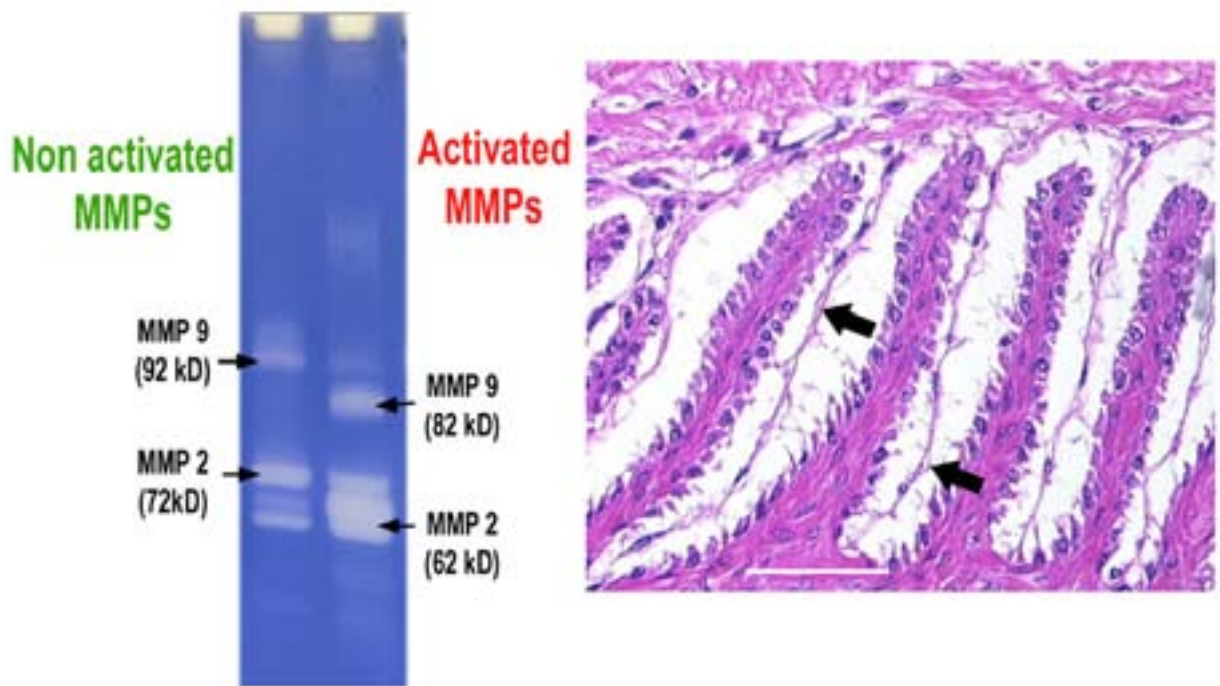


Figure 5-9 Zymography of normal lamellar explants.

The tissue culture fluid, in which explants were cultured, was applied to lanes in a polyacrylamide gel containing 0.1% gelatin (left). After electrophoresis and overnight incubation, the gel was stained for protein with Coomassie Blue G-250. Because the gel contains protein (the soluble collagen gelatin) the entire gel stains blue, except where gelatin has been digested by MMP activity. Thus the clear areas reveal the existence of MMP-9 and MMP-2 in lamellar hoof tissue. Proteins of known molecular weight (not shown) are electrophoresed at the same time to determine MMP molecular weights in kiloDaltons (kD). Lane 1 shows the MMPs contained in a normal explant. There is pro-MMP-9 but no active MMP-9, a large band of pro-MMP-2 and some active MMP-2. Lane 2 shows the effect of MMP activation with APMA. The pro-MMP-9 has been converted to active MMP-9 and a similar conversion of pro-MMP-2 has occurred. Cleavage of a 10 kD fragment from pro-MMP 9 and 2 activates the enzyme. The micrograph (right) shows a lamellar hoof explant after APMA activation of its constituent MMPs. The BM (arrows) of the secondary epidermal lamellae is no longer attached to the basal cells. Activation of lamellar MMPs causes this in vitro lesion that resembles natural laminitis. H&E stain. Bar = 10 μ m.

5.8 Laminitis and metalloproteinase enzyme activity

Lamellar explants from horses with acute laminitis, cultured in medium under the same conditions contained not only increased amounts of inactive MMP-2 and MMP-9, but large increases in the amounts of the MMPs in their activated form (**Figure 5.10**). This is proof that increased production of active MMP occurs in lamellar tissues affected by laminitis (Pollitt *et al.* 1998). This has been validated by similar findings by other laminitis researchers (Johnson *et al.* 1998). The filaments attaching lamellar basal cells to the basement membrane are MMP substrates and their enzymatic degradation leads directly to the failure of the attachment between hoof and distal phalanx.

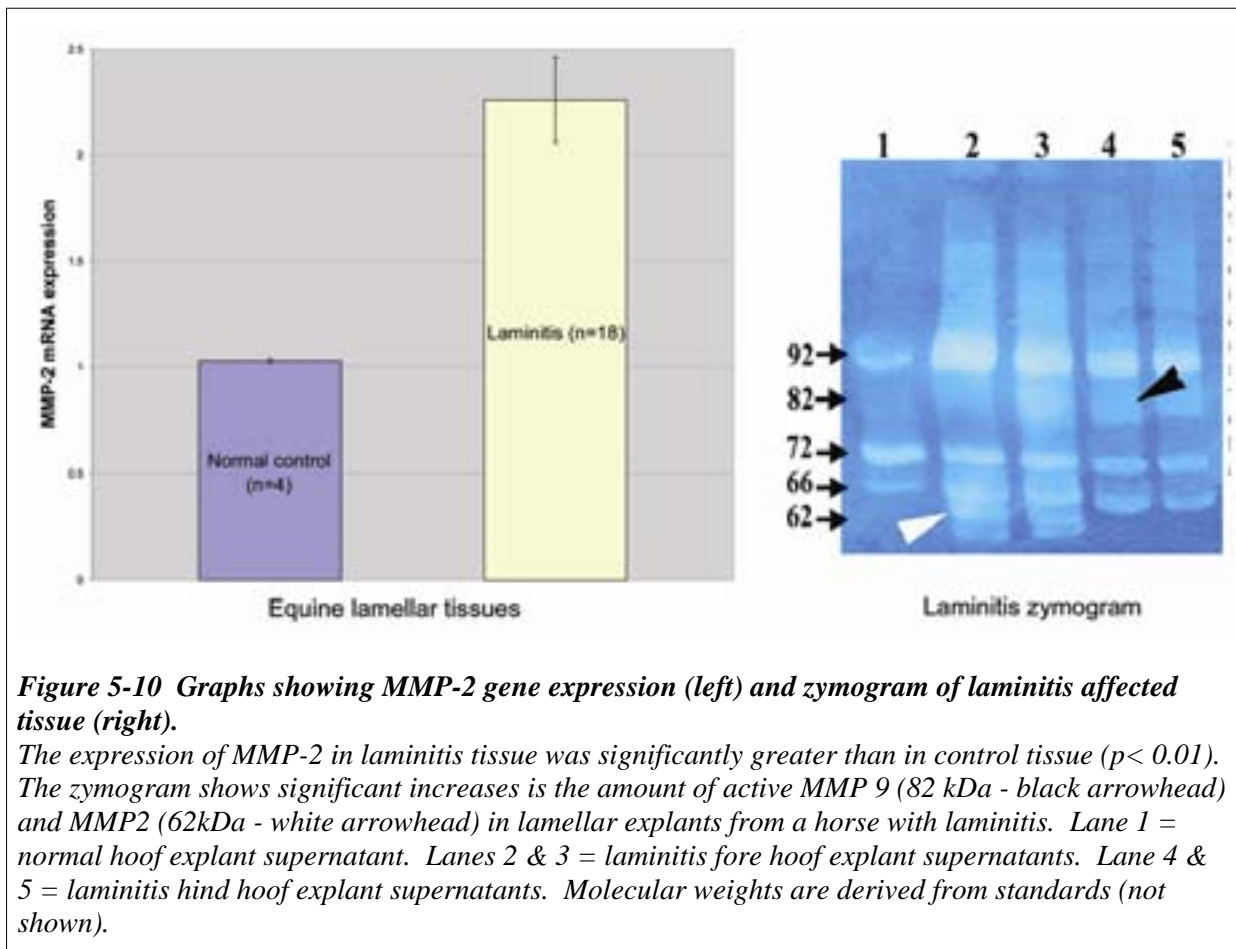


Figure 5-10 Graphs showing MMP-2 gene expression (left) and zymogram of laminitis affected tissue (right).

The expression of MMP-2 in laminitis tissue was significantly greater than in control tissue ($p < 0.01$). The zymogram shows significant increases in the amount of active MMP 9 (82 kDa - black arrowhead) and MMP2 (62kDa - white arrowhead) in lamellar explants from a horse with laminitis. Lane 1 = normal hoof explant supernatant. Lanes 2 & 3 = laminitis fore hoof explant supernatants. Lane 4 & 5 = laminitis hind hoof explant supernatants. Molecular weights are derived from standards (not shown).

5.9 Laminitis causes increased gene transcription of lamellar enzymes

Destruction and detachment of the lamellar basement membrane are the key lesions of acute laminitis. The genes controlling hoof lamellar MMP activity are significantly upregulated in tissues affected by acute laminitis, thus providing firm circumstantial evidence that MMP activation is a pivotal event in the development of laminitis (**Figure 5.10**). ADAMTS-4, an additional enzyme, capable of attacking other components of the lamellar BM zone, is also significantly upregulated by laminitis (Coyne *et al.* 2008).

5.10 Metalloproteinase inhibitors

The activity of tissue MMPs has recently been shown to correlate strongly with the degree of malignancy and invasiveness of lethal human tumours, such as malignant melanoma, breast and colon cancer. Degradation of the proteoglycan present within articular cartilage caused by ADAMTS-4 is a feature of osteoarthritis. Research in these fields has generated a wide range of chemical agents capable of inhibiting enzyme activity both *in vitro* and *in vivo*. We have shown that one of these (Batimastat or BB-94, British Biotech, Oxford) blocks the activity of the laminitis MMPs *in vitro* and has the potential to be a useful tool in the prevention and management of acute laminitis (Pollitt *et al.* 1998). We are conducting trials to test whether MMP inhibitors can prevent or ameliorate field cases of laminitis.

5.11 The search for natural laminitis trigger factors

We have used the *in vitro* laminitis explant model to investigate most of the proposed trigger factors of equine laminitis. Equine lamellae have tested resistant to virtually all known cytokines, tissue factors and prostaglandins. Gram negative bacterial endotoxin, extract of black walnut (*Juglans nigra*) and even anaerobic culture conditions fail to induce lamellar separation or significant MMP activation. There is one notable exception however. A factor present in the supernatant of cultures of *Streptococcus bovis* isolated from the equine caecum activates equine hoof MMP-2 and causes lamellar separation. During grain overload *S. bovis* is the principal microorganism responsible for the rapid fermentation of carbohydrate to lactic acid in the equine hindgut. In the presence of virtually unlimited substrate, its population explodes exponentially. We are currently investigating the role of the *S. bovis* MMP activator in natural cases of equine laminitis. If it crosses the mucosal barrier of the hindgut and enters the circulation it may be a “cause” of laminitis (at least in the carbohydrate overload model) that has escaped previous consideration.

5.12 Key Points

- A grading system for the histopathology of laminitis was developed based on the consistent pattern of histological changes to the secondary epidermal lamellae, basal cells and basement membrane that occur with the onset of laminitis. Grades 1-3 histological laminitis reflect increasing separation and lysis of the basement membrane, along with its connective tissue, from between the secondary epidermal lamellae.
- As the basement membrane and connective tissue retract, the capillaries of the lamellae are damaged, resulting in extensive changes to the circulation in the foot as blood bypasses the capillary bed through dilated arteriovenous shunts.
- An *in vitro* model for laminitis using hoof explants, followed by zymographic analysis of enzymes, showed that activation of MMP-2 and MMP-9, by laminitis or APMA, resulted in separation of epidermal and dermal lamellae. Increased gene transcription of MMP-2 and MMP-9 was present during laminitis.
- Histological examination of explants treated with APMA showed that the separation produced *in vitro* resembled the basement membrane lesion of laminitis *in vivo*.
- The presence of an MMP inhibitor, BB-94, blocked the activity of the MMPs *in vitro*.
- Factors present in the supernatant of cultures of *Streptococcus bovis* activated MMP-2 and caused lamellar separation.

6. Insulin and laminitis

6.1 Changes in insulin metabolism as a trigger for laminitis

All tissues need glucose (sugar) for energy, but most tissues can only take up glucose from the blood stream with the help of glucose transport proteins (GLUTs). There are a number of different GLUT proteins, including GLUT1, which is not affected by insulin. The GLUT4 proteins are switched on by insulin, and when they begin to fail the body makes more insulin to try to compensate. Insulin concentrations in the blood are a good diagnostic marker (or risk factor) for laminitis.

6.2 Equine metabolic syndrome

The term equine metabolic syndrome refers to horses with a history of laminitis, insulin resistance, cresty necks (**Figure 6.1**) and increased adipose tissue deposits in the withers and dorsal area of the back (Johnson 2002).



Figure 6-1 Chronically foundered pony showing the typical cresty neck of Equine Metabolic Syndrome. Photo: Don Walsh.

Elevated serum insulin concentrations distinguish ponies that are susceptible to dietary pasture associated laminitis (Treiber *et al.* 2006a; Treiber *et al.* 2006c). Furthermore, insulin concentrations are markedly elevated in ponies that develop laminitis after grazing high carbohydrate pasture, while glucose, free fatty acid and cortisol concentrations remain normal (Treiber *et al.* 2006b). In contrast to humans, insulin-resistant horses rarely develop pancreatic exhaustion and are capable of producing exceptionally high serum insulin concentrations (McGowan *et al.* 2004b; Reeves *et al.* 2001). Insulin toxicity appeared to be a key factor in triggering equine laminitis. The onset of laminitis is associated with plasma insulin that exceeds 100 $\mu\text{IU}/\text{ml}$ [normal range = 8 to 30 $\mu\text{IU}/\text{ml}$] (Walsh *et al.* 2007). To test the hypothesis that hyperinsulinaemia triggers laminitis normal, lean ponies, with no prior history of insulin resistance or laminitis, were subjected to prolonged hyperinsulinaemia and

euglycaemia. All of the ponies developed laminitis within 72h of hyperinsulinaemia (Asplin *et al.* 2007). This highlights the importance of insulin in the pathogenesis of endocrinopathic laminitis. Horses and ponies at risk of laminitis should be blood tested for the early detection of hyperinsulinaemia. Prior to sampling access to grain or other soluble carbohydrate must be prevented for 3 hours. A single blood sample showing elevated insulin predicts that laminitis will occur or may become worse (Walsh *et al.* 2007). Techniques should be employed to lower insulin concentrations and restore insulin sensitivity. A weight reducing diet with a low glycaemic index and physical exercise reduce insulin resistance in horses (Pratt *et al.* 2006). Further work is required to see if insulin-sensitising drugs of the type given to human patients with Type 2 diabetes will be effective in insulin resistant horses.

6.3 Equine Cushing's disease

Older ponies and horses sometimes develop a problem with their pituitary gland which is situated at the base of the brain. The gland enlarges and becomes dysfunctional, resulting in the development of Equine Cushing's Disease (ECD). The enlargement is sometimes described as a tumour (pituitary adenoma), but most are cases of pituitary hyperplasia (an increase in size for unexplainable reasons). The region of the pituitary involved is the *pars intermedia* giving the condition its common medical name; pars intermedia adenoma (PIA). The dysfunctional pituitary produces an excess of hormones and peptides that control other hormones. A sign that horses are affected by PIA is hirsutism; the hair coat grows unnaturally long and is not shed at the usual times (**Figure 6.2**).



Figure 6-2 Ponies with Equine Cushing's Disease fail to shed their hair coats (hirsutism).

A dysfunctional pituitary produces, in excessive amounts, hormones and peptides that control other hormones. The hormone imbalance also creates a tissue resistance to insulin and hyperinsulinaemia that disturbs hoof lamellar metabolism and causes chronic laminitis. Hirsutism is an additional sign that horses are affected by Equine Cushing's disease.

The hormone imbalance also creates insulin resistance that disturbs hoof metabolism promoting an insidious, relentlessly developing, chronic laminitis. Affected horses and ponies often have higher than normal concentrations of glucose, ACTH, cortisone and insulin in their blood. The levels of these substances varies throughout the day (diurnal or circadian rhythm) and care has to be taken with the interpretation of blood analysis. The clinical signs of ECD are pot belly and wasted top line, bulging supraorbital fat, polyuria and polydipsia, susceptibility to infections and laminitis. Insulin status is a powerful prognostic indicator in horses with equine ECD and insulin resistant animals with a basal serum insulin concentration of greater than 188 $\mu\text{IU/mL}$ are much more likely to develop

laminitis and survive less than 2 years after diagnosis, if they are also insulin-resistant (McGowan *et al.* 2004a). The laminitis developed by animals with Cushing's disease is usually refractory to treatment. However promising results have been obtained after the administration of pergolide mesylate (Permax), a drug registered for human use. Doses in the range of 1-2 mg/horse/day have been recommended. The drug mechanism is to reduce production, in the pituitary gland, of the hormone (ACTH) that controls cortisol production in the adrenal gland. With cortisol under control, insulin responsiveness in hoof lamellae returns and the laminitis stabilises. After treatment with Pergolide, the ACTH concentration of ECD horses decreases within one week (Walsh *et al.* 2007).

6.4 Hyperlipaemia

Further support for a relationship between changes in glucose metabolism and laminitis comes from observations on ponies and horses with hyperlipaemia. Hyperlipaemia is a state of negative energy balance occurring rapidly, and often precipitated by some form of stress. It has been suggested that the laminitis caused during hyperlipaemia is a result of vasoconstriction in the hoof as a consequence of the altered metabolism in the animal. An alternative explanation is that the metabolic changes leading to hyperlipaemia result in the hoof tissues being starved of glucose, thus precipitating the chain of events leading to triggering of MMP production and separation of the hoof lamellae, as occurs in cultured explants.

6.5 Supporting limb laminitis

Laminitis in the lamellae of a single hoof can occur whenever a horse's limb is forced to bear weight unilaterally for prolonged periods of time. This can occur when an injury (bone or joint fracture) or disease process (septic arthritis) in the contralateral limb is so painful that weight bearing is impossible. After 2-3 days of unrelieved weight bearing, the supporting limb develops lamellar pathology, often to a severe degree. The case for ischaemia as the cause of supporting limb laminitis appears to be clear cut. The evidence comes from *in vitro* studies using digitised subtraction angiography (DSA) in isolated perfused horse limbs (obtained after humane slaughter at a knackery). When a mechanical press was used, to place the limb in the loaded, (fetlock fully extended) position, there was zero perfusion of the foot below the level of the coronary band. When the limb was not loaded perfusion through all the major vessels of the foot was normal. Presumably a similar situation prevails *in vivo* and chronic lack of perfusion eventually triggers a lamellar pathology indistinguishable from that initiated by other causes. This form of laminitis may be prevented if the supporting limb is firmly wrapped in an elastic support bandage and shod with an effective support shoe. The horse should be provided with a deep bed of wood shavings or sand so that it can lie down comfortably and allow blood to circulate through its feet. Deep, compliant bedding also allows the horse to find a foot position that promotes the circulation. The injured limb should be treated promptly and fitted with a cast or splint so that it can begin to take its share of weight bearing. Pain should be controlled with analgesics for the same reason.

6.6 Key Points

- Horses and ponies affected by Equine Metabolic Syndrome are often obese, have cresty necks and increased adipose tissue deposits in the withers and dorsal area of the back.
- Plasma insulin concentrations above 100 μ IU/ml indicate insulin resistance (hyperinsulinaemia) and a high risk of laminitis.
- Insulin alone, when administered in excess to normal ponies, causes laminitis.
- Equine Cushing's Disease also involves tissue resistance to insulin and hyperinsulinaemia that alters glucose uptake in hoof lamellae and results in chronic laminitis.
- Hyperlipaemia also causes laminitis, perhaps because of the hyperinsulinaemia associated with it.
- Supporting limb laminitis, in the lamellae of a single hoof, can occur whenever one leg is required to bear weight unilaterally for extended periods of time. Preventative treatment should be used to avert the development of laminitis in the weight-bearing foot.

7. The Clinical Signs of Laminitis

7.1 Acute laminitis

Shifting weight from one foot to the other (paddling) is the first clinical sign that lamellar degeneration is occurring (Obel grade I laminitis) and usually occurs in the forefeet (**Figure 7.1**). Occasionally, the shifting weight sign appears in just the hind feet. Careful observation may reveal that one foot, already with more severe lamellar pathology, is being lifted more frequently, and for longer, than the contralateral foot. It is worth spending some time quietly observing sick horses for the first appearance of paddling as early institution of treatment can do much to halt the progression of further lamellar damage.



Figure 7-1 Laminitis stance: forefeet.

Laminitis usually affects the forefeet more severely than the hind; presumably because the forequarters carry a greater proportion of the horse's weight (about 65%). Often the hind feet appear to be spared completely. In the chronic laminitis case pictured, the mare is shifting weight from one forefoot to the other (the right limb is flexed and off the ground). Horses with chronic laminitis shift weight like this for months, sometimes years.

The hooves of horses developing laminitis after carbohydrate overload (and possibly laminitis associated with other toxic/ septic shock syndromes) are palpably warm. If the ambient temperature is cool, hoof temperature can be measured using a thermographic camera or a hand-held infrared temperature scanner. Hoof temperatures of 30⁰ C for more than 24 hours during the developmental phase usually indicates impending laminitis. Unfortunately, if the ambient temperature is above 30⁰ C measuring hoof temperature becomes difficult to interpret. Bounding, exaggerated pulses in the digital

arteries over the fetlock are invariably present, but may be difficult to palpate if there is much subcutaneous oedema of the distal limbs. Sometimes pulsation in the digital arteries is so pronounced it is visible to the naked eye. A bounding digital pulse is not specific (pathognomonic) for laminitis, however, and occurs after strenuous exercise and in association with a number of other foot conditions, such as sole abscessation and fractures of the distal phalanx. Thumb or hoof tester pressure over the sole at the toe usually elicits a pain response, but not always, so a negative response should not be used to rule out a diagnosis of laminitis. Lameness during the walk or trot may be obvious only when the horse turns sharply. An abaxial sesamoid nerve block abolishes the foot pain of laminitis.

Although laminitis pathology appears to weaken the lamellar attachments of all the feet, more severe lesions usually develop initially in the forefeet. This is because the forequarters support a greater proportion (around 65%) of the horse's weight and the mechanics of foot break-over put greater strain on the toes of the forefeet. Similar logic dictates that if the horse is forced to walk or is nerve blocked and made to walk, loading and locomotory forces cause the lesions to worsen in the lamellae of the dorsal hoof wall of the forefeet.

Horses that develop more extensive lamellar pathology will exhibit more obvious clinical signs (Obel grade 2 laminitis). They may tremble and sweat and appear distressed. The heart and respiratory rates may be increased. They can be mistakenly diagnosed as suffering from "tying-up" (rhabdomyolysis), pneumonia or even a broken pelvis. Severely affected horses may refuse to pick up a forefoot or a hindfoot because full weight bearing on the contralateral foot causes extreme pain (Obel grade 3). When standing still, the forefeet will be placed forward of the normal position so that the heels are loaded more than the toes (**Figure 7.2**). If forced to walk the horse will arch its back and place the hindlimbs forward, under the abdomen, to shift as much weight as possible to the hindquarters. The horse half rears before stepping forward in front. The posterior phase of the forelimb stride is kept short to minimize the painful downward rotating force of the deep flexor tendon on the distal phalanx.



Figure 7-2 *The laminitis gait.*

The forefeet are placed forward of the normal position so that the heels are loaded more than the toes. When walking is attempted, the horse will arch its back and place the hindlimbs forward, under the abdomen, to shift as much weight as possible to the hindquarters.

When the hind feet are more severely affected than the fore, the order of the laminitis stance is reversed. The forelimbs are placed back under the abdomen and the horse leans over its forequarters, lowering its head and neck as a cantilever, to relieve the hind feet of weight bearing. Weight will be shifted from one hind foot to the other. With severe lamellar failure in all four feet, horses are immobile and extremely distressed. They frequently lie in lateral recumbency with all limbs extended.

7.2 Early chronic laminitis

The internal, anatomical disintegration of the hoof, which accompanies the acute laminitis episode, is initially invisible to the naked eye. With the passage of time however the hoof begins to display the effects wrought upon it by the pathology of the acute phase. If the initial lamellar pathology is mild the clinical signs of laminitis may abate as the distal phalanx lamellar attachment apparatus repairs. Horses recovering from even the mildest laminitis should be rested and observed closely. If no or negligible radiographic evidence of palmar displacement of the distal phalanx within the hoof capsule exists, and the digital pulse is not palpably exaggerated 48 hours after treatment has ceased, the horse can be cautiously returned to its usual function. However if lameness persists and worsens and the digital pulse remains prominent this means that there is on-going pathology accompanying displacement of the distal phalanx within the hoof capsule. This process of increasing chronicity after the crash needs to be understood to if we are to care for foundered horses effectively.

7.2.1 Coronary band changes

When the majority of the lamellar attachments fail, as they do in severe cases (sinkers), the distal phalanx descends deeply into the hoof capsule, taking with it the attached coronary band connective tissue. This creates a deficit in the coronary band and the sharp edge of the proximal hoof wall becomes palpable with a finger. Initially the deficit may be palpable only dorsally (the front of the foot), over the extensor process of the distal phalanx. If it extends around the coronet to the quarters and heels, the prognosis is grave as this is an indication that most of lamellar attachment apparatus is destroyed. Sometimes the skin may separate at the hair-line of the coronet and exude serum (Figure 7.3).

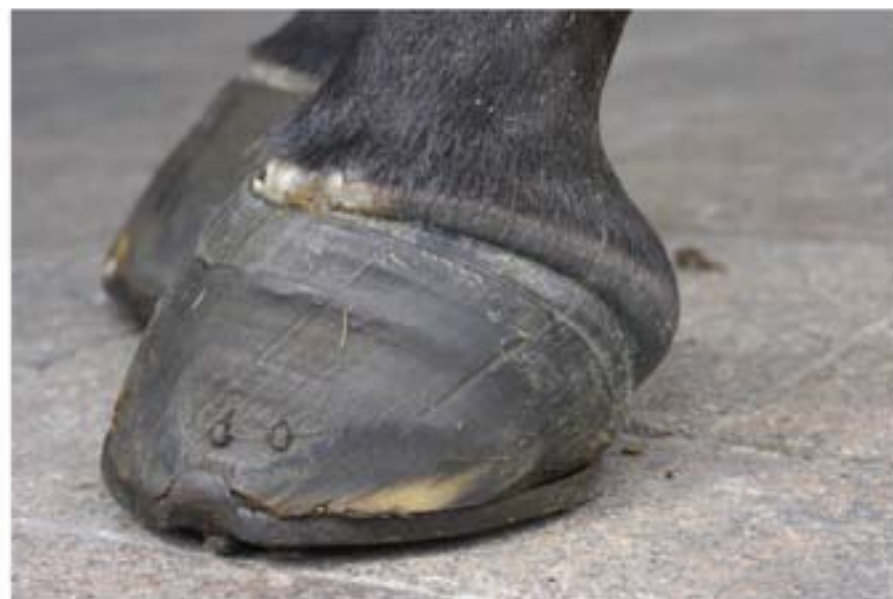

Figure 7-3 Coronary band changes due to severe chronic laminitis.

The front feet of a mare 3 months after post-foaling retained placenta and metritis. The dorsal, proximal hoof wall is deformed. The coronet is exuding serum at the hair line.

7.2.2 Sole changes

Within a few days of the acute episode, a convex bulge in the sole (the so-called dropped sole) may appear beneath the descending distal phalanx. Initially, fine cracks appear over the bulge in the sole and in severe, deteriorating cases the resultant pressure necrosis causes the corium beneath the distal phalanx to prolapse completely through the horny sole (**Figure 7.4**).

In less severe cases, where descent of the distal phalanx has been slight, the sole may lose its normal concave appearance and be flat. Careful shaving of the sole, with a sharp hoof knife, may reveal a red, crescent-shaped bruise. This is evidence of trauma from within, inflicted on the sole by the descending margin of the distal phalanx which is also crescent shaped. Haemorrhage from blood vessels in the solar corium, crushed under the distal margin of the bone, releases haemoglobin that stains the horny sole. The red stain appears at the ground surface of the sole after a period of sole growth. Bilateral, crescent-shaped bruising of the sole must not be dismissed as “stone bruising”.

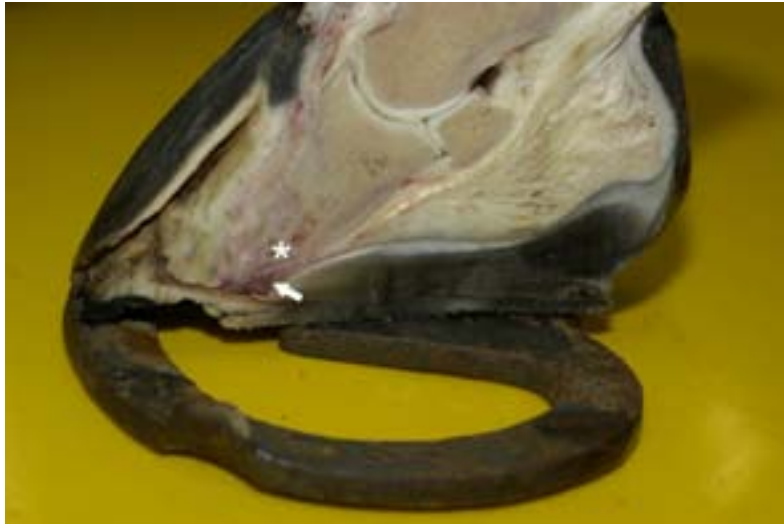

Figure 7-4 *Sagittal section of the foot of the mare in Figure 7.3.*

There is extensive internal damage due to on-going chronic laminitis. The sole has bulged downward and the sole corium (arrowed) over the tip of the distal phalanx has prolapsed through the perforated the sole. The dorsal surface of the distal phalanx (asterix) is extensively remodelled.

7.2.3 Hoof wall changes

After the acute episode of laminitis and the consequent shift in the position of the distal phalanx within the hoof capsule, the horse is left with a legacy of deformed hoof growth. Dorsal hoof wall growth is retarded, while growth at the heels usually proceeds at the normal rate. In the normal hoof, minor fluctuations in growth rate produce in the wall a series of concentric rings, parallel to the coronet, clearly visible on the surface of the hoof. In a hoof affected by chronic laminitis the growth rings are no longer parallel; they converge at the toe where growth is deformed. In severe cases, the divergent growth between toe and heel produces a dramatic upturning of the toe and the hooves take on the appearance described as “Aladdin’s slippers” (Figure 7.5). If neglected, toes affected by chronic laminitis can become unnaturally long and make locomotion for the foundered horse or pony extremely difficult.




Figure 7-5 *Chronically foundered pony with “Aladdin’s slipper” feet.*

During the acute phase, when the lamellar attachment apparatus fails, the descending distal phalanx takes with it the soft, not yet keratinised, proximal hoof wall and the dermal papillae of the coronary groove. The normally straight hoof tubules and papillae become kinked, but the basal cells of the coronary epidermis continue to elaborate hoof wall, but now in an abnormal, inward (no longer downward) direction. After the acute episode the coronet usually recovers to some extent and produces hoof tubules with a more correct orientation. However, the kinked tubules remain in the hoof wall until they grow out at the ground surface. Kinked hoof wall tubules can be seen in sections of chronically foundered feet post mortem (Figure 7.6). A groove in the hoof wall, corresponding to the zone of kinked tubules, is visible on the surface of the hoof wall. The depth of the groove gives some indication of the severity of the acute episode.

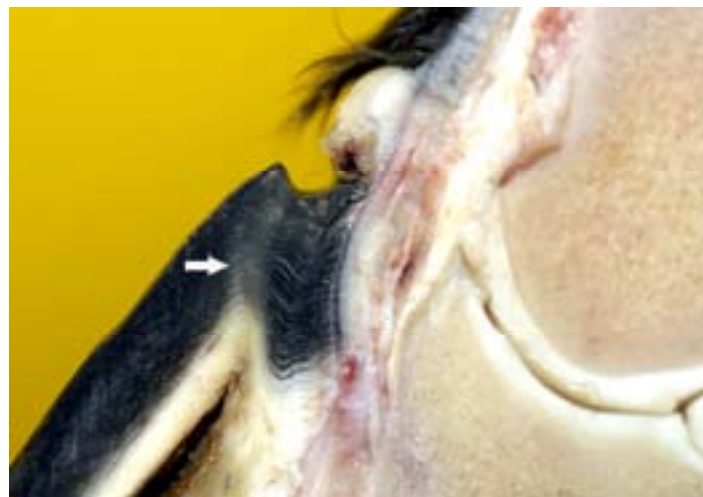

Figure 7-6 Kinked, displaced, hoof wall tubules due to severe chronic laminitis. Prior to the development of laminitis the hoof wall tubules were straight and parallel. When laminitis occurred the distal phalanx descended into the hoof capsule taking with it coronary papillae and the soft, unkeratinised, proximal hoof wall. Hoof wall growth from that point on (arrowed) has been deformed and, trapped below the level of the old straight hoof wall, growing inwards towards the extensor process. The foot is also shown Figures 7.3 and 7.4.

7.2.4 Hoof wall lamellar changes.

Ultimately it is the strength of the lamellar interface that determines prognosis. Many horses relapse after the initial laminitis episode despite early signs of improvement and we need better strategies for managing laminitis affected feet. Thus we studied laminitis affected tissue 7 days after the initiating episode to assess the healing response to the disease (van Eps and Pollitt; submitted Equine vet.J 2007).

Surprisingly, 7 days after laminitis, the destructive enzymatic processes that caused lamellar basement membrane (BM) dysadhesion and lysis, basal cell dislocation and lamellar attenuation had abated. All epidermal compartments were enveloped in normal appearing BM and the majority of epidermal basal cells were of normal shape and orientation. The major abnormality was the spectacular change in lamellar architecture. Lamellar anatomy was in disarray. The rows of organised, symmetrical hoof wall lamellae that characterize normal lamellae had been replaced with epidermal strands and pearl shaped islands, many no longer connected to their respective primary hoof wall lamellae. The lamellae had clearly lost their capacity to function as an attachment apparatus between hoof wall and bone. Premature resumption of athletic exercise and thus greater load and foot break-over strain, particularly in the fore feet, could rupture surviving but weak lamellar attachments. This is the likely one of mechanism behind the notorious exacerbations that plague horses apparently recovered from a primary bout of laminitis.

The lamellae that are stretched and elongated (Figure 7.7) allow the distal phalanx to sink into the hoof capsule. Initially this results in a small but significant increase in distance, measurable on radiographs, between the outer hoof wall and the upper surface of the distal phalanx. This emphasises the importance of good quality radiographs to assess the severity of the initial laminitis insult. Even a small increase in the distance between the hoof wall and the distal phalanx should indicate to the practitioner that histopathological changes have occurred. Early radiographs can be used as a yardstick against which to measure any subsequent exacerbation.

The empty compartments of dislocated BM, so obvious in the acute stages of acute laminitis (Pollitt 1996) are colonised by surviving epidermal cells and produce spheres and discs of isolated epidermal SEL remnants. The outright lysis of lamellar BM that occurs adjacent to the PEL (Pollitt & Daradka 1998) is the reason why the islands of epidermal tissue become stranded in the lamellar dermis. Laminitis, observed 7 days after induction, reduces the surface area of the lamellar attachment apparatus and weakens it.

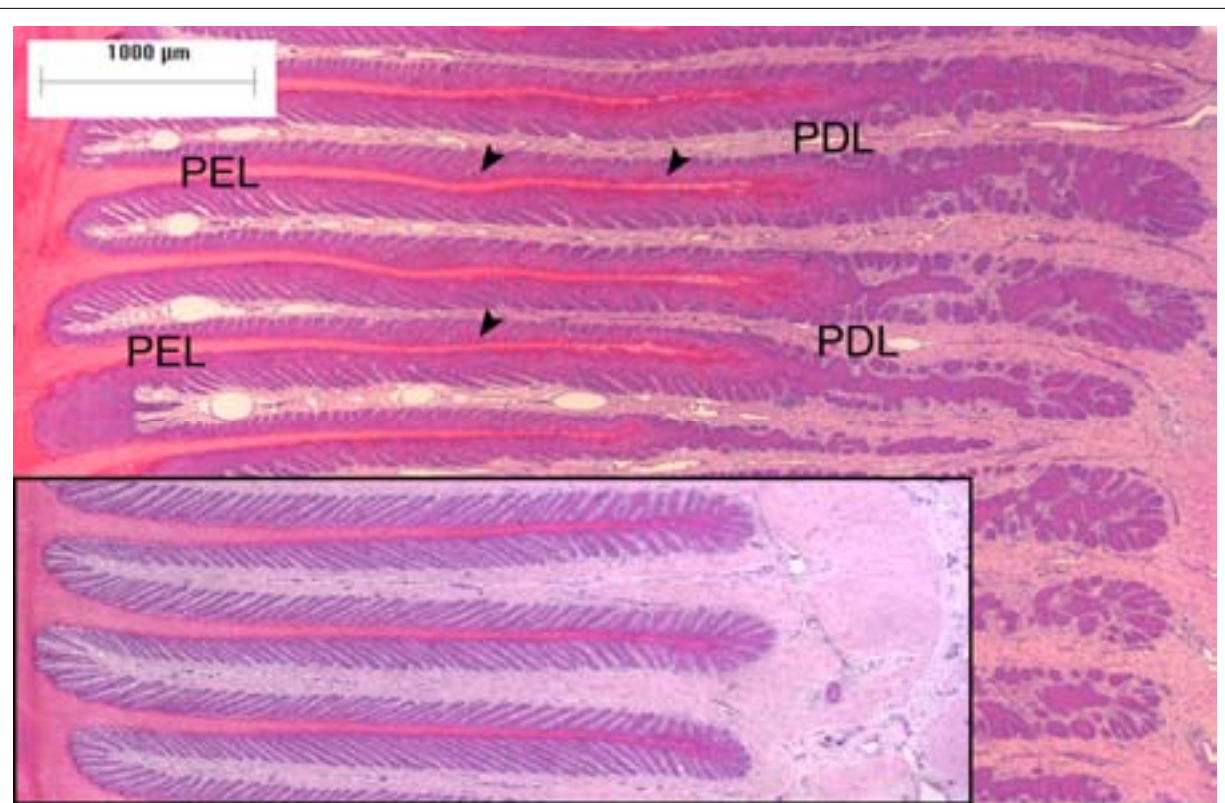


Figure 7-7 Photomicrograph of left fore hoof lamellae 7 days after laminitis induction. The primary epidermal lamellae (PELs) affected by laminitis are longer than normal (the inset photomicrograph, at the same magnification, shows lamellae from a normal control horse). The keratinised axis of the PELs is relatively unaffected but on either side of it are abnormal columns of partially keratinised epidermal cells (arrowheads). Figure from van Eps and Pollitt 2007 (submitted *Equine vet. J.*)

The formation of a lamellar wedge is often described as a hallmark of chronic laminitis but there was no sign that one was forming at the 7 day stage of the disease. Presumably the wedge and palmar rotation of the distal phalanx occur much later, as a consequence of unstable lamellar attachments and chronic changes in tubular hoof wall growth.

7.3 Severe chronic laminitis

When large scale failure of lamellar attachments occurs the distal phalanx descends and drags with it the growth zone of the proximal hoof wall. The growth zone continues proliferation of new hoof wall but now in a kinked pattern. In severe chronic laminitis the growth zone sinks below the pre-laminitis hoof wall and in this trapped situation produces hoof wall that grows inwards. The in-growing coronet of chronic laminitis feet compresses the coronary cushion (Fig 7.8) and exerts unrelenting pressure on the coronary vasculature that is probably pathological.

Severe cases of chronic laminitis develop venogram filling deficits and this why venography is valuable; it detects pathology that would otherwise escape treatment. Although insignificant initially, the filling deficits become more complete as the weeks go by. After 7 weeks there are usually prominent deficits in the coronary band and toe venous circulations (Figure 7.8).

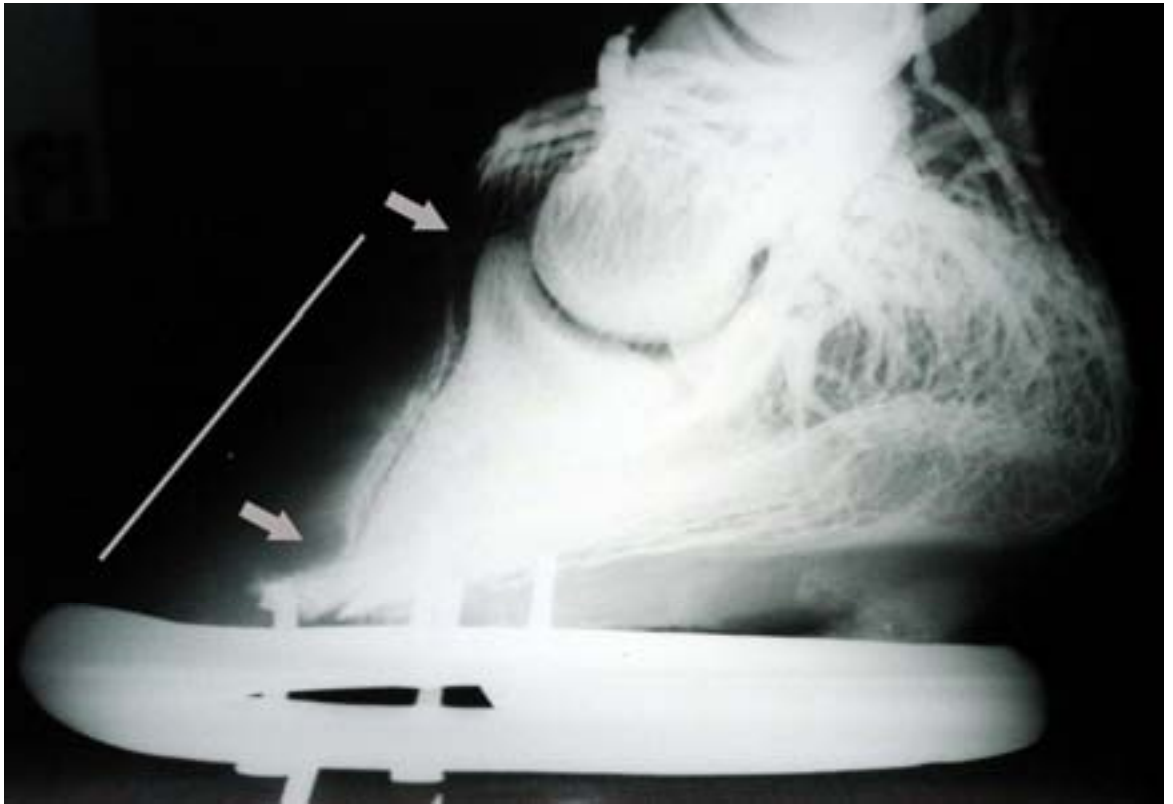

Figure 7-8 Venogram of foot with severe chronic laminitis: Case study “Grace”.

The hoof distal phalanx distance is 32 mm and there are venous filling deficits at the coronet and toe (arrowed).

Histological studies show the reason for the venous filling deficits. The veins in the region of the deficits are compressed, as if squeezed shut (Figure 7.9) suggesting that contrast medium is absent in venograms because veins are physically unable to fill. The neighbouring arteries appear unaffected.

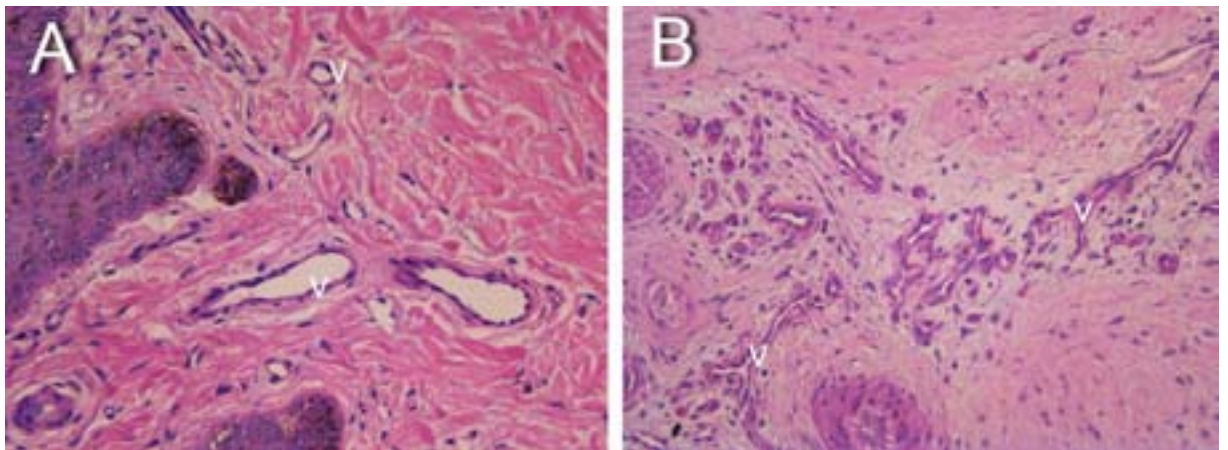


Figure 7-9 Histology of normal coronary band veins (A) and veins affected by severe chronic laminitis (B).

With chronic laminitis the veins (v) are compressed and flat. Same horse as in Fig 7.8 case study “Grace”.

Arteriograms of feet with prominent venographaphic deficits are relatively normal suggesting that in the cases we have studied so far the circulatory changes are mainly confined to the venous side of the circulation. Paired venograms vs arteriograms of the front feet of the case study horse “Grace” that had severe chronic laminitis show the remarkable difference between arteries and veins (**Figure 7.10**).

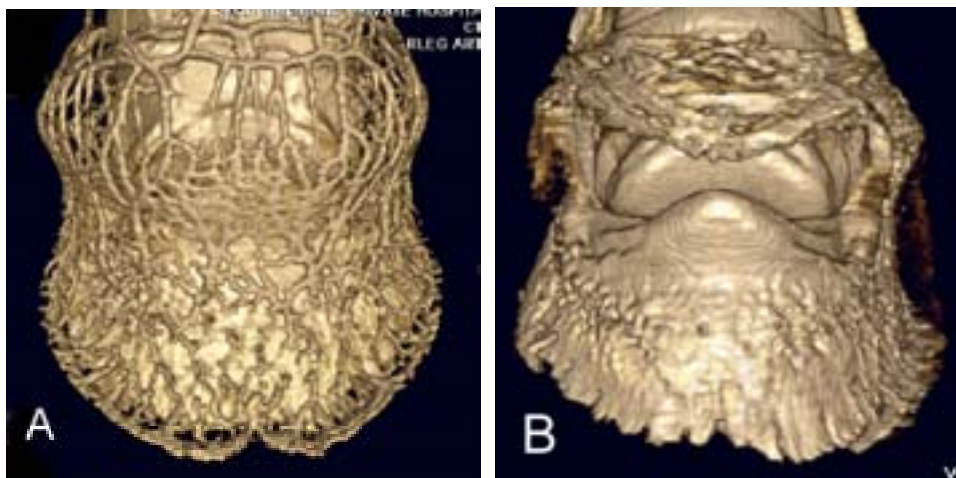


Figure 7-10 *Computed tomography (CT) arteriograms vs. venograms of the front feet of a horse (Case study “Grace”) with severe chronic laminitis.*

Arterial infusion of the right foot (A) with barium sulphate shows that despite a pre-existing dorsal venographic deficit the arteries are relatively unaffected. However venous infusion of the left foot (B) with barium sulphate shows the absence of venous filling of the dorsal half of the foot.

We have profiled the coronary cushions of a large number of chronic laminitis feet to understand the sequence of events that lead to incurable demolition of foot architecture. The coronary cushion is defined as the space between the proximal hoof wall and the extensor process of the distal phalanx. When sectioned in the sagittal plane, feet with normal venograms, have coronary cushions with broad, triangular profiles and hoof tubules that are straight and parallel (Figure 7.11A). Feet affected by chronic laminitis however have flattened, compressed coronary profiles, kinked hoof wall tubules and growth zones that are below the level of the pre-laminitis wall (Figure 7.11B).

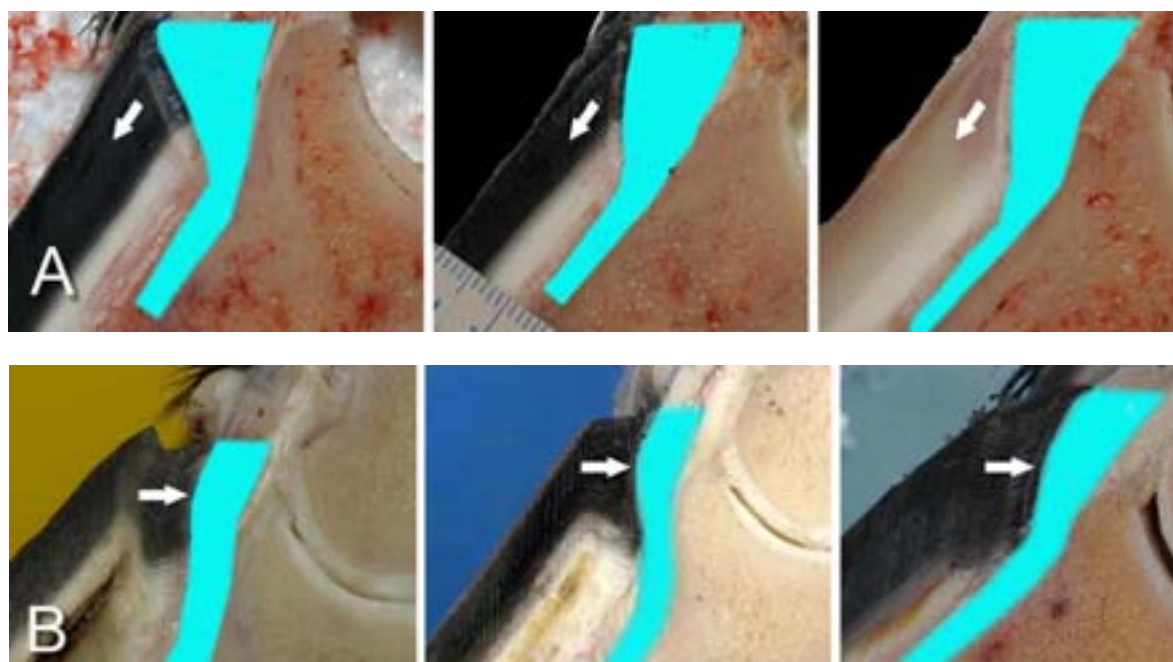


Figure 7-11 *The coronary cushions of normal vs. chronic laminitis feet.*

Coronary cushion of normal feet (row A): the profiles are triangular in shape and hoof tubules are straight and parallel. Hoof wall growth is normal and in the direction of the arrows. Coronary cushion of chronic laminitis feet (B): The profiles are reduced in size because the proximal hoof wall is growing inwards (in the direction of the arrows) and compressing the coronary cushion and the veins within it.

Similar events occur at the toe. When the distal tip of the distal phalanx descends into the hoof capsule it not only crushes the sole corium but drags downwards the tubular growth zones of the toe. As with the coronet this growth zone continues to proliferate but instead of the normal downwards direction (Figure 7.12A) it grows inwards towards the tip of the distal phalanx. Compared to the dorsal coronet the pathological changes of the toe are more obvious and more serious. Not only are veins compressed, as shown by the venogram, the pressure is sufficient to lyse (destroy) much of the distal third phalanx (Figure 7.12B and Figure 7.14) and probably contributes to rotation of the distal phalanx.

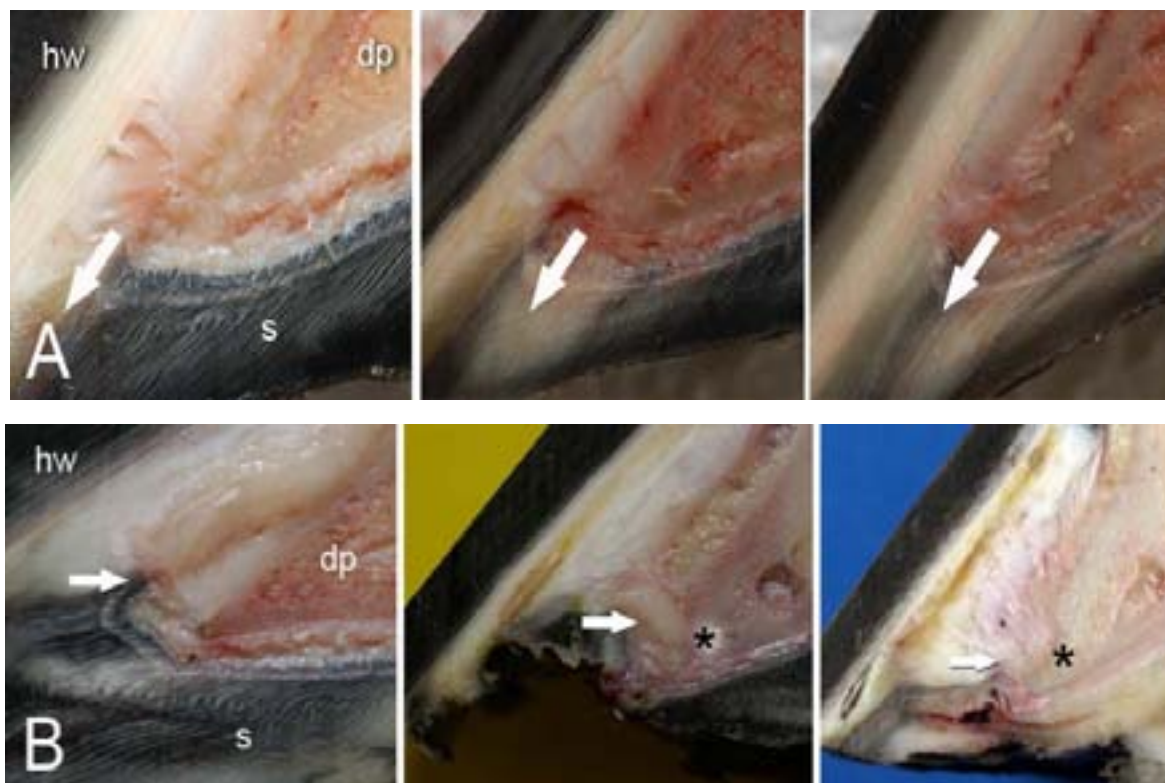


Figure 7-12 Normal (A) compared to severe, chronic laminitis (B) toe and terminal wall tubules.

Normal tubules are straight, parallel and growing downwards in the direction of the arrow.

Terminal wall and sole tubules of feet with severe, chronic laminitis are displaced and growing inwards, towards the distal phalanx, in the direction of the arrow. The unremitting pressure of the inward growing hoof causes lysis of the distal phalanx (asterix). Hoof wall = hw, distal phalanx = dp, sole = s.

The band of displaced hard, inward growing terminal wall and sole tubules encircles the distal third phalanx and applies pressure to everything in its path. Soft tissue, nerves and blood vessels are severely compressed and damaged (Figure 7.13).

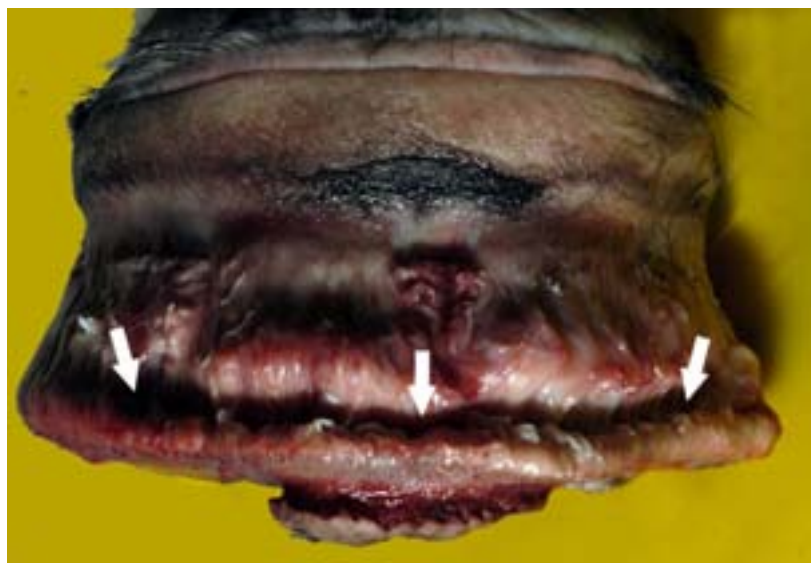

Figure 7-13 *The foot of a chronically foundered horse with the hoof removed. The in-growing toe and terminal wall has severely compressed a band (arrowed) of lamellar corium that extends across the dorsal half of the foot.*

There is extensive remodeling of the bone of the distal phalanx (Figure 7.14) and lysis of this magnitude is undoubtedly painful and must contribute to the obvious lameness of chronically foundered horses. The inexorable rotation of the distal phalanx may be due to the inward growing hoof tubules slowly pushing the tip of the bone backwards and downwards. This is contrary to the widely held belief that it is the pull of the deep flexor tendon that causes distal phalanx rotation. Rotation of the distal phalanx is not an acute phenomenon and its appearance does not correlate to when the dorsal hoof lamellae are at their weakest; the acute phase. Instead distal phalanx rotation first appears around six weeks after laminitis development, just when displaced, inward growing terminal wall and sole tubules reach the distal margin of the third phalanx. If left unchecked the inward growing hoof of the proximal and distal hoof wall progressively destroys foot architecture eventually leading to incurable pathology.

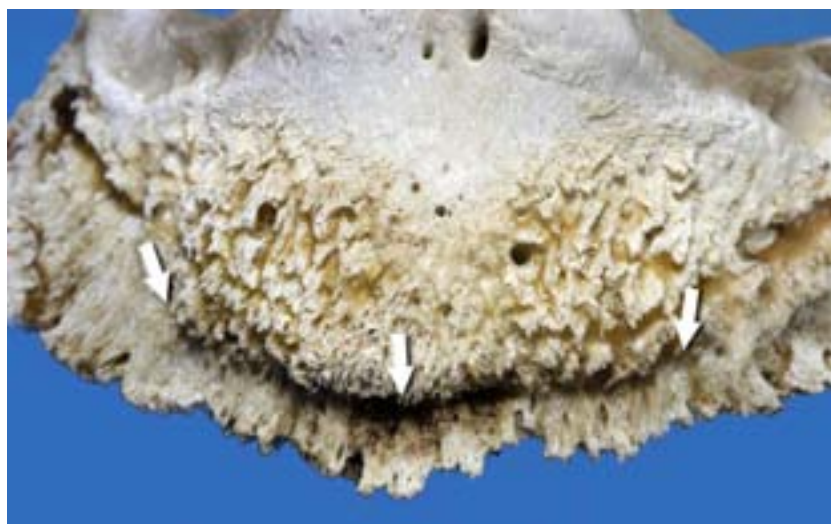

Figure 7-14 *The distal phalanx of the same chronically foundered horse in Figure 7.13. The band of in-growing toe and terminal wall has caused extensive lysis of the distal margin of the bone (arrowed).*

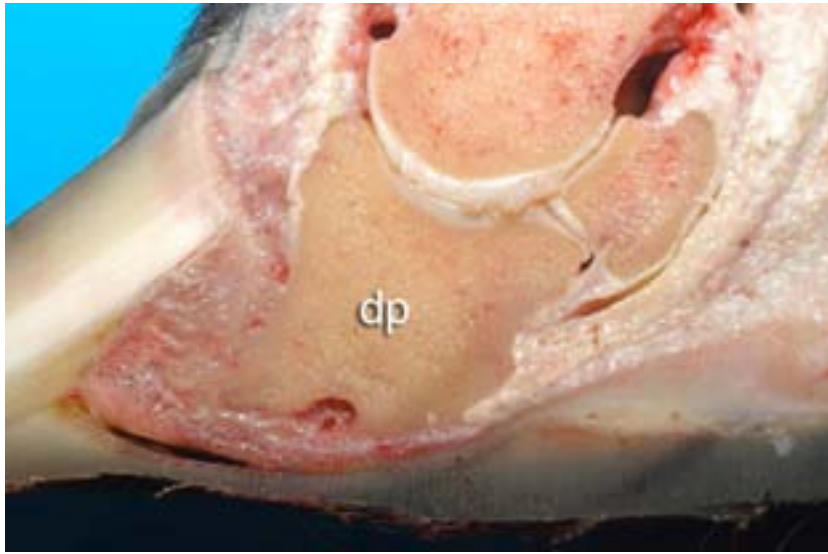


Figure 7-15 *The foot of a horse with severe chronic laminitis of long standing. There is extensive remodeling of the tip of the distal phalanx (dp). The convex sole is weight bearing.*

Prolapse of the distal phalanx through the sole of the foot is usually accompanied by infection. The sole may be under-run and gas lines delineating the solar corium may be visible on lateral radiographs. Osteomyelitis of the distal phalanx and abscess formation may cause pus and gas to discharge from the coronet. In chronic laminitis of long standing there can be spectacular de-mineralization of the distal phalanx and destruction of foot architecture (Figure 7.15).

Laminitic horses with significant initial lamellar destruction, as manifest by radiographic displacement of the distal phalanx, appear never to make a complete anatomical recovery and are prone to recurrent episodes of foot pain. Ultimately, the prognosis is directly proportional to the severity and extent of lamellar and tubular hoof displacement and pathology. Horses with more than 15 degrees of rotation, accompanied by downward displacement of the distal phalanx into the hoof capsule within 4-6 weeks of the initial episode of laminitis, have a poor prognosis. Prolapse of the distal phalanx through an already necrotic sole, accompanied by subsolar and sublamellar infection, usually occurs. Pus will discharge from the coronet and the heels. Osteomyelitis and progressive lysis of the distal margin of the distal phalanx will develop. Such cases will require months of expensive supportive care and surgery and although the occasional horse does make a surprisingly good recovery, most suffer months of crippling foot pain and recumbency, and eventually require euthanasia on humane grounds.

7.4 Conclusions

The road to recovery after a serious bout of laminitis is a rocky one. The extent of the lamellar pathology lies hidden beneath the hoof wall and we can only guess at what is really going on. Sequential radiographs, venograms and the initial degree of pain expressed by the horse (often masked by pain-killers such as phenylbutazone) give valuable clues. Rapid sinking of the distal phalanx into the hoof capsule and involvement of all four feet make recovery unlikely. If the horse is clearly more mobile and comfortable after shoeing, this is a sign that the chosen therapeutic technique is working. Over time, the red, necrotic solar corium, beneath the displaced tip of the distal phalanx, will reepithelialise, turning light yellow in colour as new horn cells colonize the damaged area. The reappearance of thick, concave sole is an encouraging development. A return of hoof growth parallel to the coronary band especially at the front of the foot is also encouraging as is the disappearance of venogrographic deficits especially after strategic coronet and toe hoof resection. Many horses recover to be sound enough for breeding purposes or paddock retirement. They will however require prolonged aftercare in the form of frequent expert shoeing and perhaps confinement to a personal yard. A few return to former athletic soundness.

A more complete understanding of the pathologic processes of chronic laminitis, the timing of their appearance and how they can be addressed should help clinicians produce better outcomes for their patients. Over 17 years of laminitis research and clinical experience has enabled the synthesis of this

theory of “**the problem of in-growing tubular hoof**”. Much was made possible by case referrals from clinicians and the willingness of horse owners to donate their animals for euthanasia and further study. The AELRU gratefully acknowledges these contributions to knowledge based medicine.

7.5 Key Points

- Early clinical signs of laminitis include shifting weight from one foot to the other, high hoof temperatures for a prolonged time and bounding pulses in the digital arteries. A pain response elicited by hoof tester pressure may not always be present, nor marked lameness during a trot-out.
- After the development of more extensive lamellar pathology, foot pain increases and its severity is proportional to the extent of displacement of the distal phalanx within the hoof capsule. A characteristic stance and gait is adopted by the horse to minimize the pain in its feet.
- Chronic laminitis is marked by persistent lameness and anatomical disintegration of the hoof that includes changes to the coronary band, the development of a dropped sole and deformed hoof growth.
- Radiographic and venographic examination of the feet should be performed as soon as clinical signs of laminitis appear and during the course of treatment.
- Inward growing tubular hoof is destructive and contributes to rotation and lysis of the distal phalanx.

8. Radiology of laminitis

As the histopathology of laminitis clearly shows, the major feature of acute laminitis is a progressive increase in the distance between the hoof wall and the distal phalanx. Initially this distance is microscopic in scale, but rapidly progresses to a separation measurable in millimetres. In radiological terms, this translates to an increase in the distance between the outer hoof wall and the upper surface of the distal phalanx, for convenience, the hoof, distal phalangeal distance (HDPD). The HDPD never varies in normal horses (**Figure 8.1**). If the HDPD increases, laminitis is the likely cause and it is extremely important to know the rate and magnitude of the HDPD increase. Good quality radiographs, documenting the shifting status of the distal phalanx within the hoof capsule, supply important diagnostic and prognostic information and should be part of the work-up of every laminitis case.

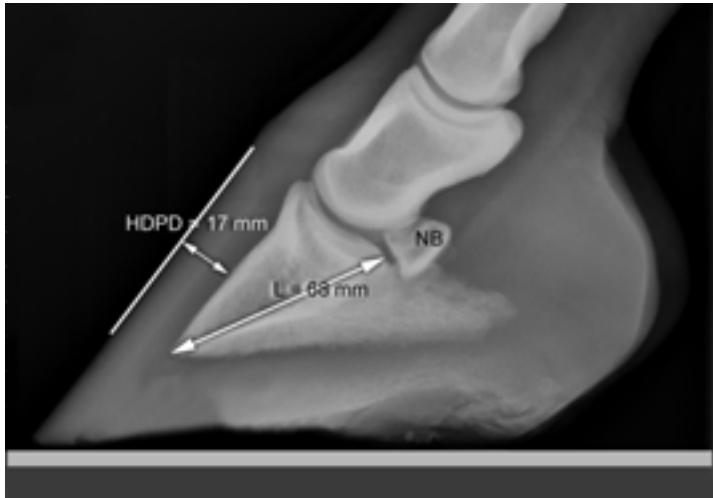

Figure 8-1 Lateromedial radiograph of a normal foot.

The thickness of the dorsal hoof wall and the underlying connective tissue is proportional to the size of the foot, which in turn is directly related to the size of the distal phalanx. Thus, the distal phalanx can be used to measure the thickness of the tissue between it and the surface of the dorsal hoof wall. The distance between the radiopaque rod taped to the dorsal surface of the hoof wall and the dorsal cortex of the distal phalanx is the hoof distal phalanx distance (HDPD), normally

16-18mm in horses weighing 400-450kg. The length of the palmar cortex of the distal phalanx (L) is measured from the tip of the distal phalanx to the articulation of the distal phalanx (DP) and the navicular bone (NB). The HDPD in the normal horse is approximately 25% of L. Note that in the normal horse the hoof wall (as shown by the radiopaque marker) is parallel to the dorsal cortex of the distal phalanx.

8.1 Radiographic technique

The x-ray beam should be at a predetermined distance from the film, at right angles to the sagittal plane of the foot and centered midway between the heel and the toe, 2-3 cm above the bearing surface of the hoof wall. The foot should be clean with the shoe removed, at least for the initial radiographic examination. Excess sole and frog should be pared away with a hoof knife and any mud and gravel removed with a wire brush. As the beam of most x-ray machines cannot be lowered closer than 10cm above ground level the horse should be standing with its forefeet on wooden blocks or boxes 10-15 cm thick so that the x-ray beam can be centered on the foot while kept parallel to the ground (**Figure 8.2**). A radiopaque marker, in the form of a straight metal bar or rod, should be embedded in the edge of the wooden block closest to the film cassette. This creates a horizontal line on the radiograph against which the angle of the distal phalanx can be calculated.



Figure 8-2 Horse standing on boxes to align x-ray beam with distal phalanx. Most horses will co-operate with this procedure. The x-ray beam is centred on the foot and parallel to the ground. A radiopaque marker (a straight metal bar) is embedded in the edge of the wooden block on the side closest to the film cassette (R). This creates a horizontal line on the radiograph against which the angle of the distal phalanx can be calculated. A straight metal marker (a 50-70 mm steel rod, the flat side of a horse shoe nail or a strip of barium paste) is applied to the surface of the dorsal hoof wall (arrowhead) to locate the outer surface of the dorsal hoof wall on the radiograph.

8.2 Radiology of acute/early chronic laminitis

A straight metal marker (a 50-70 mm steel rod) or narrow strip of barium paste should be placed on the surface of the dorsal hoof wall, to locate the outer surface of the dorsal hoof wall on the radiograph. This applies to digital as well as film radiographs because, despite appearances, the precise outer edge of the hoof wall is not fully recorded on the digital image. Another marker, usually a drawing pin or thumbtack, should be inserted into the apex of the frog as an anatomical reference for subsequent shoe fitting. A radiographic marker (such as a ball bearing, lead shot, small screw) can be left in the proximal hoof wall to serve as a reference point for subsequent measurement of downward vertical displacement of the distal phalanx, should this occur. For the majority of normal horses in the 400-450 kg bodyweight range, the mid-wall HDPD (the distance between the marker and the outer edge of the distal phalanx) is between 16-18 mm on radiographs uncorrected for magnification error. The hoof wall and the dorsal cortex of the distal phalanx are parallel in the normal horse.

Radiographs of horses or ponies, in the acute/early chronic stage of laminitis, should be examined for an increase in the HDPD (**Figure 8.3**). An increase of just 2-3 mm is extremely significant in the context of early chronic laminitis. In the first few days of the chronic phase, the hoof wall and the distal phalanx will draw apart, but remain parallel.

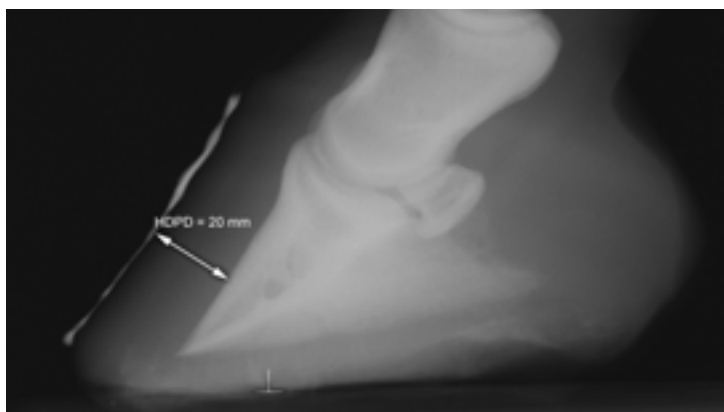


Figure 8-3 Severe chronic laminitis: lateromedial radiograph.

The position of the distal phalanx relative to the dorsal hoof wall changes as laminitis allows the bone descends into the hoof capsule. If the distance between the marker on the dorsal hoof wall and the dorsal surface of the distal phalanx exceeds 16-18 mm this is early, valuable evidence that laminitis has occurred. Remedial medical and mechanical

support for the foot should begin immediately. In the laminitis radiograph illustrated, the distance between bone and dorsal hoof wall is 20 mm. The drawing pin was placed in the tip of the frog to act as a reference point for the accurate placement of a heart bar shoe. The sole is convex (dropped sole) and there is no rotation, yet, of the distal phalanx, from the axes of either the dorsal hoof wall or the first and second phalangeal bones. (Radiology: A van Eps).

Rotation of the distal phalanx relative to the hoof wall and/or the phalangeal axis occurs later (after about 6 weeks). A valid diagnosis of early chronic laminitis can be made on the basis of a small increase in the HDPD. With an early diagnosis, prevention of any further increase by the application of the correct medical and supportive shoeing strategies may be possible. It is a mistake to let rotation of the distal phalanx be the sole diagnostic criterion of chronic laminitis; the diagnosis can be made earlier than this with good quality radiographs. Early diagnosis and early treatment produce better outcomes.

8.3 The rate at which the HDPD increases correlates with the severity of the acute lesion.

When the bulk of the lamellar attachment apparatus fails simultaneously and there is circumferential separation of hoof from the distal phalanx, the HDPD increases. The distal phalanx sinks vertically into the hoof capsule, without palmar rotation, and such cases are appropriately termed ‘sinkers’. The distance from the proximal edge of the hoof wall to the extensor process also increases. When sinkers are dissected the hoof wall falls away free of its dermal connective tissue attachments to the distal phalanx (**Figure 8.4**).



Figure 8-4 Dissection of the dorsal hoof wall affected by severe acute (early chronic) laminitis.

Parallel saw cuts were made through the dorsal hoof wall. When it was cut away from the sole, the wall was devoid of any connections to the underlying dermis and could be lifted away. The distal phalanx sinks ‘vertically’, there is no palmar rotation and radiographs show only an increase in the hoof distal phalanx distance.

This, the most severe outcome of the laminitis process carries with it the gravest of prognoses, especially if it has occurred in all four feet. The animal suffers intense unrelenting pain, there is virtually no hope of a satisfactory recovery; euthanasia is usually the only logical option. It is emphasized that severe, life-threatening laminitis can be diagnosed without palmar rotation of the distal phalanx being evident on lateromedial radiographs. Predicting when a horse will become a sinker is difficult.

The radiolucent line which forms beneath the inner hoof wall is also an indicator of severity. Its presence means that considerable lamellar separation and stretching has occurred. Dissection and histopathology of lamellae, which display the linear radiolucency, show that the lucent zone corresponds to a series of dorsal epidermal lamellae between which the dermal lamellae are absent. Air or gas is in the spaces once occupied by the dermal lamellae (**Figure 8.5**). The spaces between the lamellae are dry and the lamellae readily peel apart. Usually the tips of the epidermal lamellae are still connected to the lamellar corium. How the gas forms between the lamellae, when the hoof capsule and the surrounding tissues are still intact, is a mystery, but one explanation is that the gas is nitrogen, coming out of solution in the blood, as progressive lamellar separation creates a vacuum (a gradient of negative pressure). The linear, radiolucent zone is sometimes erroneously referred to as a seroma; however serum is not radiolucent.

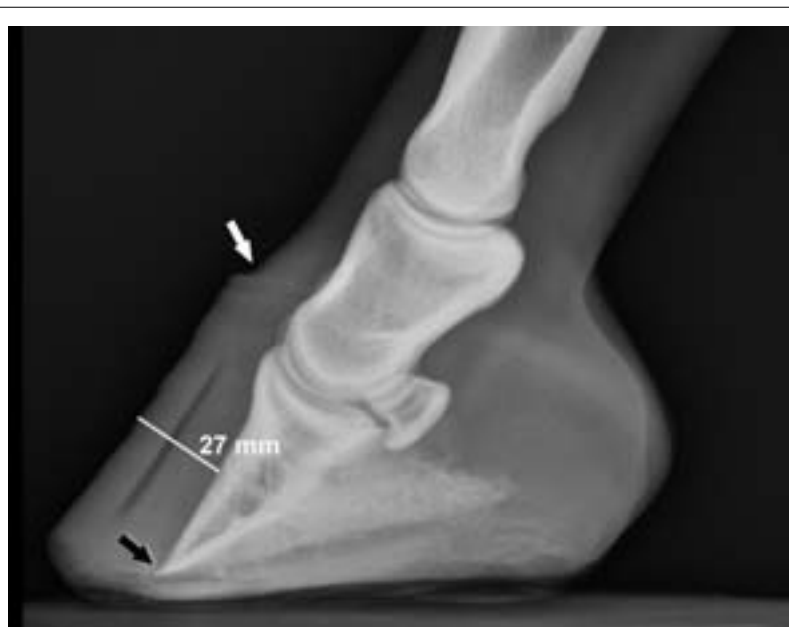

Figure 8-5 Radiograph of a foot with severe, chronic laminitis of 4 weeks duration (same foot as in Figure 8.3).

There is a deficit at the dorsal coronet (white arrow) created when the distal phalanx sank deeply into the hoof capsule and a radiolucent line adjacent to the inner edge of the hoof wall. The sole is convex (dropped sole) and the distal phalanx is close to the ground surface (black arrow). The HDPD is 27 mm (normal=17 mm) and there is slight rotation of the distal phalanx away from the hoof wall. (Radiology: A van Eps).

In acute/chronic laminitis, lateromedial projections supply the most information. However, two other projections supply useful data and should be included in the radiographic examination. They supply reference information that could be useful later if the case deteriorates with increasing chronicity. The dorsoproximal-palmarodistal (“upright pedal” or “high coronary”) view, exposed to show the tip of the distal phalanx, records demineralisation and progressive osteomyelitis of the tip of the distal phalanx (**Figure 8.6**).

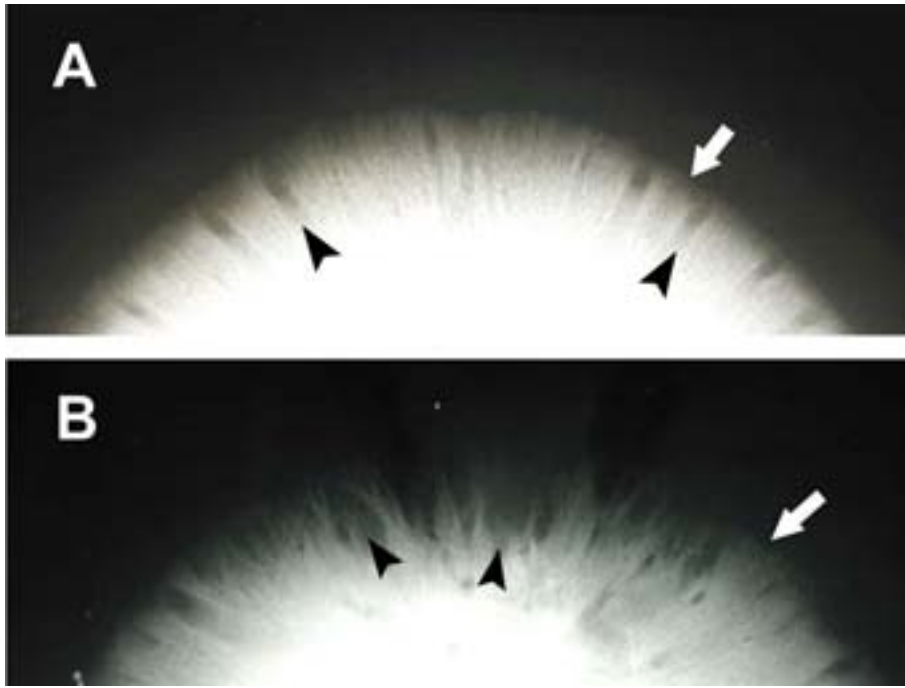


Figure 8-6
Radiographs of
normal (A) and
chronic laminitis (B)
distal phalanx.

The radiographs were made using the oblique proximodorsal-palmarodistal ('upright pedal' or 'high coronary') view. Exposure was adjusted to show the margin of the distal phalanx. The margin of the normal distal phalanx (A) is sharp (white arrow) and has a regular, curved outline. The radiolucent gaps

intersecting the solar margin (arrowheads) are vascular channels radiating out from the terminal arch of the distal phalanx (not shown). Chronically foundered horses (B) develop a demineralised distal phalanx; bone is resorbed from the solar margin. The solar margin is ragged in outline, no longer uniformly radiopaque and is only clearly outlined laterally and medially (white arrow). The vascular channels are enlarged and distorted reflecting the congested, engorged state of the circulation.

margin (arrowheads) are vascular channels radiating out from the terminal arch of the distal phalanx (not shown). Chronically foundered horses (B) develop a demineralised distal phalanx; bone is resorbed from the solar margin. The solar margin is ragged in outline, no longer uniformly radiopaque and is only clearly outlined laterally and medially (white arrow). The vascular channels are enlarged and distorted reflecting the congested, engorged state of the circulation.

The dorsoproximal-palmarodistal ("standing") view, with the x-ray beam parallel to the ground, shows if the linear, radiolucent lines, usually beneath the dorsal hoof wall (as shown by the lateromedial projection) are also present beneath the lateral and medial hoof walls. If they are present (**Figure 8.7**) this means that separation is extensive (not just confined to the toe as it often is) and the gravity of the prognosis is increased. Dorsal hoof wall resection is contraindicated if radiolucent lines are visible at the quarters, under the lateral and medial hoof walls.

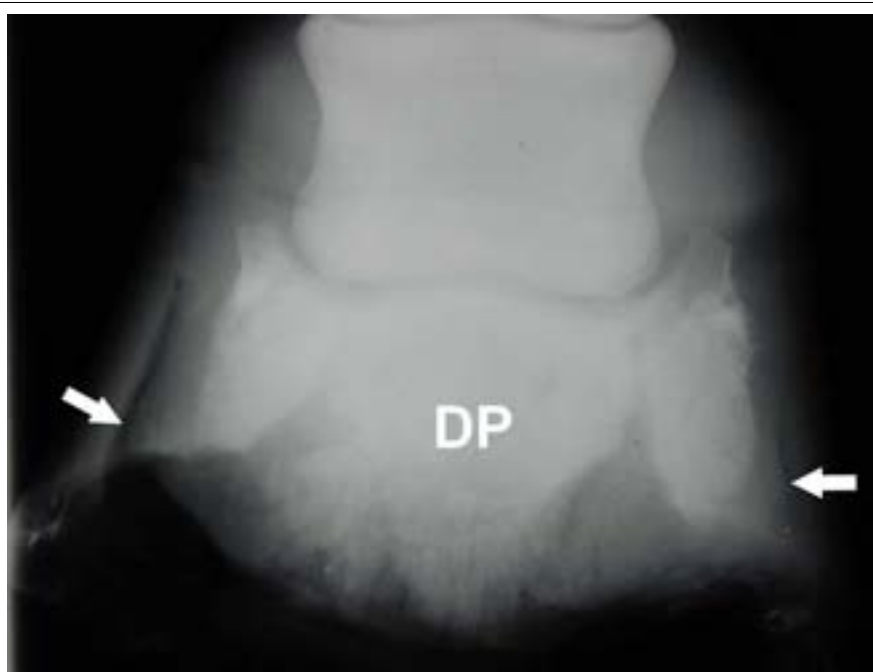

Figure 8-7
Proximodorsal-
palmarodistal
('standing') view of a
foot with severe chronic
laminitis.

The radiolucent lines (arrowed) show that the distal phalanx (DP) has separated from the lamellae of the medial and lateral hoof walls. The radiolucent line is usually confined to the dorsal hoof; finding radiolucent lines beneath the medial and lateral hoof walls worsens the prognosis.

With increasing chronicity, the distal phalanx continues to sink and move away from the hoof wall. The tip of the distal phalanx gradually rotates away from the dorsal hoof wall and begins to compress the corium of the sole; the tip of the distal phalanx gets closer to the ground (**Figure 8.5**). As pressure between bone and sole increases, the sole undergoes necrosis and the tip of the bone slowly disappears (osteolysis). Lateral and oblique dorsal-palmer radiographs show the degree of rotation and lysis of the distal phalanx. Also contributing to bone lysis is the impact of inward growing tubular dorsal sole described in chapter 7). However it is the severity of pain and lameness at the time laminitis is first detected that more reliably predicts the outcome for the horse. Most veterinarians agree that the Obel system for grading the lameness of laminitis takes precedence over the radiographic determination of distal phalanx rotation for predicting final outcome. The good correlation between the extent and severity of histological, lamellar damage and grade of lameness supports this view (Pollitt 1996).

In addition to rotation, the distal phalanx should be examined radiographically for progressive bone remodelling, distal margin fractures, osteolysis and osteomyelitis. These changes take several weeks (at least 5-6 weeks) to develop after the onset of laminitis and when present indicate that the horse is well into the chronic stage. They occur at the tip of the rotating distal phalanx where downward pressure against the sole, or in severe cases the ground, is at its greatest. At this time inward growing tubular white line and dorsal sole hoof makes contact with the distal margin and promotes further bone lysis. In mild, chronic laminitis, where palmar rotation is minimal (<5.5 degrees) the tip of the distal phalanx remodels and appears “ski-tipped” in lateral radiographs. Rapid, extensive bone lysis accompanies severe palmar rotation of the distal phalanx (>11.5 degrees) and such horses are poor candidates for rehabilitation.

8.4 Key points

- Radiographs that supply information on the position of the distal phalanx and HDPD should be obtained with careful radiographic technique to allow early diagnosis and treatment.
- The rate at which the HDPD increases and the appearance of a radiolucent line beneath the inner hoof wall are indicators of the severity of the lamellar pathology.
- When the distal phalanx sinks rapidly into the hoof capsule, without rotation, the cases are labelled “sinkers” and have catastrophic outcomes.
- With increasing chronicity, the degree of palmar rotation and pathology of the distal phalanx should be determined radiographically.

9. Venography of laminitis

9.1 Introduction

Venography was developed in our laboratory in 1991 to determine if retrograde venous therapy of the equine digit was possible. Radiographs showed that the lack of valves in all veins below the mid-pastern region enabled near complete retrograde filling with 20-25 ml of radiopaque contrast media (Figure 9.1 and 9.2). In 1992 the technique was shown to Ric Redden the eminent, equine podiatrist of Kentucky, USA who has since used venography extensively and encouraged its wide spread use.

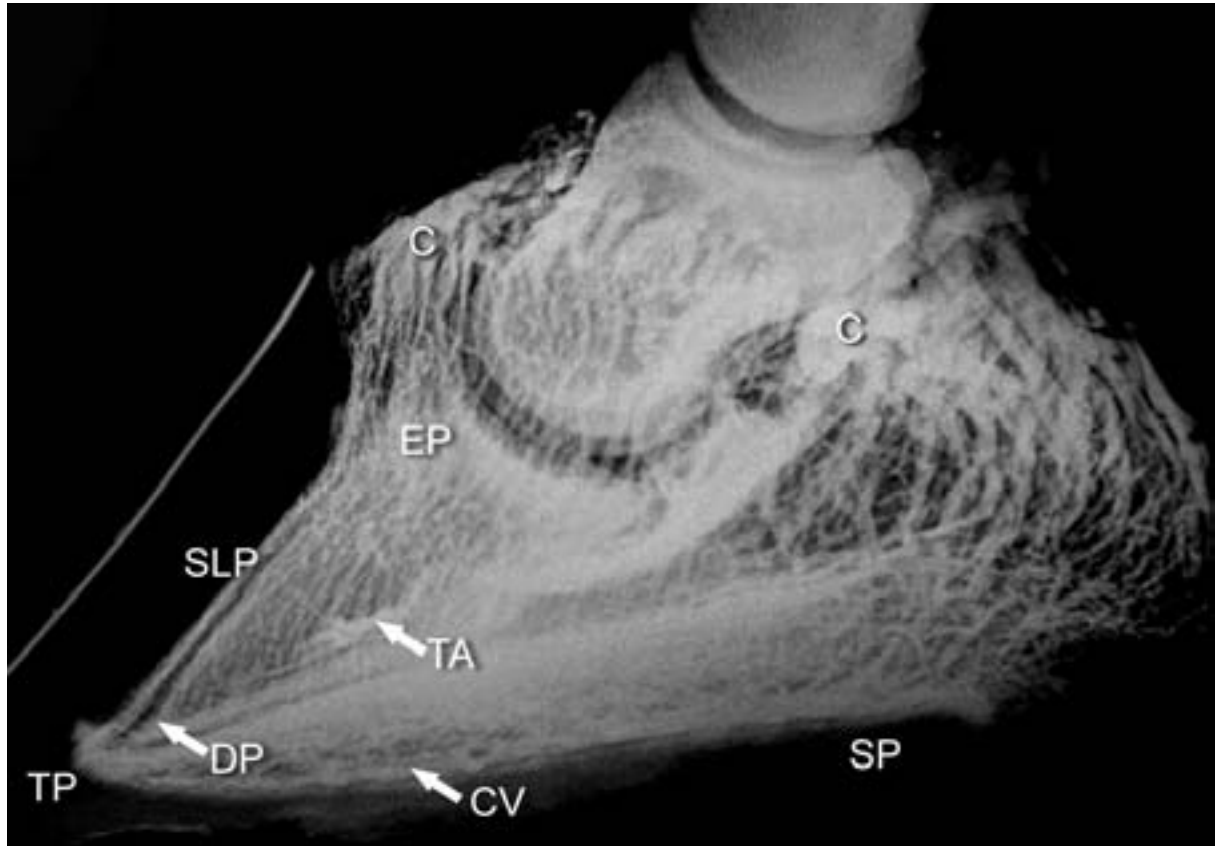


Figure 9-1 Lateral venogram of a normal foot made with digital equipment.

Most of the vessels are large veins. Veins in sole and terminal papillae are visible but not the veins and capillaries between lamellae. C = Coronary venous plexus. EP = extensor process of distal phalanx. SLP = sub-lamellar plexus. TA = terminal arch vessels (arrowed). DP = distal phalanx (distal margin arrowed). TP = terminal papillae. CV = circumflex vein (arrowed). SP = sole papillae. Venogram: Homestead Equine Hospital, MO, USA.

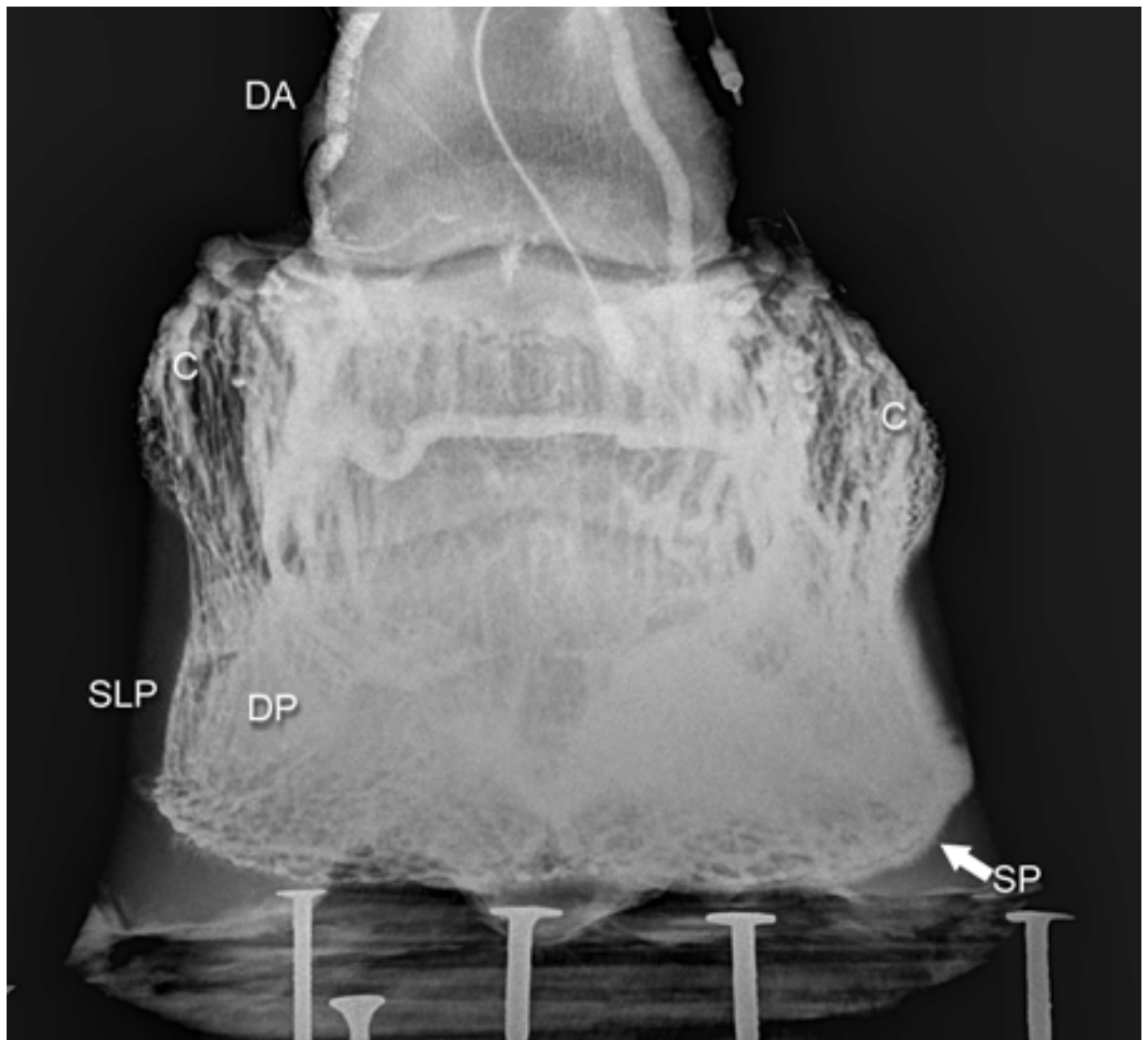


Figure 9-2 Dorsopalmar venogram of a normal foot made with digital equipment.

Most of the vessels are large veins. DA = digital artery with 'string of beads' appearance. C = Coronary venous plexus. SLP = sub-lamellar plexus. DP = distal phalanx. SP = sole papillae. Venogram: Homestead Equine Hospital, MO, USA.

Venography is a relatively simple and practical method for assessing the state of the digital circulation in the standing, sedated horse. During the chronic phase of laminitis the distal phalanx shifts from its normal position and descends in the hoof capsule. In severe cases pathological changes continue to develop and worsen over time and venography enables early assessment of pathology that would otherwise remain undetected. In moderate to severe chronic laminitis there is structural damage to the coronary, sublamellar and solar circulation that results in ischaemic necrosis of the surrounding tissue and lysis and ongoing destabilisation of the distal phalanx. We have used venography to investigate clinical case material and conducted experiments to document vascular changes as horses progress from normal into the acute and chronic phase of laminitis. Knowing when venographic compromise occurs in the acute or chronic phase of laminitis and linking this to the pathology of tissue obtained *post mortem* provides a better understanding of the chronic laminitis process. Importantly the information obtained from venography informs on remedial measures and whether they are successful or not.

9.2 Venographic technique

Performing a venogram requires good radiographic technique and team work. To enable subsequent analysis a radiopaque marker should accurately delineate the surface of the dorsal hoof wall even if using digital equipment. A narrow strip of barium paste, applied to the hoof wall conforms to flares and other wall deformities and is the most accurate method. A 3 mm strip of the lead impregnated fabric from a discarded lead apron also conforms to the hoof wall may be used instead. If the hoof wall is genuinely straight a fine metal rod will suffice. Satisfactory plain shots should be done first to ensure all parameters that may affect quality are catered for. The venogram views of most value are the lateral/medial and the horizontal proximal dorsal/distal palmar views (parallel to the ground); there is little time for any others as the contrast material diffuses from the digital vessels and blurs the image (hence the need for team work; everything needs to be ready for rapid action).

The horse should be well sedated with the foot under investigation thoroughly cleaned and nerve blocked at the abaxial sesamoid sites. The medial and lateral sides of the pastern should be clipped and prepared as for surgery. An Esmarch's bandage (tourniquet) is applied tightly around the fetlock starting proximally and progressing distally to distend the digital veins (the opposite of the usual surgical application). Latex rubber bicycle inner tubes make satisfactory tourniquets.

The distended digital vein can be palpated with the gloved finger. The concave curve of the midpastern makes needle placement difficult – there is a tendency to push the needle through to the other side. The original description recommended a short scalp vein 21G needle and many use this successfully as the tubing leading from the needle makes syringe attachment easy. However, if the horse moves the needle can damage the vein and increase the chance of peri-vascular injection of contrast material and technique failure. To circumvent this risk an indwelling catheter (22G, 25mm), with an un-capped extension tube pre-attached, can be placed into the vein. Use a scalpel to cut down through the skin over the vein and carefully introduce first the needle (a few mm) and then the catheter all the way down into the vein (Figures 9.3).



Figure 9-3 Venogram technique. A 22G, 25 mm intravenous catheter, with pre-attached extension tube (ET), has been placed in the digital vein (arrowed) after skin cut-down over the vein. The distal limb is nerve blocked at the abaxial sesamoid site and Esmarch's rubber bandage has been applied at the fetlock.

Once free backflow of blood is established and the line is patent and free of air bubbles the extension tubing is capped with a latex injection site and the catheter is taped in place (Figure 9.4) out of the x-ray beam. Back pressure will dislodge the catheter so taping is important.

Most 450 kg horses will need 20-25 ml of contrast material for the venogram. Employ any of the contrast agents used for myelograms, undiluted (e.g. Urografin 76, Iomeron 350 or Omnipaque). The use of 2 smaller 10 ml syringes instead of one large syringe enables greater hydraulic pressure to be exerted.

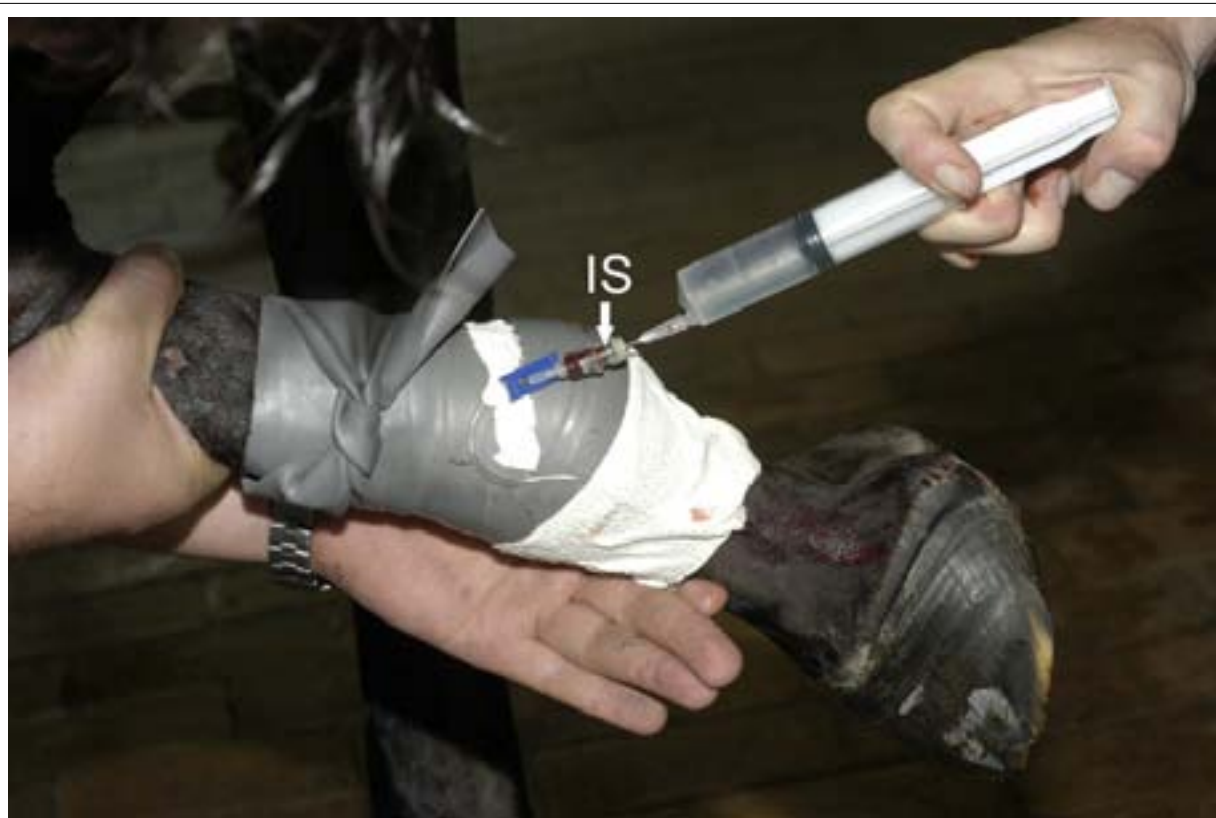

Figure 9-4 Venogram technique.

Contrast medium (20-25 ml) is injected into the catheterised digital vein via the latex injection site (IS) attached to the extension tube. The limb must be non-weight bearing (unloaded) during the procedure to ensure filling of coronary and sublamellar veins.

When injection commences the team must be ready to expose the plates with the x-ray beam focused level with the palmar/plantar aspect of the distal phalanx. The horse stands on pre-designed boxes or blocks to achieve this. The foot should be made non-weight bearing during or just after the injection – the dorsal vessels will not fill otherwise. Some remove 15ml of blood before injecting contrast but this seems to make little, if any, improvement. Inject at least 20 ml contrast medium through the injection site. There may be significant back pressure – detected after the first 15ml. Shoot two high and low contrast laterals first and quickly position the equipment for the horizontal dorso/palmar shots.

After a few minutes contrast diffuses from the vessels and subsequent radiographs deteriorate. Release the tourniquet, remove the catheter or needle and bandage a small gauze pad over the venipuncture site to prevent haematoma formation.

Practice on normal/teaching horses first. Some believe that venography is therapeutic but this remains to be properly tested.

9.3 Venography of acute/early chronic laminitis

Venography detected changes in hoof anatomy as early as 5-7 days after laminitis development (Baldwin and Pollitt 2000). The severity and rate at which venographic changes developed correlated to the degree of lameness. Sequential venograms and measurements gave important information about the insidious pathology that chronic laminitis inflicts on foot structures within the hoof capsule.

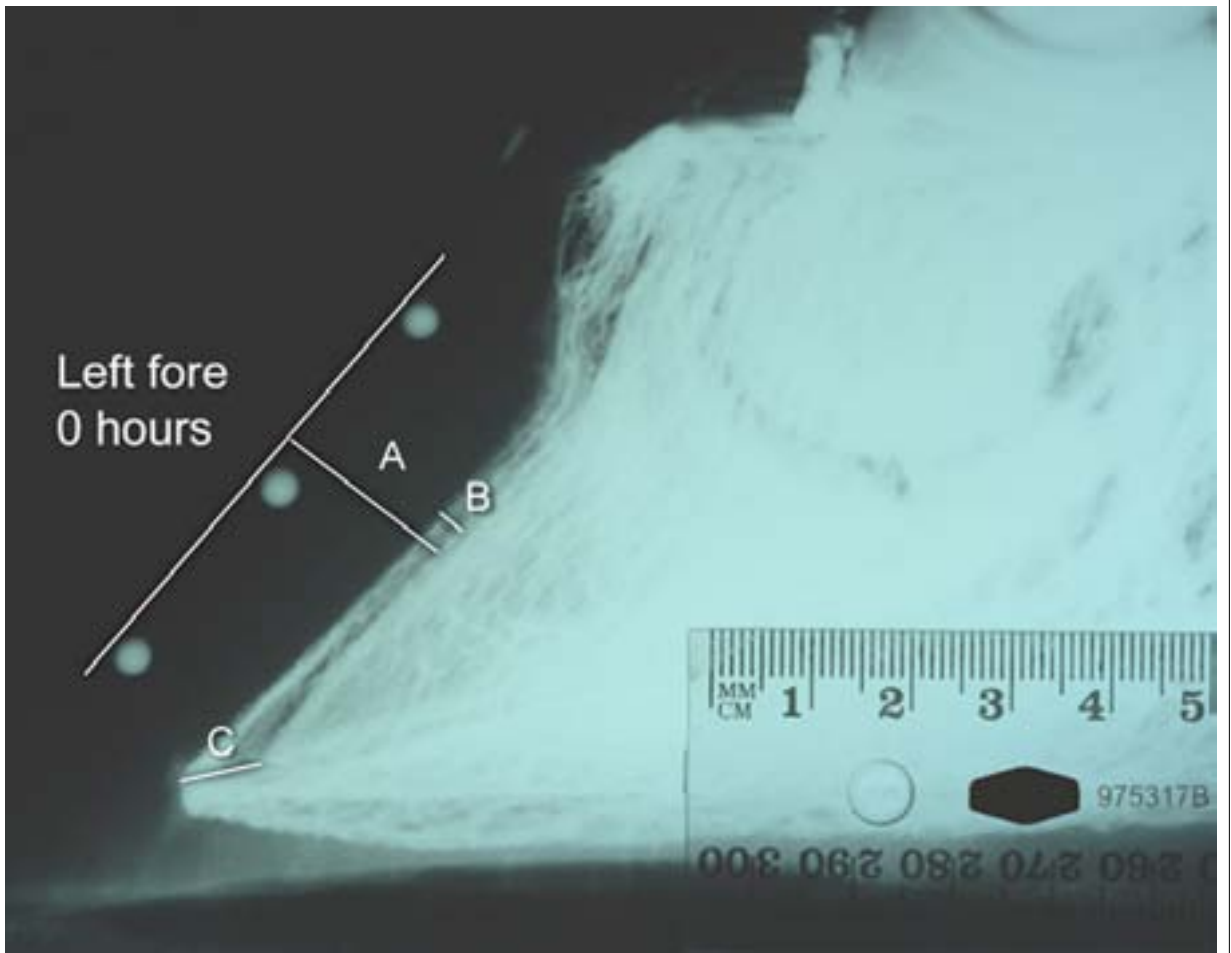


Figure 9-5 Normal venogram of an adult Standardbred gelding.

Round lead pellets were embedded in the dorsal hoof wall so that standard measurements of the dorsal hoof wall distal phalanx distance (length A) could be made over time. The width of the dorsal sub-lamellar venous plexus (B) and the distance between the tip of the distal phalanx and the dorsal circumflex vessels (C) was also measured. Venogram: Greg Baldwin.

In normal, pre-laminitis venograms (Figure 9.5) measurements were made in 9 pairs of front feet. The mean distance between the outer hoof wall and the distal phalanx (A) was 18.2 mm. The distance B was 3.0 mm and distance C was 8.0 mm.

When laminitis had been in existence for 5-6 days (Figure 9.6) the distal phalanx had sunk into the hoof capsule and the distance (A) between the hoof wall and distal phalanx had increased by 1.7 mm to 19.9 mm. There was a positive correlation between the increase in A and lameness grade ($p < 0.01$).

The sublamellar vascular bed width (B) increased by 1.5 mm to 4.5 mm. There was also a positive correlation between the increase in sublamellar vascular bed width (B) and lameness grade ($p < 0.01$). Similarly the distance between the tip of the distal phalanx and the dorsal circumflex vessels (C) increased 1 mm from 8.0 mm to 9.0 mm. In 7 day venograms there was mild deterioration of the venous filling with contrast medium of the coronary plexus (asterix in Figure 9.6). The tip of the

distal phalanx had sunk further below its normal position of above the circumflex vessels giving an indication of the severity of the acute episode.

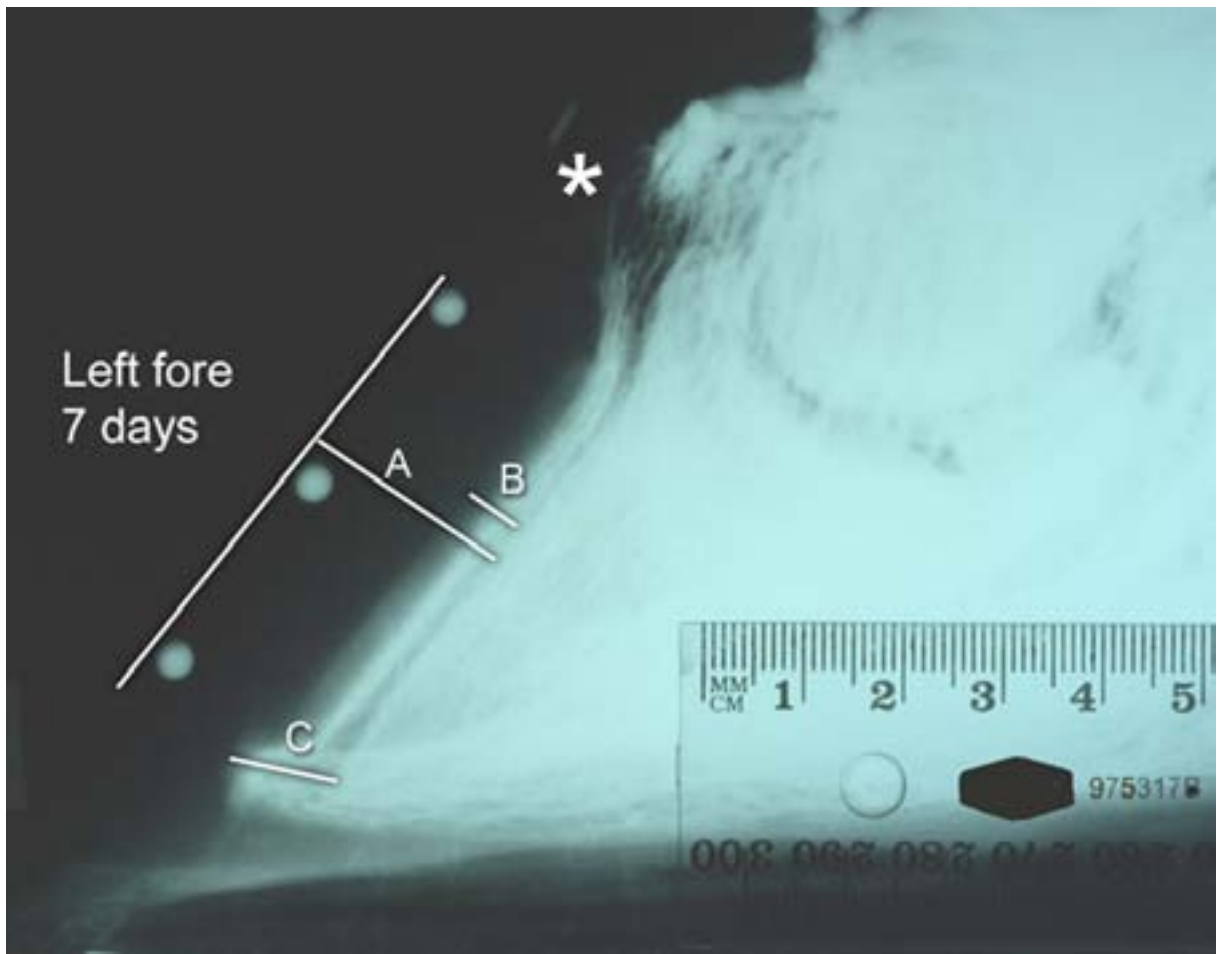


Figure 9-6 Venogram of the same adult Standardbred gelding in Figure 9.5 made 5 days after acute laminitis developed.

The hoof distal phalanx distance (length A) has increased. The width of the sub-lamellar venous plexus (B) and the distance between the tip of the distal phalanx and the circumflex vessels (C) also increased. The tip of the distal phalanx is no longer above the circumflex vessels. Venogram: Greg Baldwin.




Figure 9-7 Venogram of the same adult Standardbred gelding in Figures 9.5 and 9.6 made 28 days after acute laminitis developed.

Filling of coronary vessels (asterix) is absent. The hoof distal phalanx distance (length A), the width of the sub-lamellar venous plexus (B) and the distance between the tip of the distal phalanx and the circumflex vessels (C) have continued to increase. The tip of the distal phalanx (arrowed) has lost density and is below the circumflex vessels which are now poorly outlined. Venogram: Greg Baldwin.

When laminitis had been in existence for 28 -42 days (Figure 9.7) the distance (A) between the hoof wall and distal phalanx had further increased by 4.0 mm to 22.5 mm. There was still a positive correlation between the increase in A and lameness grade ($p < 0.05$). The sublamellar vascular bed width (B) increased by 2.5 mm to 5.4 mm. Similarly the distance between the tip of the distal phalanx and the dorsal circumflex vessels (C) increased 3.3 mm from 8.0 mm to 11.3 mm. In contrast to 7 day venograms, where there was mild deterioration of the venous filling of the coronary plexus, after 21 days filling of coronary vessels was absent (asterix in Figure 9.7). The tip of the distal phalanx had sunk further below its normal position above the circumflex vessels suggesting that sinking/rotation of the distal phalanx, now weeks after the initial laminitis episode, was an on-going processes. The tip of distal phalanx was radiolucent and just visible. Venographic changes (widening and distortion of the sublamellar and circumflex vascular beds) were present 7 days post-induction and indicated displacement of the distal phalanx. Horses with severe laminitis developed progressively greater venographic changes (especially filling deficits) while the changes of mildly affected horses stabilised. Serial venography gave important information into otherwise non-visible vascular pathology. Venographic changes occurred in virtually all cases of clinical laminitis, often when subtle plain radiographic changes were inconclusive. Venography of chronic laminitis supplied additional information about the magnitude of the changes that occurred during the development phase and subsequently and is thus superior to plain radiography. Venography contributes to the development of more effective laminitis case management.

9.4 Digital radiography and venograms.

Venograms performed with digital radiographic equipment produce good results with somewhat superior definition and contrast. In lateral to medial radiographs the sublamellar veins show strong contrast but vessels between lamellae do not. The terminal papillae at the distal ends of the lamellae, are visible and may form a notch more dorsal than the rest of the circumflex vessels (Figure 9.8). Vessels within the terminal arch of the distal phalanx fill with contrast and these may be veins or arteries or both. Digital arteries do fill with contrast and can be recognised mid-pastern by their 'string of beads' appearance. The normally well filled coronary venous plexus is a feature of venograms and is visible dorsal to the extensor process of the distal phalanx and follows the dorso-palmar angle of the coronary band.



Figure 9-8 Sagittal section (A) and digital venogram (B) of normal toe superimposed (C) to show relationship between distal phalanx and the veins of the dorsal sole and terminal papillae.

9.5 Key Points

- Venography is possible because there are no valves in the veins of the horse's foot.
- Performing a venogram is relatively simple but requires practise and good radiographic technique.
- Venograms provide more information than plain radiographs especially if performed sequentially.
- Venograms diagnose venous filling problems due to progressive pathological changes in tubular hoof wall and sole growth.

10. Laminitis Medical Therapy

10.1 Laminitis therapy

From the outset it must be stated that a therapeutic regime, using biological or chemotherapeutic agents, able to arrest or block the triggering of laminitis, does not exist. On the other hand, there is a plethora of remedies, used empirically, that symptomatically help the horse after it has acquired laminitis. It is more the extent and severity of the lamellar pathology that influences the outcome for the horse, not the treatment regimen itself. An effective laminitis preventive may emerge when the mechanism behind the disintegration of the anatomy of the hoof wall lamellae is fully understood. Our discovery that a class of enzymes appears to be involved in the lamellar failure of laminitis has led us to commence trials of proteinase inhibitor therapy, specifically targeted at hoof wall matrix metalloproteinases.

Since laminitis usually develops as a sequel to disease processes in body compartments other than the foot, it is of paramount importance that the primary disease is treated urgently and effectively. If the duration and severity of the primary disease can be reduced by intensive therapy, there is a strong chance that the severity of lamellar pathology may also be reduced, thus improving the prognosis for the horse. Nevertheless, severe laminitis is sometimes the outcome despite the best of current therapy.

When the laminitis process is triggered, there is virtually nothing, by way of drug therapy, that will stop its relentless progress. The administration of a nonsteroidal anti-inflammatory drug (NSAID) like phenylbutazone, during the developmental/acute stages, will ameliorate foot pain and create a more comfortable-looking horse, but the disease continues unabated. This creates an ethical dilemma; balancing the need to alleviate pain and suffering against the realisation that most of what is administered is only palliative. When NSAIDs are in use, the patient should be confined to a stall with deep bedding. Exercise in the critical acute phase, while under the influence of painkillers, such as phenylbutazone, is contraindicated.

10.2 Cryotherapy

The results of experiments at the AELRU, continuously evaluating foot temperature (and by implication foot circulation), as horses developed laminitis, showed that vasoconstriction during the developmental stage of laminitis may have had a protective effect (Pollitt and Davies 1998). Thus the induction of digital vasoconstriction during the developmental phase of laminitis may be a useful preventive strategy. Limited anecdotal evidence from practising veterinarians suggests that cryotherapy applied to horses already with acute laminitis may halt the further development of the disease.

The profound hypometabolic effect of cryotherapy is considered to be the most important mechanism by which cold limits the severity of an injury. Tissue metabolic rate and oxygen consumption are inversely related to temperature. A reduced requirement of cooled tissue for glucose, oxygen and other metabolites enhances the survival of cells during periods of ischaemia. This mechanism is thought to protect tissue and is the basis for the use of cryotherapy in organ transplant surgery. Enzymatic activity is reduced 50% for every 10°C reduction in tissue temperature. The activity of collagenases and pro-inflammatory cytokines is also significantly reduced at lower temperatures.

Cryotherapy causes potent local vasoconstriction. This is largely mediated by sympathetic nervous control; however, a direct constrictive effect on blood vessel walls may occur, particularly at lower temperatures. To date clinical recommendations for the duration and temperature of cryotherapy in horses has been extrapolated from human medicine. Our recent studies have challenged these recommendations.

10.3 Cryotherapy: potential mechanisms for preventing lamellar damage

The precise, molecular pathogenesis of acute laminitis is unknown. The diverse effects of cryotherapy, however, have the potential to interrupt many of the pathophysiological mechanisms that are likely to occur during the developmental and acute phases of the disease. A summary is presented in Table 1.

Table 1. The potential mechanisms by which continuous distal limb cryotherapy may prevent acute laminitis (Table: Andrew van Eps).

<i>Pathophysiological mechanisms implicated in the development of laminitis</i>	<i>Potential beneficial effect of cryotherapy</i>
<i>Delivery of 'laminitis trigger factors' to the digit via the circulation</i>	Profound vasoconstriction limits the delivery of haematogenous 'trigger factors' to the digit
<i>Production and activation of excess lamellar matrix metalloproteinases (MMPs)</i>	Profound hypometabolism reduces the production and activation of lamellar MMPs
<i>Enzymatic degradation of lamellar attachments by MMPs</i>	Profound inhibition of enzymatic activity through hypometabolism
<i>Local production and activity of pro-inflammatory cytokines (TNF-α and IL1-β)</i>	Hypometabolic effect reduces the production and activity of cytokines
<i>Inflammatory damage caused by infiltration of polymorphonuclear leukocytes (PMNs)</i>	Vasoconstriction and hypometabolism reduce the delivery and activity of PMNs
<i>Digital hypoperfusion resulting in lamellar ischaemia</i>	Profound hypometabolic effect protects lamellar tissue from ischaemic damage
<i>Reduced cellular glucose availability</i>	Profound hypometabolic effect reduces lamellar requirement for energy substrates

Enzymatic degradation of lamellar attachments by matrix metalloproteinases (MMPs) forms the basis of our pathophysiological theory for developmental laminitis. It is hypothesized that the inappropriate release of excess, activated lamellar MMPs is mediated by "laminitis trigger factors" delivered to the foot via the digital circulation during developmental laminitis. The delivery of these triggers, which may include cytokines, protein fragments or bacterial products of hindgut origin, appear to be limited by cold-induced digital vasoconstriction during the developmental phase of laminitis. This was the basis for evaluating the use of cryotherapy for the prevention of laminitis. The potent local hypometabolic effect of cryotherapy could augment the vasoconstrictive effect on the digital vasculature. A cold-induced reduction in the local production and activity of MMPs would limit degradation of the lamellar attachments. A digital hypometabolic state would also limit the local production and activity of pro-inflammatory cytokines, such as interleukin (IL) and tumor necrosis factor (TNF), during the developmental stage of laminitis. Cryotherapy could also limit secondary inflammatory damage caused by white blood cell infiltration. Similar mechanisms are believed to be the basis for the efficacy of scalp cryotherapy in preventing alopecia in cancer patients undergoing chemotherapy. Vasoconstriction apparently reduces delivery of the chemotherapeutic agent to the scalp, and cellular uptake and metabolism are reduced when residual drug reaches the hair follicles.

Alternate pathophysiological theories for laminitis propose that digital hypo-perfusion during the developmental stage leads to lamellar ischemia and necrosis. Profound, cold-induced vasoconstriction would seem contraindicated if digital hypo-perfusion was the primary mechanism behind the development of laminitis. However, despite a reduction in digital perfusion, the hypometabolic effect of cryotherapy could protect the lamellar tissue from ischaemic damage. Similarly, a profound cold-induced reduction in metabolism could protect the lamellar tissue from a lack of glucose (proposed as an initiator of lamellar separation in one study). Until the true pathophysiology of laminitis is discovered, the apparent resilience of the equine distal limb to prolonged, extreme cold may hold the key to successfully preventing the disease. Continuous distal limb cryotherapy during the developmental stage of laminitis has the potential to preserve the lamellar tissue until the systemic insult, occurring elsewhere in the body, has abated.

10.4 Efficacy of continuous distal limb cryotherapy for the prevention of acute laminitis

10.4.1 Experimental data

We have completed two controlled studies on the efficacy of cryotherapy for the prevention of laminitis. In the first study (van Eps and Pollitt 2004) laminitis was induced in six horses using the oligofructose overload model. Each horse had one forelimb immersed in ice and water (mean temperature 0.5-1.7°C) for a 48 hour experimental period (Figure 10.1), achieving a mean internal hoof temperature of 3.5-0.9°C. All horses developed clinical and histological laminitis in one or more of the untreated limbs. The cooled limbs did not develop clinical laminitis and had significantly reduced lamellar histological damage. The study also showed significantly reduced up-regulation of lamellar MMP mRNA in the cooled limbs when compared with the untreated limbs. Although cryotherapy markedly reduced the severity of laminitis it did not completely prevent minor histological changes in 4 of the 6 horses.



Figure 10-1
Single limb
cryotherapy
trial.

Using a rubber boot (Bigfoot Ice Boots) one forelimb was immersed in ice and water (mean temperature 0.5-1.7°C) for the 48 hour experimental period. The mean internal hoof temperature was 3.5-0.9°C. Laminitis occurred only in the non-cooled untreated limbs. The cooled

limbs did not develop clinical laminitis and had significantly reduced lamellar histological damage.

In a second study cryotherapy was applied to all 4 limbs of 6 horses for 72 h (Figure 10.2). Laminitis was induced as before and the observation period was extended until 7 days post-oligofructose dosing. The horses showed either no or very mild clinical signs of laminitis and histology of lamellar tissues taken 7 days post-induction showed no laminitis. Control horses were lame at 7 days and had moderate to severe laminitis histopathology (van Eps and Pollitt 2004).

Cryotherapy was instigated immediately following administration of the carbohydrate induction bolus in these studies. In a clinical case of grain overload or acute colitis such prompt initiation of cryotherapy may not be possible. It is unclear whether such a potent prophylactic effect would occur if cryotherapy was initiated later in the course of the disease when lameness was already present. Thus the potential of cryotherapy to prevent laminitis has been demonstrated and further clinical evaluation of the technique is justified.

10.4.2 Clinical data

Anecdotal evidence of the successful use of cryotherapy to prevent acute laminitis has surfaced following the initial evidence-based recommendations for its use. The authors have trialed continuous distal limb cryotherapy for the prevention of laminitis in 7 cases of acute colitis (5 Thoroughbred geldings, 1 Thoroughbred colt and 1 Arab mare). All cases presented with fever ($>39.5^{\circ}\text{C}$), profuse watery diarrhoea and signs of endotoxaemia and circulatory shock (injected mucous membranes with poor capillary refill time, rapid heart rate and depression). Only one horse had signs of laminitis before the initiation of cryotherapy. This horse had increased intensity of digital pulses in all four limbs, though lameness was not obvious. All cases were placed into a plastic tub with a rubber floor. Shoes, if present, were not removed. Water, then cubed ice, was added to the tub to submerge the fore and hind limbs. The level of ice and water was maintained at the upper third of the cannon bones. Approximately 100 kg of cubed ice was required to cool the water initially. Subsequently, 50 kg of ice was added at 4- to 8-hour intervals to maintain the temperature within the bath at less than 5°C .

All horses were treated (while in the cold bath) with intravenous polyionic fluids and plasma, antibiotics, NSAIDs and activated charcoal and paraffin oil by nasogastric tube. Lucerne hay and water were provided *ad libitum*. The cases were monitored constantly and remained in the cold bath for a minimum of 72 hours. All horses tolerated the cold bath well, without becoming agitated. The decision to remove the horses from the cold bath after the 72-hour period was based on resolution of clinical signs. Each horse was removed when the rectal temperature stabilized below 38.5°C , faeces was formed, and the mucous membranes returned to normal colour. Five of the horses were removed at, or shortly after, 72 hours. The remaining 2 horses were removed from the bath at approximately 96 hours. None of the horses were lame on removal from the cold bath; however, all had increased intensity of digital pulses in all four limbs for the ensuing 24 hours. Variable distal limb oedema was also present. One horse that had signs of incipient laminitis before commencement of cryotherapy was mildly lame between 12 and 24 hours after removal from the cold bath. The lameness disappeared over the subsequent 10 days of hospitalization and radiographs of this horse revealed no displacement of the distal phalanx within the hoof capsule. It is unclear whether cryotherapy reduced the severity, stabilized the pathology or had no effect on the development of laminitis in this case.

The remaining 6 horses were sound throughout the hospitalization period, and no lameness was detected on subsequent re-examinations 4 to 6 weeks later. All horses returned to athletic activity, reportedly at previous levels. At the time of publication, three of the Thoroughbred

horses have won metropolitan races since discharge. After examination of hospital records, the authors estimate the incidence of acute laminitis in previous similar cases of acute colitis (that were not treated with cryotherapy) to be 40 to 50%. Although these are very limited numbers, the authors believe the prophylactic use of continuous distal limb cryotherapy in similar cases at risk of developing laminitis is worthy of further clinical evaluation.

10.4.3 Application methods

Any means by which the distal limbs can be continually exposed to temperatures of 0 to 5°C is acceptable. The cooling method should be applied to the entire distal limb. We suggest cooling the limb up to the top of the cannon, as this appears to result in more effective cooling of the lamellar region. This takes advantage of the unique distal limb anatomy of the horse; the major arteries are subcutaneous in the fetlock region and the blood they are delivering to the foot can be cooled on its way down. Cooling just the feet is not enough. Laminitis breaks through and is not prevented when only the feet are cooled. Ice and water immersion is effective, practical and inexpensive. Commercial cryotherapy cuff devices and gel packs could be modified to include the hoof, but in trials to date none have effectively cooled the feet sufficient to prevent laminitis. The authors have had experience with a range of boots and tubs for ice and water immersion.

We have found that the use of a tub, 200 cm long, 80 cm wide and 50 cm high, most practical for prolonged, continuous application of cryotherapy to all four limbs (Figure 10.2). A water-tight door at one end for ease of access, and a rubber floor are suggested. Temporary or permanent stocks, together with cross-tying the head may assist in keeping the horse stationary. A refrigerated pump, re-circulating water at around 2°C, can reduce or replace the requirement for ice. Overall, vigilance should be exercised to maintain immersion temperatures below 5°C to maximize the protective effect.



Figure 10-2
The cryotherapy apparatus consisted of a wooden bath holding water to a level just below the carpus. The water was recirculated and chilled to 1°C by a refrigeration pump (inset) and heat exchanger (Thermoline Scientific, Northgate, Qld 4013, Australia.

www.thermoline.com.au). The horses were housed within stocks and given free access to feed and water. An equine diaper (Equisan Marketing Pty Ltd., South Melbourne, Vic 3205 Australia. www.equisan.com.au) kept faeces and urine out of the water.

Continuous distal limb cryotherapy shows considerable promise as a technique for preventing acute laminitis. The authors continue to evaluate cryotherapy in clinical cases at risk of developing laminitis, and welcome correspondence from others engaged in similar pursuits. Currently the most challenging aspect of cryotherapy in the clinical situation is the identification of cases that will develop laminitis, and subsequently deciding when to initiate and cease cryotherapy in these cases. A biological marker to identify horses at imminent risk of developing laminitis is needed. Such a marker would define the clinically silent developmental phase of laminitis in individual cases, and greatly improve the potential for prevention of the acute disease. Undoubtedly genetic markers exist for the early identification of horses developing laminitis. Up-regulation of enzyme m-RNA early in the acute phase of laminitis has been demonstrated in lamellar tissue. If this process begins during the developmental phase of laminitis, particularly within the blood, skin, ergot or chestnut tissue, a diagnostic potential exists. The eventual discovery of the exact pathophysiology of laminitis will surely lead to effective and direct methods of prevention and therapy. In the meantime, the apparent resilience of the equine distal limb to prolonged, extreme cold can be harnessed and holds the key to successfully preventing the disease.

10.5 Management practices to avoid pasture associated laminitis.

Our research provides strong circumstantial evidence that fructan in the hindgut of horses triggers laminitis. Horses can ingest fructan rich pasture rapidly in amounts exceeding (Longland and Byrde 2006) that used to induce experimental laminitis (van Eps and Pollitt 2006).

Owners of horses predisposed to laminitis should develop strategies to reduce risk. Most horse owners in New Zealand and Australia are committed to pasture feeding regimens throughout the year so a combination of both pasture and horse management practices needs to be considered. The aim is to reduce the concentrations of water soluble carbohydrate (WSC) in pasture and to prevent its consumption by the grazing horse.

10.6 Pasture factors

Some pasture species are notorious fructan accumulators (they are selected and bred for this) and if possible should not be fed to horses. The WSC content of grass can reach 56% of its total dry matter (DM), of which fructan can be 44%. Grass that is actively growing tends to store less WSC. Maintaining soil moisture and fertility and keeping grass short by mowing or grazing encourages leaf growth and WSC consumption (Watts and Chatterton 2004). WSC accumulation in grass is driven by photosynthesis and takes time to occur. It peaks in the afternoon and early evening and high WSC intake can be avoided by allowing grazing only in the early morning. Likewise, pasture shaded by tree-lines and windbreaks accumulates less WSC and susceptible horses can be strip grazed behind electric fences in these areas. Some horse managers will poison selected paddocks to eliminate pasture altogether and at time of high risk keep their horses on these “dry lots”. Times of risk are conditions of high light intensity and low ground temperatures such as in spring and autumn. Particular care is indicated at these times. Under these conditions photosynthesis and WSC production is relentless, but growth and metabolism is slow; hence WSC accumulation. Using a cash flow analogy; the bank balance is greatly in credit – cash income exceeds expenditure. Drought or periods of low soil moisture may also drive WSC accumulation and even dry looking pasture can have a high WSC concentration. Drought breaking rain can also be a trap. WSC accumulated in subsoil roots during dry times is rapidly mobilized to new shoots and many a pony has foundered on insignificant looking pasture after rain. Another trap is slashed or heavily grazed pasture or stubble after harvesting. Most of the WSC of grass is stored, not in the green leaves, but in the lower, pale green stems that are the plants WSC reservoir. Grass

that has gone to seed in summer is usually low in overall WSC content in its leafy tissues but could still pose a risk from the starch in the seeds. A yield of starch from the seed of perennial ryegrass has been estimated at 360 kg/ha per growing season (Longland and Byrde 2006). Horses will selectively strip seed from standing pasture and could conceivably consume sufficient starch to trigger laminitis from hindgut fermentation.

10.7. Horse factors

Grazing muzzles have been successfully used to limit grass and thus WSC intake by horses at pasture (Figure 10.3). The hole in the muzzle limits intake and confines consumption to leafy tops that are lower in WSC content.

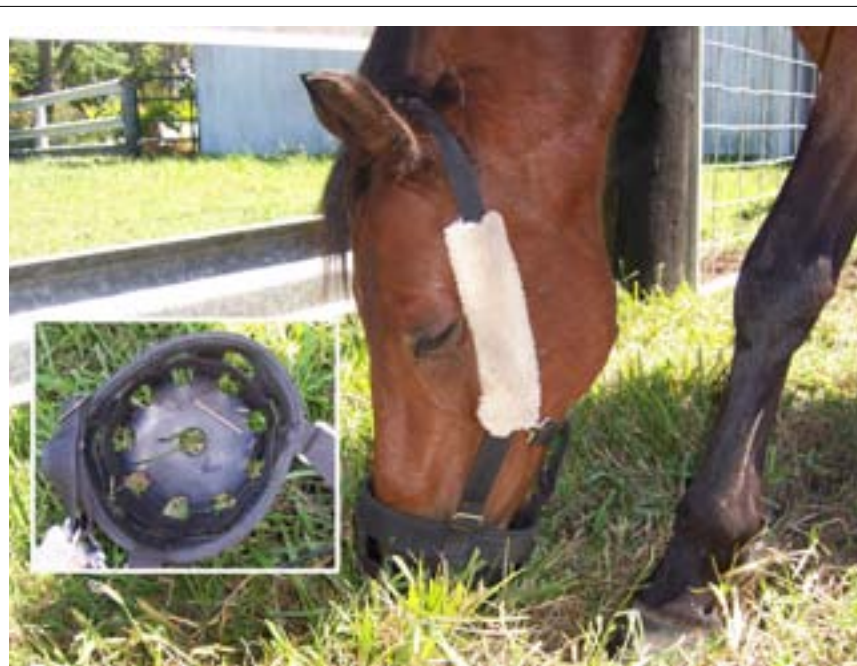

Figure 10-3 Grazing muzzles limit grass and thus WSC intake by horses at pasture.

Holes in the rubber base-plate (inset) allow access to some pasture (photos: Darrin Hatchman). Grazing muzzle (VET2295X) from Saddlery Trading Company, 124 Tennyson Memorial Avenue, Tennyson Qld, Australia 4105.

www.saddlerytrading.com

When horses and ponies have no access to pasture and are yarded or confined to dry lots what are they to be fed? The usual solution is grass or forage hay. However the haymaking process may not always reduce WSC and sometimes the most innocent looking hay may have dangerous WSC levels. If possible choose hay made from mature pasture, made in summer, that has gone to seed. Hay could still be dangerous if harvested during periods of plant stress such as autumn and spring. Analysis of the WSC content of such hay is warranted but not always practical. Fortunately soaking hay in fresh water leaches out WSC (but not starch) and reduces the WSC content significantly. Sixty minutes of soaking and draining removed an average of 31% of the soluble sugars from 15 hay samples (Watts and Chatterton 2004). Pony breeds in particular are prone to obesity and insulin resistance and obese individuals are at high risk of developing laminitis. The diet of obese individuals can be modified so that energy intake is derived from fat and fibre rather than from high glycaemic sources. Owners should monitor the body weight and learn to condition score their horses aiming for more optimum weights. Insulin resistance can be reversed by weight reduction and regular aerobic exercise.

“Founderguard” (Virbac Australia, Milperra, NSW 2214, <http://www.virbac.com.au/>) is an antibiotic formulation that can be fed to horses and ponies at pasture and when present in the hindgut limits the proliferation of *Streptococcus bovis*. When ‘predosed’ it may control hindgut carbohydrate fermentation to levels that prevent serious laminitis.

10.8 Endotoxaemia therapy

Horses diagnosed with toxæmia during enteritis, colitis, strangulating colic, pleuropneumonia, septic metritis (retained placenta) and grain overload are at high risk of developing laminitis and ideally, cryotherapy, medical therapy and mechanical support for the distal phalanx should be initiated before the clinical signs of foot pain appear. Addressing laminitis as soon as it appears in a sick horse should always be regarded as an emergency procedure. Even then it may be too late.

Anti-endotoxin hyperimmune plasma (Equiplas. Plasvacc Pty Ltd, Kalbar Q 4309.

<http://www.plasvacc.com>) should be included in the intravenous fluid therapy for horses with, or at risk, of developing endotoxaemia. Apart from vigorously treating the primary inciting disease, attention should be paid to reducing inflammation and foot pain by administering nonsteroidal anti-inflammatory drugs (NSAIDs). Flunixin meglumine (Finadyne,) administered intravenously at 0.25 mg/kg TID or 1.1 mg/kg BID has a proven anti-endotoxin effect by reducing prostaglandin production via cyclooxygenase inhibition and is valuable. Horses receiving flunixin meglumine and subsequently dosed with endotoxin had significantly lower blood prostaglandin and lactate concentrations and reduced clinical signs than control horses. However, the effectiveness of flunixin or any NSAID as an anti-laminitis agent has never been tested. Phenylbutazone (4.4 mg/kg IV or orally every 12 hours) appears to be a potent NSAID for the control of foot pain and is popular with most clinicians. Phenylbutazone and flunixin meglumine at the lower dose rate can be used concurrently; the former to control severe foot pain and the latter to control the effects of endotoxaemia. Intravenous ketoprofen (2.2 mg/kg BID) can be used interchangeably with flunixin. Horses with acute laminitis usually require NSAID therapy for at least 2 weeks and, because of its low cost, phenylbutazone at the 2.2 mg/kg dose rate is the best choice for maintenance therapy.

However NSAIDs have been administered to horses during experimental induction of laminitis without altering the outcome - laminitis still occurs. Alarmingly, laminitis *in vitro* studies indicate that MMP activation is slightly potentiated when NSAIDs are present in the culture system. This is borne out in practice. When the laminitis process is triggered, there is virtually nothing, by way of drug therapy, that will stop its relentless progress. The administration of phenylbutazone, during the developmental/acute stages, will abolish foot pain and create a more comfortable-looking horse, but the disease continues unabated. This creates an ethical dilemma; balancing the need to alleviate pain and suffering against the realisation that most of what is administered is only palliative. When NSAIDs are in use, the patient should be confined to a stall with deep bedding. Exercise, while under the influence of painkillers, such as phenylbutazone, is contraindicated.

10.9 Vasodilator therapy

The use of vasodilatory therapy and hot water footbaths during the developmental phase of laminitis appears to be contraindicated. Drugs with vasodilator action such as isoxuprine hydrochloride, acepromazine and glyceryl trinitrate (applied as a patch to the pastern) may be beneficial after lamellar damage has occurred, when healing is required, but should be administered with caution during the developmental phase. Exercise of an intensity which raises core temperature and local anesthetic blockade of the palmar or plantar nerves both result in hoof wall heating (and by implication vasodilation) and are contraindicated during the developmental stage. In addition, horses given local anaesthetic to block foot pain, and then encouraged to walk, will almost certainly sustain greater lamellar damage than a rested, confined horse. Forced exercise to any horse with acute laminitis is strongly contraindicated.

10.10 Free radical scavengers

Dimethylsulfoxide (DMSO) may be given intravenously for its free radical scavenging and anti-inflammatory effects. DMSO (90% solution) mixed with polyionic solutions and 5% dextrose is best administered slowly at about 8 litres per hour. The concentration of DMSO must remain below 20% to avoid the risk of intravascular haemolysis. However, despite the potential of DMSO, its promise as an effective laminitis therapy has not been fulfilled. There is no evidence that ischaemia, reperfusion injury and the generation of free radicals are involved in the pathogenesis of most cases of laminitis.

10.11 A recommended treatment strategy

The list of pharmaceuticals that have been administered to horses with laminitis is long and, apart from the NSAIDs, none have achieved particular prominence. The author's recommended treatment strategy is to aggressively treat the primary disease entity, systematically addressing the problems the horse may have as proactively as possible. Fluid and electrolytes, antibiotics and NSAIDs are administered as required. Horses with septic metritis/retained placenta also require uterine lavage.

The administration of 4 litres of mineral oil four times /day may be beneficial in the case of laminitis developing from grain overload. It has a laxative effect and its presence in the large intestine is said to block the absorption of toxins. Similarly, activated charcoal is an effective adsorbent of a range of toxins and may be useful in cases of grain overload if administered promptly. In Australia, doses of 1-5 g/kg/day have been used to treat plant toxicoses in large animals. The higher dose is indicated if a large quantity of grain has been consumed. However activated charcoal has not been tested against alimentary laminitis, so its true effectiveness is unknown. The application of cold therapy to the front feet, strict confinement to a stall with a deep bedding of sand or shavings and mechanical support for the distal phalanx are also recommended.

10.12 Key Points

- Vigorous treatment of the primary inciting disease is of paramount importance.
- The diagnosis of toxæmia and septicaemia is associated with a high risk of developing laminitis and requires the initiation of medical therapy and mechanical support for the distal phalanx before the appearance of clinical signs of hoof pain.
- Inflammation and foot pain can be reduced with NSAIDs, however their effect is only palliative and will not stop the development of laminitis.
- Cryotherapy is a proven preventive for horses at risk of developing laminitis, while vasodilator therapy and forced exercise are contraindicated.
- The administration of mineral oil or activated charcoal may be beneficial in cases of laminitis developing after ingestion of excess grain.

11. Therapeutic Shoeing

11.1 Introduction

The overriding problem of laminitis is failure of the distal phalanx to remain attached to the inner hoof wall. Descent and palmar rotation of the distal phalanx, prolapse of the bone through the sole of the hoof with its attendant sepsis and osteomyelitis and, above all, severe unrelenting pain all derive from this fact. Prompt, effective mechanical support of the distal phalanx can spare weakened, separating lamellae, give them time to heal and thus improve the outcome of horses showing the early signs of laminitis. Procedures designed to support the distal phalanx, and by implication the weakened lamellae, must be instituted early if significant benefit is to be gained. The ideal time is before the appearance of foot pain or at least at its very onset. To wait for the appearance of increasing foot pain and radiographic evidence of palmar distal phalangeal displacement, before applying mechanical support, is a therapeutic opportunity lost.

11.2 Mechanical support of the distal phalanx

Significant mechanical support of an unstable distal phalanx can be achieved by the application of a frog/sole support device. Experience with a large number of cases by veterinarians and farriers, from around the world, indicates that the severity of founder is lessened if some form of frog/sole support device is applied.

11.3 Foam sole support

Foundered horses derive considerable pain relief from the application of foam digital supports. Foam digital support allows horses to bear weight on the palmar (back) two thirds of the foot. This spares the painful, dorsal (front) third of the foot, where the corium of the sole is being crushed by the descending distal phalanx. This easy, economical technique has received wide international support and is probably the best, first step to take in the rehabilitation of a foundered horse. Use foam digital support for the first few weeks. If the horse responds and stabilises clinically, then proceed to more expensive and technically demanding procedures. Foam blocks, 50-60mm thick, cut to the size of the foot, supply relief to foundered horses when taped in place over the sole. Always blue in colour, Styrofoam® has a closed, uniform cell structure and is manufactured by continuous extrusion with a non-CFC containing gas. It is used for insulation in the building industry and for flotation in pontoons and surfboards. It is chemically inert, does not rot and its closed cell structure makes it remarkably resistant to water penetration. White polystyrene foam 50-60 mm thick (H-grade), purchased from suppliers to the refrigeration industry (RMAX, see appendix 2), can be substituted for Styrofoam® although it is less suitable, because its beaded composition creates a tendency for it to split and crumble when used as a sole pad.

Creating foam sole supports for foundered horses requires two foam blocks for each foot and is a two step procedure. The first foam block is applied to the sole and taped in place with two short lengths of PVC duct tape (**Figure 11.1**). A longer length of tape is then wrapped around both the foam and the hoof and high around the heels to keep the block firmly in place (**Figure 11.2**).




Figure 11-1 Application of a foam sole support pad.

The foam is first trimmed to size and then taped to the sole of the foot using PVC duct tape. Initially 2 strips of tape, (A&B), are applied to the foam. The foam is then placed on the foot and strips A&B applied to the sides and front of the hoof. Tape is then wrapped around the foot to anchor the foam securely to the foot.



Figure 11-2 Foam sole support pad taped in place to the sole of a foundered foot.

The duct tape is wrapped high around the heels to keep the pad securely in place.

Weight-bearing by the horse over the next 24-48 hours, compresses the first foam block, creating a cast (15-20 mm thick) of the sole. This foam cast is modified by trimming away all foam that was beneath the descended, rotated solar margin of the distal phalanx . (**Figure 11.3**)

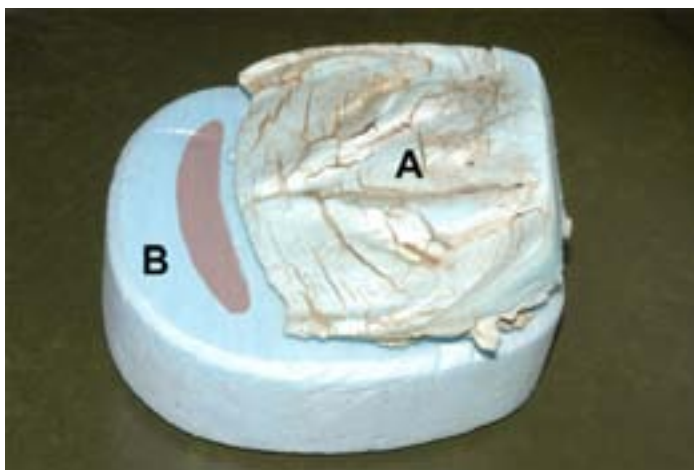


Figure 11-3 The foam sandwich that is taped together to form a laminitis sole support pad.

Weight-bearing by the horse over 24-48 hours has compressed the first foam block (A), creating a cast (15-20mm thick) of the sole. This foam cast is modified by trimming away all foam that was beneath the descended, rotated solar margin of the distal phalanx and taped to block B to form the sole support cast. The zone that should not be loaded is shown shaded.

The position of the solar margin of the distal phalanx can be determined in the field by the judicious use of hoof testers. Hoof tester pressure on the sole, over the solar margin of a distal phalanx displaced downwards by laminitis, elicits a pain withdrawal response. This spot is marked on the sole with a permanent felt marker pen. Hoof testing and marking are repeated until the marks on the sole have created a map indicating the position, under the horny sole, of the painful solar margin of the distal phalanx. This is the zone that must receive no pressure from the foam sole cast. Foam that would apply pressure is trimmed away. Hoof tester pressure on the sole palmar (behind) to the solar margin causes significantly less pain (or no pain in some cases) and it is this part of the sole (and frog) that can support weight.

The second step of the procedure is the taping to the foot, of a second foam block (similar in dimensions to the first), over the top of the first. This will compress as well and the resultant foam sandwich is taped together and left taped in place. Foam pads can be replaced or modified as governed by the response of the horse. They last several days if the environment of the horse does not damage the foam. Ideally the horse should be confined to stables covered with deep shavings or sand.

11.4 The Steward Clog

Mike Steward, a veterinarian based in Oklahoma, USA, introduced a cheap, effective, rolled-toe, rolled-heel, wooden shoe for foundered horses (Steward 2003). Easily made and fitted from readily available components the shoe requires no nailing and brings relief to the majority of foundered horses (Figure 1-1 The gait of a horse with severe laminitis.)

Figure 11-4). Impression material (Coltene Lab-Putty, see appendix 2) is mixed and applied to the sole, bars and frog of the cleaned, foundered foot (Figure 11-5). Before the impression material cures the clog is quickly taped in place and the foot placed on the ground and allowed to bear weight. This compresses the lab putty evenly and creates a firm, silicone rubber cast supporting the palmar/plantar (back) half of the foot.

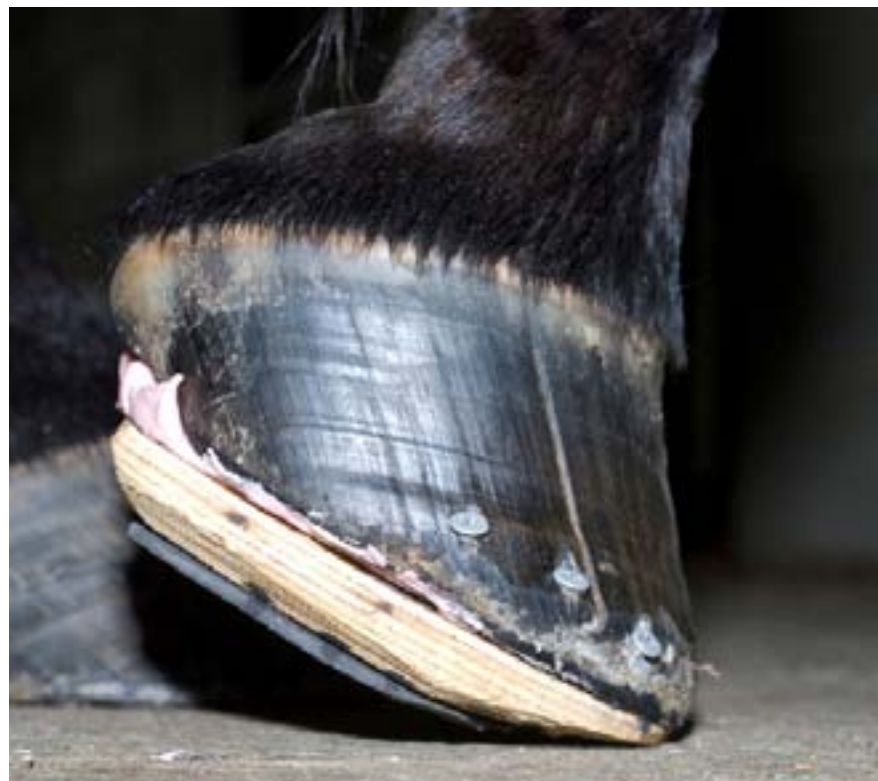

Figure 11-4 A home made wooden version of the Steward Clog.
The plywood was shaped with a jig-saw and attached with screws (Chipboard screws 8G x 30-40mm). The front of the clog has been bevelled with a rasp to provide easy break-over. Between the sole of the hoof and the plywood clog is silicone impression putty (Coltene Lab Putty-see appendix 2).



Figure 11-5 The two components of Coltene lab putty (appendix 2), a silicone dental impression material, are thoroughly mixed and while still soft applied to the cleaned sole.

The bulk of the putty is applied to the heels, bars and frog (avoiding the toe) where support can be safely applied without loading the more painful dorsal (front) half of the foot.

The clog is then removed and the cured rubber cast is trimmed, removing any material that may exert pressure to the sole beneath the rotated solar margin of the distal phalanx (Figure 11-13). In severe cases where the distal phalanx has sunk and rotated downwards and caused the sole to bulge downwards (dropped sole) it is important to sand out a cavity in the plywood to accommodate the bulge to avoid painful pressure (Figure 11-6).



Figure 11-6 The clog showing the surface depression created to accommodate a dropped sole.

A pattern was made by placing the foot on a sheet of plywood and drawing around the perimeter of the hoof with a marker pen. The clog was cut from the plywood with a jig-saw and the edges bevelled with a sanding disc attached to an angle grinder. The sanding disc was used to create the surface depression

In cases where the distal phalanx has rotated significantly the insertion of a 2⁰-3⁰ wedge pad between the heels and the shoe will raise the heels and may bring added relief. With the foot weight bearing holes, of similar diameter to the screws, are drilled through the outer hoof wall and into the plywood. The pattern of screw placement is similar to a nailed-on shoe taking extra care at the heels where the wall is thinner. Next the hoof is screwed down (Chipboard screws 8G x 30-40mm) to the wooden clog taking care not to exert excessive pressure by over tightening. An advantage of the Steward Clog is that the pain of nailing is absent and shoeing can proceed with all four feet on the ground. Foundered horses suffer added pain when one foot is held off the ground for long periods so being able to attach a support shoe while the feet are on the ground is an advantage. The use of a cordless drill speeds application time. Wrapping fibreglass casting material (DynaCast Extra or Scotchcast Plus, 100mm wide, code: 4793 from www.sportstek.net/) around the perimeter of the distal hoof and the shoe confers extra durability and longevity. Attaching rubber to the sole of the shoe also extends the life of the shoe. Plastic Steward Clogs, in 4 standard sizes, are available in kit form from EDSS Inc. www.edsshooftcare.com/.

11.5 Digital support shoes

To date only properly designed, digital support shoes, firmly attached to the hoof wall, have satisfactorily stabilised the distal phalanx, supported the damaged lamellae and protected the sole from injury when it makes contact with the ground. Taped-on foam sole supports and frog pads, are useful temporary measures, until digital support shoes can be applied.

11.6 The heart-bar shoe (HBS)

The use of the HBS in the treatment of foundered horses is the rediscovery of a 19th century frog plate shoe used on the forefeet of harness horses experiencing excessive road trauma. A description of the shoe can be found in Dollar and Wheatley's (1898) Handbook of Horseshoeing (Dollar JAW and Wheatley A: A Handbook of Horseshoeing. D Douglas, Edinburgh 1898: pp 352-353. Facsimile edition 1993: Centaur Forge Ltd., Burlington, Wisconsin, USA). J.A.W. Dollar was a member of the Royal College of Veterinary Surgeons based in London.

The regular therapeutic use of the HBS on foundered horses began in 1968 when Burney Chapman and Dr George Platt, a farrier/veterinarian combination from Texas, USA, realised that the frog could be recruited to share, along with the hoof wall, a substantial proportion of the normal weight bearing load without being damaged and without causing additional discomfort to the horse. The frog is not normally involved in significant load sharing when the foot makes ground contact. However, to Chapman and Platt, stabilization of the distal phalanx and support of the skeletal axis of the limb appeared necessary, to limit the mechanical destruction of the foundered foot. A correctly applied heart-bar shoe loads the palmar (back) structures of the foot, shifts the weight bearing load away from the toe, thus sparing the dorsal (front) structures of the foot. When non-surgical, dorsal hoof wall resection was combined with the use of the HBS the recovery rate and the speed of effective hoof wall regeneration in selected cases increased. The combined procedure appears to release the coronary band from the pressure of the dislocated distal phalanx and provides drainage for infected lamellae if sepsis has developed beneath the dorsal hoof wall. The epidermal lamellae beneath the dorsal hoof wall of a chronically foundered horse proliferate unnaturally to form a wedge of material (the lamellar wedge) which physically prevents the hoof wall from re-establishing effective attachments to the distal phalanx. Nonsurgical dorsal hoof wall resection and removal of the lamellar wedge, in selected cases (those where lamellar separation is confined to the toe), often results in improved alignment of hoof wall and distal phalanx as a "new" hoof wall grows down from the hair line. The procedure requires monthly re-setting of the heart-bar shoes and removal of any lamellar wedge that may return. Foundered horses treated early are sometimes able to return to previous performance levels. On the other hand foundered horses treated late, can be made pasture sound and able to return to stud duties. Some horses, especially "sinkers", fail to respond, and should be euthanased on humane grounds.

The widespread international use of the HBS and the need for veterinarians and farriers to work cooperatively together on cases of laminitis has caused a resurgence in the art of farriery. Many

modern equine practices retain a specialist farrier on either a part-time or full-time basis. The use of the heart-bar shoe has enabled veterinarians and farriers to rehabilitate and salvage many horses and ponies that, previous to its introduction, would have been lost.

11.7 Construction of the heart-bar shoe

Factory made heart-bar shoes are readily available in a range of sizes and with the aid of a forge can be shaped to fit most horses. For ponies and the giant breeds, or if a prefabricated HBS cannot be obtained, a HBS can be custom forged by a farrier.

The frog support plate of the shoe must be adjusted so that when fitted the shoe applies even, mild pressure over the entire length of the frog. The shape and depth of the frog varies between horses and sometimes the frog has to be trimmed and shaped so that it makes even contact with the frog support plate of the HBS. The tip of the frog plate should not be angled upwards; it should instead be parallel to and 2-3 mm above the level of the adjacent branches of the shoe (**Figure 11.4**). The toe of the shoe should be square and forged to resemble the tip of a snow ski. The break-over point of the shoe should be beneath the tip of distal phalanx.



Figure 11-7 The heart-bar shoe. Factory made heart-bar shoes are readily available in a range of sizes and can be shaped to fit most horses. As supplied, the shoe is flat and must be adjusted so that the frog plate (F) is “set up” above the level of the branches of the shoe. The frog plate should be parallel to and 2-3 mm above the level of the adjacent branches of the shoe. The frog support plate of the shoe should apply even pressure over the entire length of the frog. Rolling the toe of the shoe (arrowed), eases breakover of the foot during locomotion, and relieves tension on lamellae weakened by laminitis.

Moving the break-over fulcrum under the tip of the distal phalanx shortens the lever arm of the toe and reduces the shearing stress on the dorsal lamellae. No part of the shoe must encroach on the sole or bars. For the horse with minimal displacement of the distal phalanx, the shoe can be fixed in place with the tip of the frog bar covering all but 10-15 mm of the tip of the frog. In all other cases it is dangerous to apply a HBS without knowledge of the position of the distal phalanx within the hoof capsule. In other words the HBS is fitted to the distal phalanx, not the external hoof. The position of the distal phalanx within the hoof capsule can only be determined with radiographs. Radiography and fitting the HBS to a foundered foot go together and necessitate vet/farrier co-operation.

A radiopaque marker such as a drawing pin or thumb-tack placed in the apex of the frog is used to transfer the measurements from the radiograph to the foot and the shoe. The tip of the frog plate of the HBS should be positioned on the frog, beneath the insertion of the deep flexor tendon on the palmar distal phalanx. This point can be located on the lateral to medial radiograph by measuring the distance between the tip of the distal phalanx and the extremities of the superimposed lateral and medial palmar processes (**Figure 11.5**).

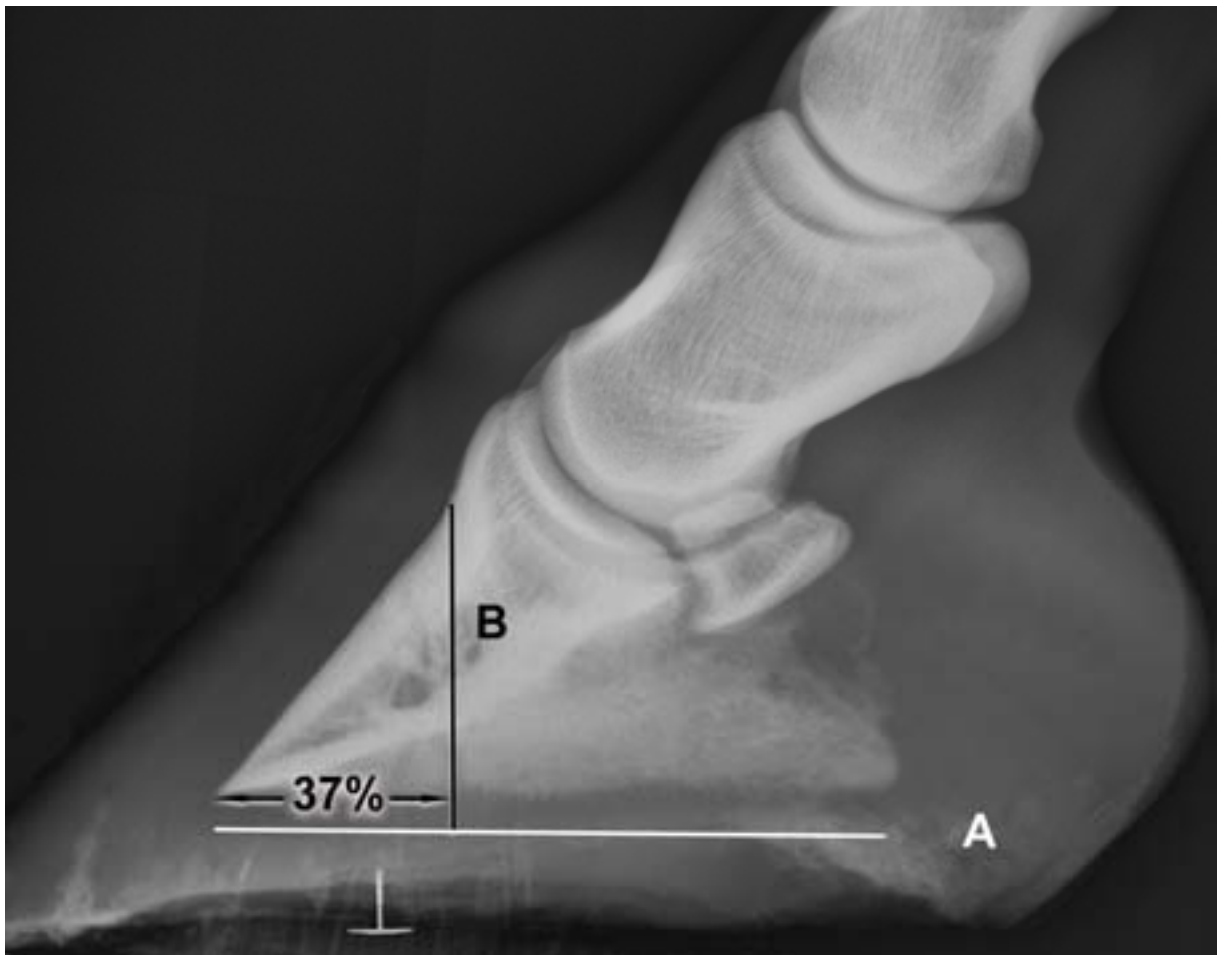

Figure 11-8 Fitting the heart-bar shoe (A).

When laminitis causes the position of the distal phalanx within the foot to alter, it becomes important that the heart-bar shoe is made and fitted with reference to the internal structures of the foot. If the frog plate of the shoe is too far forward (i.e. more dorsal than the insertion of the deep flexor tendon) an increase in lameness will result. The construction of the shoe and the placement of the frog plate should be determined with reference to radiographs whenever possible (particularly in long-standing cases). A radiopaque marker such as a drawing pin placed in the apex of the frog is used to transfer the measurements from the radiograph to the foot and the shoe. The tip of the frog plate of the HBS should be positioned on the frog, beneath the insertion of the deep flexor tendon on the palmar distal phalanx. This point can be located on a true latero-medial radiograph by measuring the distance (line A) between the tip of the distal phalanx and the extremities of the superimposed lateral and medial palmar processes. The correct location for the tip of the frog plate is 37% of this distance palmar to (back from) the tip of the distal phalanx. Alternatively the same point can be located by dropping a line (line B) from the base of the extensor process, perpendicular to the outline of the solar margin. Reference to the radiopaque marker allows the correct location of the point transposed from the radiograph to the shoe and the horse's foot.

Alternatively the same point can be located by dropping a line from the base of the extensor process, perpendicular to the outline of the solar margin. Reference to the radiopaque marker allows the correct location of the point to be transposed from the radiograph to the horse's foot (**Figure 11.6**). It

is vital that positioning of the foot, x-ray beam and film is correct to ensure a true lateromedial projection. The position of the distal phalanx, within a hoof capsule affected by laminitis, may shift dramatically so fitting the HBS with reference to the bone, using a radiograph, is important. The principle behind the application of a heart-bar shoe is that lamellar separation and tearing can be limited by the application of a counterforce, exerted by the unyielding frog plate of the shoe, on the palmar distal phalanx via the digital cushion and the resilient frog.

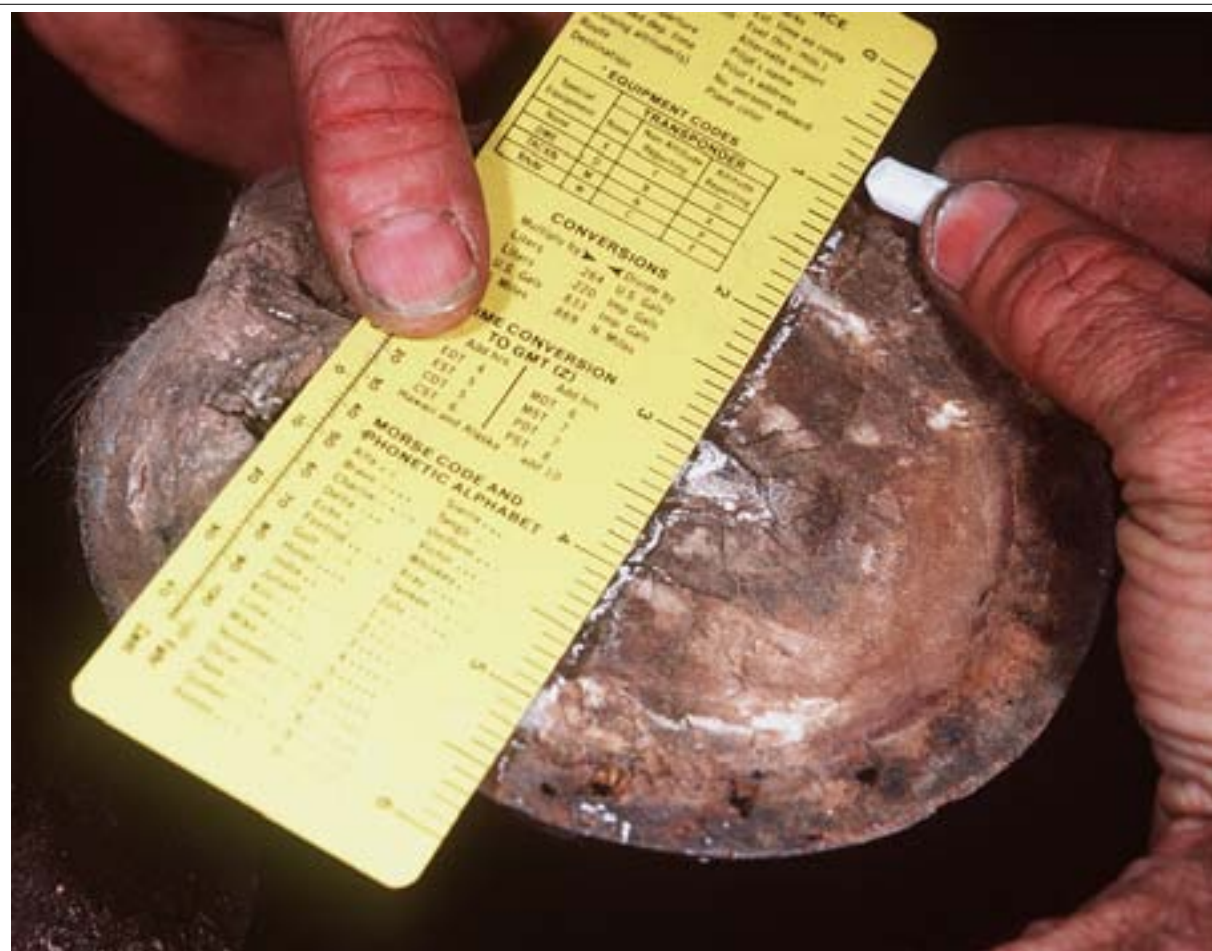

Figure 11-9 Fitting the heart-bar shoe (B).

Reference to the position of the drawing pin on the radiograph allows the measurement of the correct position for the tip of the frog plate to be transferred to the under surface of the hoof.

11.8 Heel elevation

Although the weight of the horse, transferred through the limb skeleton to the distal phalanx, is considered to be the primary force causing progressive separation of compromised lamellae, additional separation appears to be caused by the rotary force exerted by contraction of the deep digital flexor muscle via the palmar insertion of its tendon (the deep flexor tendon) to the palmar distal phalanx. Raising the heels of feet affected by acute laminitis by 12-18 degrees, is claimed to decrease the biomechanical tension in the deep flexor tendon by 50-60%, arrest further dislocation of diseased lamellae and to reduce pain. Wedges for elevating the heels of horses are available commercially (see appendix 1). If the initial radiographs show no palmar rotation of the distal phalanx heel elevation can proceed immediately. If rotation of the distal phalanx is present the hoof should be trimmed to normalise the position of the distal phalanx, in relation to the hoof capsule, (de-rotated) before heel elevation is performed. Strict rest in a stall with deep bedding is mandatory when using heel wedges. The wedge is removed 10-15 days after the signs of laminitis have disappeared (without analgesia). The principle of temporary heel elevation is that lamellar distraction can be prevented, or at least ameliorated, if the force exerted on the distal phalanx by the deep flexor tendon is neutralised.

11.9 The Equine Digit Support System

Gene Ovnicek, a farrier originally from Columbia Falls, Montana, USA, developed the **Natural Balance Shoe™** in conjunction with a system of pads, heel wedges, frog inserts and silicone impression material (known as the Equine Digit Support System or EDSS) specifically for the rehabilitation of foundered horses. The system is marketed as a kit and can be purchased from the comprehensive website (www.edsshoofcare.com)




Figure 11-10 *The Equine Digital Support System.*

Components of the system are the Natural Balance Shoe (A), a plastic pad with a built-in frog plate (B), additional frog inserts (C) and wedge rails (D). The plastic pad can be screwed to the shoe firmly via the pre-drilled and tapped in the toe of the shoe (arrowed). Frog support can be increased by the addition of frog inserts of various sizes. The holes and pegs in the branches of the shoe are for accurate and secure placement of the wedge rails.

The EDSS shoe is a version of the **Natural Balance Shoe™** with predrilled and tapped holes for the attachment of other components of the EDSS (**Figure 11.7**). The hole at the toe is used to attach the EDSS pad while the holes on the shoe branches are for the attachment of heel elevation wedges or “wedge rails”. This ingenious system of interchangeable parts allows adjustments of heel height to be made without removal of the shoe. The shoe has a rolled, square toe, designed to promote easy break-over during locomotion, thus limiting further mechanical separation and tearing of damaged lamellae. A plastic pad with a stainless steel insert embedded into its toe is used in conjunction with the **Natural Balance Shoe™**. When screwed firmly into place (in the pre-drilled toe hole) the pad conforms to the seated-out design of the shoe and frog support is provided by a built-in frog plate. Frog support can be added to by attaching one of a range of different sized, plastic frog inserts. The amount of heel elevation can be adjusted by attaching a pair of “wedge rails” to the shoe utilising the predrilled holes in the shoe and pegs and holes in the plastic rails.

EDSS styrofoam pads are part of the kit and are recommended for horses in the early stages of acute laminitis. When the horse has stabilised clinically (this may take 2- 3 weeks), support of the foundered feet can progress from foam pad support to a shoe based system. Completing the system is a two-part silicone based impression material that, when blended together, cures into a rubber-like consistency. A cast of the bottom of the foot is made by placing the freshly blended impression material over the sole, bars and frog. The impression material is then covered with a hard rigid pad that is quickly taped to the foot. The horse is made to stand on the pad while the impression material cures. The rubber cast is then trimmed so that only the back part of the foot (the palmar sole, frog and bars) is used for support. There should be no contact between impression material or any part of the pad with the painful, descended, corium beneath the solar margin of the distal phalanx. Correct foot trimming is essential if the EDSS is to achieve its potential.

A detailed instructional video is available and it is highly recommended that this be studied prior to using the EDSS. The heels of the foundered foot are trimmed so that a bearing surface is created, adjacent to the widest part of the frog (**Figure 11.8**). Lateral radiographs assist in visualising the new altered position of the distal phalanx. The foot is shod to accommodate the new position of the distal phalanx and for the time being the toe can be ignored. After selection of the appropriate shoe, pad, frog inserts and wedge rails, a supportive sole cast is made with the impression material.

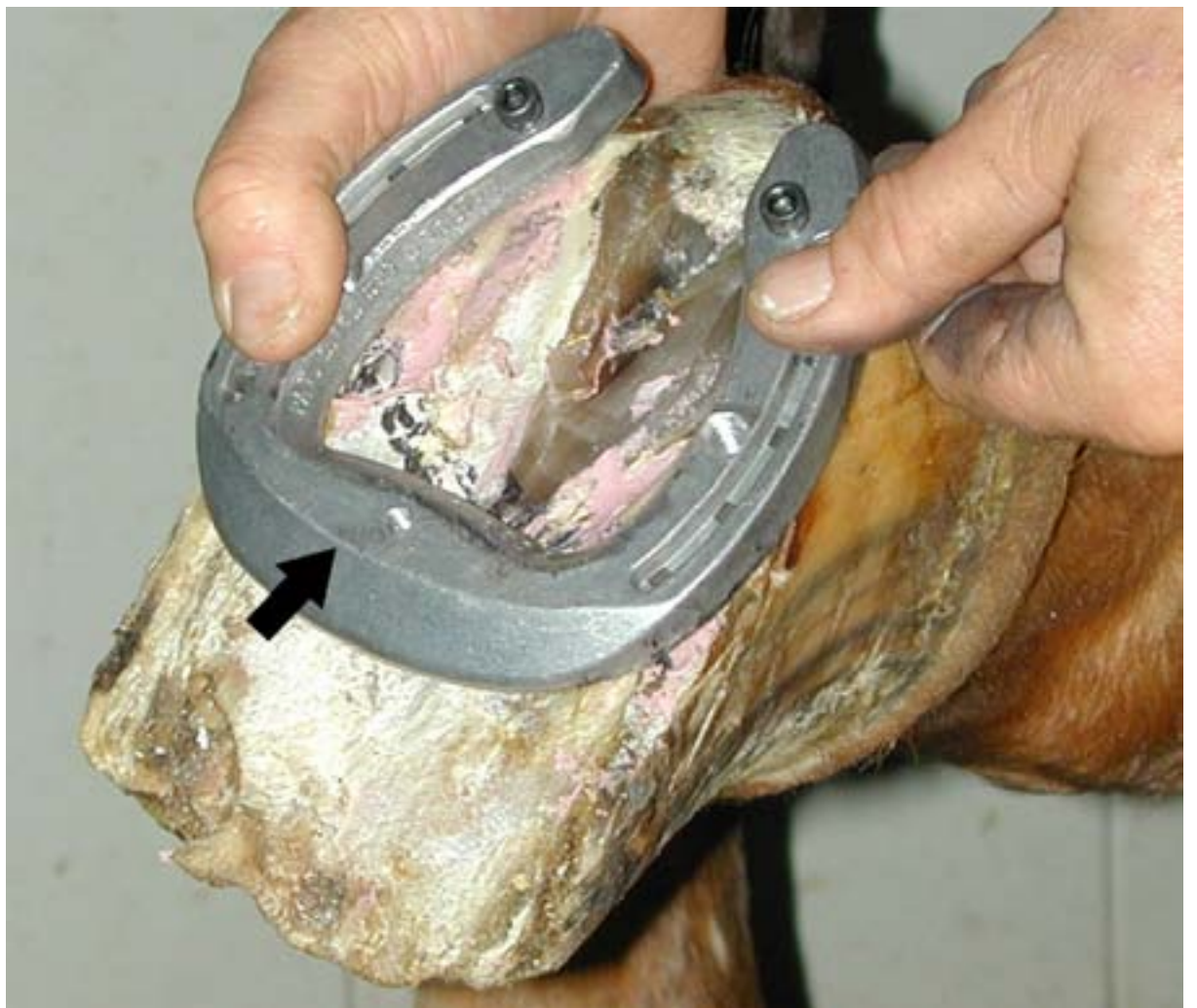

Figure 11-11 Fitting the EDSS Natural Balance Shoe.

When fitting the shoe the heels are trimmed to the widest part of the frog. Lateral radiographs assist in visualising the distal phalanx within the foot. The foot is shod to accommodate the new, altered, position of the distal phalanx. The point of break-over of the shoe (arrowed) should be aligned beneath the tip of the distal phalanx to minimise further separation of weakened lamellae.

After appropriate trimming, the silicone rubber sole cast is fitted to the foot and the assembled shoe is nailed in place. If nailing is too painful for the horse, a shoe with aluminium tabs is available, that can be attached with special hoof adhesives (eg. Equilox, Flex n Bond, see appendix 1 for suppliers). After the horse is shod the degree of comfort provided by the system should be assessed. Adjustments to the amount of frog support and the height of the heels can be made by selection of different sized components. The responses of the horse can be used to select the EDSS configuration that provides the most comfortable support.

11.10 Heart-bar support shoe

A shoe combining the principles of the heart-bar, heel elevation, a support pad and silicone rubber impression material has been developed by the veterinarian Dr Lionel Richards and farrier Craig Jones of Brisbane, Queensland. The shoe is hand forged from a single length of aluminium bar stock 1/2 inch in thickness, 3/4 inch in width. The base of the frog plate is welded to the heel of the shoe in the forge and the branches of the shoe are fullered and punched. The frog plate is kept level with the branches of the shoe. The toe of the 1/2 inch thick aluminium is easily forged and rasped into a ski-tipped shape to provide ease of breakover (**Figure 11.9**).



Figure 11-12 Hand forged heart-bar support shoe.

The toe of the shoe has been rolled and the ease of break-over is being demonstrated. Triangular shaped rails have been bolted to the underside of the shoe to provide heel elevation (Shoe forged by Craig Jones of Brisbane, Queensland).

A leather pad is cut and riveted to the shoe. Impression material (Coltene Lab-Putty, see appendix 2) is mixed and applied to the sole, bars and frog of the foundered foot. Before the impression material cures the shoe is taped or temporarily nailed to the foot (using just 2 nails at this stage) so that weight-bearing by the horse, compresses the lab putty, thus creating a silicone rubber support cast (**Figure 11.10**). The shoe is then removed and the cured rubber cast is trimmed, removing any material that may exert pressure to the sole beneath the rotated solar margin of the distal phalanx. The heels can be elevated by bolting triangular shaped aluminium rails to the base of the shoe. The shoe is fitted and the hoof trimmed in accordance with the anatomical principles outlined previously. The combination heart-bar support shoe utilises the excellent shock-absorbing qualities of aluminium, leather and silicone rubber and is being used by a growing number of vet-farrier teams.



Figure 11-13 Silicone rubber cast of the palmar sole, bars and frog.

Used in conjunction with special shoes and pads silicone rubber casts spread the task of load-bearing over the entire palmar half of a foundered foot.

11.11 Hoof wall resection

Early resection of the hoof wall in a zone corresponding to the in-growing coronet and toe (Figure 11.11) of chronic laminitis appears to release compression of the tissues beneath and, depending on the extent of the soft tissue and bone pathology, restore a semblance of normal hoof growth (Figure 11.12).

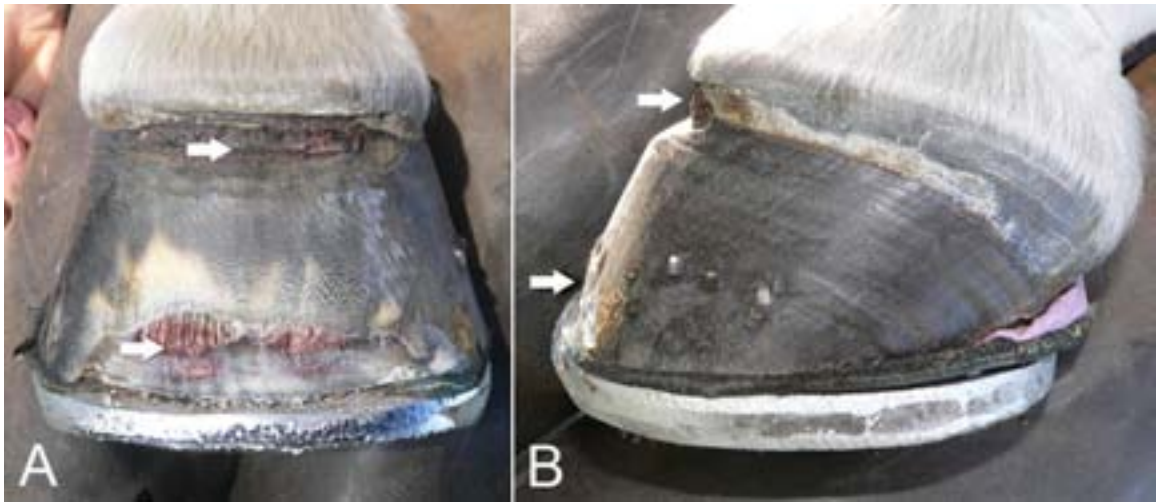


Figure 11-14 Hoof resection of the coronet and distal toe.

Improved growth of hooves affected by chronic laminitis occurs after resection of the in-growing coronet and toe. Dorsal and lateral views of the 2 cm wide groove below the coronet and the resection of the distal toe are shown in A and B respectively. The shoe is a custom made aluminium heart-bar, with a leather pad and silicone palmar sole support fitted with reference to radiographic measurements. Shoe forged and fitted by Richard Hanson. Hansen Forge Pty Ltd., Samford, Queensland. www.hansenforge.com.au

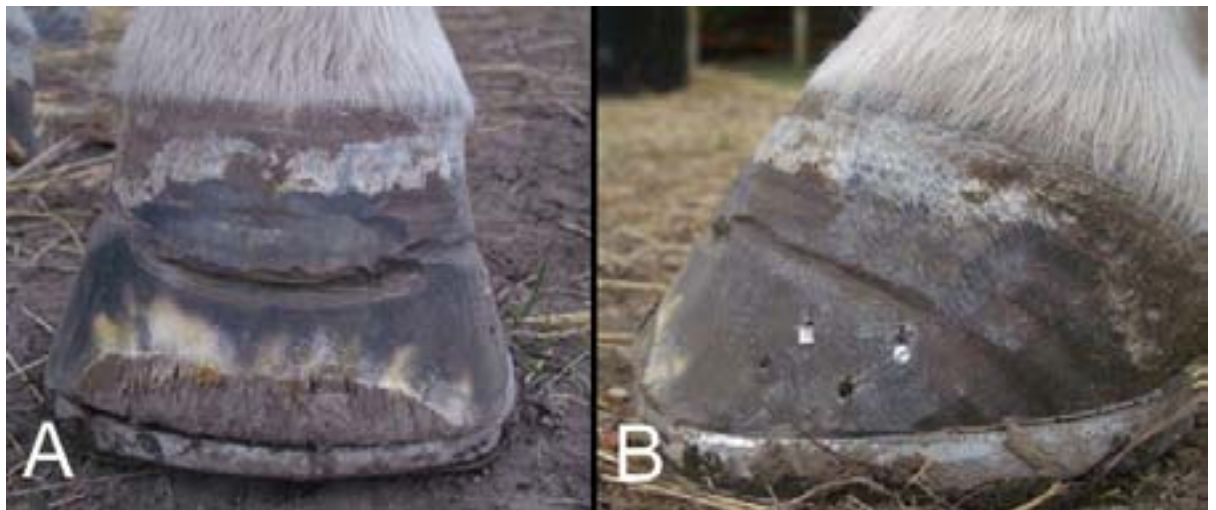

Figure 11-15 Foot of the same horse in Fig 11.11 10 weeks after coronary band and toe hoof resection.

Dorsal and lateral views are shown in A and B respectively. The procedure appears to have restored parallel hoof growth below the hair line of the coronet. The horse's gait and demeanour was concomitantly improved.

11.12 Deep flexor tenotomy

If, despite the initial therapy, the distal phalanx continues to rotate and descend into the hoof capsule and pain is ever present, the option of deep flexor tenotomy can be considered. The aim of the operation is to remove the disto-palmar force exerted on the distal phalanx by the deep flexor tendon. The surgery is best performed at the mid-metacarpus, under local anaesthesia, with the horse in the standing position, deeply sedated with xylazine or a combination of xylazine and butorphanol. After surgery is complete, the legs should be kept bandaged and the horse confined to a stall for 6-8 weeks. The hoof should be trimmed to place the distal phalanx in a normal position within the hoof capsule. Most horses show an initial clinical improvement. This supports the hypothesis that the unopposed palmar tension exerted by the deep flexor tendon on the distal phalanx contributes to the pain of chronic refractory laminitis. If tenotomy is performed before there is significant osteolysis of the distal phalanx, most horses recover slowly. However clinical improvement is sometimes short lived and many horses require euthanasia within 12 months of surgery. The prognosis is poor if osteolysis and abscessation of the distal phalanx develop.

11.13 Key Points

- Effective mechanical support, using frog/sole support devices, should be provided early to a horse developing laminitis to improve the outcome of the disease. Frog/sole support devices can be taped to the foot to temporarily support the distal phalanx until digital support shoes are applied.
- The heart-bar shoe stabilises the distal phalanx, supports the damaged lamellae and loads the palmar structures of the foot to shift the weight bearing function back from the toe. Cooperative liaison between veterinarian and farrier is required for correct application of this shoe.
- Raising the heels of feet affected by acute laminitis using wedges reduces the force exerted on the distal phalanx by the deep flexor tendon, and therefore ameliorates further lamellar separation and reduces pain.
- The Steward Clog and the Equine Digit Support System are commercially available systems of interchangeable parts that allow attachment of support pads and elevation wedges to a specially designed shoe using predrilled holes. A supportive sole cast, made using a two-part silicone based impression material, provides additional support to the back part of the foot.
- An aluminium heart bar shoe, to which a leather support pad, silicone rubber support cast and elevating aluminium rails can be added, is an alternative therapeutical support shoe.
- Strategic proximal and distal toe hoof wall resection improves the abnormal hoof growth due to chronic laminitis.

12. Prognosis and Future Directions

Some horses that show the clinical signs of acute laminitis recover completely if treated promptly using a combination of rational medical therapy and mechanical support. However, horses recovering from even the mildest laminitis should be rested and observed closely. If no radiographic evidence of palmar displacement of the distal phalanx within the hoof capsule exists, and the digital pulse is not palpably exaggerated 48 hours after treatment has ceased, the horse can be cautiously returned to its usual function.

If radiographs do show displacement of the distal phalanx, then the prognosis must be more guarded. Horses with a mild increase in the distance between the distal phalanx and the dorsal hoof wall, with or without rotation of the distal phalanx, often make an apparent recovery and remain sound indefinitely. However, horses with marginally greater displacement and rotation of the distal phalanx make only partial recoveries and often have a history of intermittent lameness, especially after exercise. Histopathology of the hoof lamellae at the early chronic stage shows a reduction in the number of functional secondary epidermal lamellae. Many of the SELs had distorted, abnormal shapes even several years after the initial episode of laminitis. Some SELs become isolated from their attachment to the PEL and exist as isolated, unattached islands (pearls) adrift in the lamellar connective tissue. If the surface area of the lamellae of the inner hoof wall is reduced after laminitis, the effectiveness of the lamellar distal phalanx suspensory mechanism must also be reduced. In other words, horses developing laminitis associated with significant initial lamellar destruction, as manifest by radiographic displacement of the distal phalanx and venographic evidence of vascular compromise, appear never to make a complete anatomical recovery and are prone to recurrent episodes of foot pain.

Inward growing tubular hoof at the coronet and toe adds an additional layer of complexity to dealing with severe chronic laminitis. The problem is best diagnosed by the detection of venous filling defects using sequential venography. Fortunately judicious resection of the proximal and distal hoof, overlying the in-growing zones, restores hoof growth to partial normality. If neglected, in-growing tubular hoof contributes the rotation and pathological lysis of the distal phalanx.

Ultimately, the prognosis is directly proportional to the severity and extent of lamellar pathology. Horses with more than 15 degrees of rotation, accompanied by downward displacement of the distal phalanx into the hoof capsule within 4-6 weeks of the initial episode of laminitis, have a poor prognosis. Prolapse of the distal phalanx through an already necrotic sole, accompanied by subsolar and sublamellar infection, usually occurs. Pus will discharge from the coronet and the heels. Osteomyelitis and lysis of the distal margin of the distal phalanx will develop. Such cases will require months of expensive supportive care and surgery and although the occasional horse does make a surprisingly good recovery, most suffer months of crippling foot pain and recumbency, and eventually require euthanasia on humane grounds.

If the horse is clearly more mobile and comfortable after shoeing, this is a sign that the chosen therapeutic technique is working. Over time, the red, necrotic solar corium, beneath the displaced tip of the distal phalanx, will re-epithelialise; turning light yellow in colour as new horn cells colonise the damaged area. The reappearance of thick, concave sole is an encouraging development. A return of hoof growth parallel to the coronary band especially at the front of the foot is also encouraging. Many horses recover to be sound enough for breeding purposes or paddock retirement. They will however require prolonged aftercare in the form of frequent, expert shoeing and perhaps confinement to a personal yard. A few return to former athletic soundness.

12.1 Future Directions

At the AELRU the search for the fundamental causes of laminitis continues. Using advanced biochemical and molecular biological techniques we continue to thoroughly investigate the link between bacterial overgrowth in the horse's bowel (particularly that induced by the key pasture carbohydrate fructan) and events occurring at the basement membrane of the hoof lamellae. The real hope for horses as they confront their crippling adversary, laminitis, is a means to effectively prevent it. Once the devastating pathological cascade of laminitis is underway, the anatomical dislocations are so overwhelming that there is little hope that mankind will develop technology to be able restore a foundered foot to normal. When the reason behind the failure of a normally robust, trouble-free attachment apparatus between hoof and bone are understood, the way to develop effective preventive strategies will be clear.

12.2 Key Points

- Recovery from laminitis is unpredictable, but generally the prognosis is directly proportional to the extent of displacement of the distal phalanx and the resultant lamellar pathology that occurs.
- The return to a normal-looking hoof takes time and prolonged aftercare will often be required. Few horses return to their former athletic soundness after chronic laminitis.
- Research at the AELRU is devoted to discovering the mechanism by which the basement membrane and lamellae separate, because prevention of this terrible disease represents a better option than trying to repair the gross anatomical dislocations once they have occurred.

13. References

- Asplin, K., Sillence, M., Pollitt, C. and McGowan, C.M. (2007) Induction of laminitis by prolonged hyperinsulinaemia in clinically normal ponies. *Vet J* **174**, 530-535.
- Baldwin, G.I. and Pollitt, C.C. (2000) Retrograde venous angiography (venography) of the equine digit during experimentally induced laminitis. In: *The third international equine conference on laminitis and diseases of the foot.*, West Palm Beach, Florida, USA.
- Black, S.J., Lunn, D.P., Yin, C., Hwang, M., Lenz, S.D. and Belknap, J.K. (2006) Leukocyte emigration in the early stages of laminitis. *Vet Immunol Immunopathol* **109**, 161-166.
- Coffman, J.R., Johnson, J.H., Guffy, M.M. and Finocchio, E.J. (1970) Hoof circulation in equine laminitis. *J Am Vet Med Assoc* **156**, 76-83.
- Coyne, M.J., Cousin, H., Loftus, J.P., Johnson, P.J., Belknap, J.K., Gradil, C.M., Black, S.J. and Alfandari, D. (2008) Cloning and expression of ADAM related metalloproteases in Equine Laminitis. *J. vet. Immunol. (in press)*.
- Croser, E.L. and Pollitt, C.C. (2006) Acute laminitis: descriptive evaluation of serial hoof biopsies. In: *52nd Annual Convention of the American Association of Equine Practitioners*, San Antonio, Texas, USA.
- Daradka, M. and Pollitt, C.C. (2004) Epidermal cell proliferation in the equine hoof wall. *Equine Vet J* **36**, 236-241.
- French, K.R. and Pollitt, C.C. (2004a) Equine laminitis: cleavage of laminin5 (L5) associated with basement membrane dysadhesion. *Equine vet. J.* **36**, 242-247.
- French, K.R. and Pollitt, C.C. (2004b) Equine laminitis: loss of hemidesmosomes in hoof secondary epidermal lamellae correlates to dose in an oligofructose induction model. *Equine vet. J.* **36**, 230-235.
- Hood, D.M., Amoss, M.S., Hightower, D., McDonald, D.R., McGrath, J.P., McMullan, W.C. and Scrutchfield, W.L. (1978) Equine Laminitis 1: Radioisotopic analysis of the haemodynamics of the foot during the acute disease. *J. equine Med. Surg.* **2**, 439-444.
- Johnson, P.J. (2002) The equine metabolic syndrome peripheral Cushing's syndrome. *Vet Clin North Am Equine Pract* **18**, 271-293.
- Johnson, P.J., Tyagi, S.C., Katwa, L.C., Ganjam, V.K., Moore, L.A., Kreeger, J.M. and Messer, N.T. (1998) Activation of extracellular matrix metalloproteinases in equine laminitis. *Vet Rec* **142**, 392-396.
- Kyaw-Tanner, M. and Pollitt, C.C. (2004) Equine laminitis: increased transcription of matrix metalloproteinase-2 (MMP-2) occurs during the developmental phase. *Equine vet. J.* **36**, 221-225.
- Longland, A.C. and Byrde, B.M. (2006) Pasture nonstructural carbohydrates and equine laminitis. *J. Nutr.* **136**, 2099S-2102S.
- McGowan, C., Frost, R., Pfeiffer, D. and Neiger, R. (2004a) Serum insulin concentrations in horses with equine Cushing's syndrome: response to a cortisol inhibitor and prognostic value. *Equine Vet J.* **36**, 194-198.

- McGowan, C.M., Frost, R., Pfeiffer, D.U. and Neiger, R. (2004b) Serum insulin concentrations in horses with equine Cushing's syndrome: response to a cortisol inhibitor and prognostic value. *Equine Veterinary Journal* **36**, 295-298.
- Milinovich, G.J., Trott, D., Burrell, P.C., Croser, E.L., Al Jassim, R.A.M., Morton, J.K., van Eps, A.M. and Pollitt, C.C. (2007) Fluorescence in situ hybridization analysis of hindgut bacteria associated with the development of equine laminitis. *Environmental Microbiology* doi:10.1111/j.1462-2920.2007.01327.x.
- Milinovich, G.J., Trott, D.J., Burrell, P.C., vanEps, A.W., Thoenner, M.B., Blackall, L.L., AlJassim, R.A.M., Morton, J.M. and Pollitt, C.C. (2006) Changes in equine hindgut bacterial populations during oligofructose induced laminitis. *Environ. Microbiol.* **8**, 885-898.
- Mungall, B.A., Kyaw-Tanner, M. and Pollitt, C.C. (2001) In vitro evidence for a bacterial pathogenesis of equine laminitis. *Vet Microbiol* **79**, 209-223.
- Mungall, B.A. and Pollitt, C.C. (1999) Zymographic analysis of equine laminitis. *Histochem Cell Biol* **112**, 467-472.
- Nourian, A.R., Baldwin, G.I., van Eps, A.W. and Pollitt, C.C. (2007) Equine laminitis: ultrastructural lesions detected 24-30 hours after induction with oligofructose. *Equine vet. J.* doi: 10.2746/042516407X177448
- Obel, N. (1948) *Studies of the Histopathology of Acute Laminitis.*, Almqvist and Wilcsells Bottrykeri Ab Uppsala (Thesis).
- Pollitt, C.C. (1992) Clinical anatomy and physiology of the normal equine foot. *Equine Vet. Ed.* **4**, 219-224.
- Pollitt, C.C. (1994) The basement membrane at the equine hoof dermal epidermal junction. *Equine Vet J* **26**, 399-407.
- Pollitt, C.C. (1995) *The Horse's Foot*, Mosby-Wolfe, London.
- Pollitt, C.C. (1996) Basement membrane pathology: a feature of acute equine laminitis. *Equine Vet J* **28**, 38-46.
- Pollitt, C.C. (1998) The anatomy and physiology of the hoof wall. *Equine Vet Education* **10**, 318-325.
- Pollitt, C.C. (2004) Anatomy and physiology of the hoof wall. *Clinical Techniques in Equine Practice.* **4**, 3-21.
- Pollitt, C.C. and Daradka, M. (1998) Equine laminitis basement membrane pathology: loss of type IV collagen, type VII collagen and laminin immunostaining. *Equine Veterinary Journal Supplement.* **26**, 139-144.
- Pollitt, C.C. and Davies, C.T. (1998) Equine laminitis: its development coincides with increased sublamellar blood flow. *Equine Veterinary Journal Supplement* **26**, 125-132.
- Pollitt, C.C., Pass, M.A. and Pollitt, S. (1998) Batimastat (BB-94) inhibits matrix metalloproteinases of equine laminitis. *Equine Vet J Suppl* **26**, 119-124.

- Pratt, S.E., Geor, R.J. and McCutcheon, L.J. (2006) Effects of dietary energy source and physical conditioning on insulin sensitivity and glucose tolerance in Standardbred horses. *Equine Exercise Physiology* **36**, 579-584.
- Reeves, H.J., Lees, R. and McGowan, C.M. (2001) Measurement of basal serum insulin concentration in the diagnosis of Cushing's disease in ponies. *Veterinary Record* **149**, 449-452.
- Steward, M.L. (2003) How to construct and apply atraumatic therapeutic shoes to treat acute or chronic laminitis in the horse. In: *American Association of Equine Practitioners 49th Annual Convention.*, New Orleans, Louisiana U.S.A. pp 337-346.
- Treiber, K., Kronfeld, D. and Geor, R. (2006a) Insulin resistance in equids: possible role in laminitis. *J Nutr.* **136**, 2094S-2098S.
- Treiber, K.H., Kronfeld, D.S., Hess, T.M., Byrd, B.M., Splan, R.K. and Staniar, W.B. (2006b) Evaluation of genetic and metabolic predispositions and nutritional risk factors for pasture-associated laminitis in ponies. *Journal of the American Veterinary Medical Association.* **228**, 1538-1545.
- Treiber, K.H., S., K.D. and J., G.R. (2006c) Insulin resistance in equids: possible role in laminitis. *The Journal of Nutrition* **136**, 2094S-20985S.
- Trout, D.R., Hornof, W.J., Linford, R.L.K. and TR, O.B. (1990) Scintigraphic evaluation of digital circulation during the developmental and acute phases of equine laminitis. *Eq.Vet.J.* **22**, 416-421.
- van Eps, A.W. and Pollitt, C.C. (2004) Equine laminitis: cryotherapy reduces the severity of the acute lesion. *Equine Vet J* **36**, 255-260.
- van Eps, A.W. and Pollitt, C.C. (2006) Equine laminitis induced with oligofructose. *Equine Vet J* **38**, 203-208.
- Walsh, D., McGowan, C., McGowan, T., Lamb, S., Schanbacher, B. and Place, N. (2007) Equine Cushing's disease / equine metabolic syndrome: a practitioner field study. In: *The Fourth International Equine Conference on Laminitis and Diseases of the Foot.*, West Palm Beach, Florida, USA.
- Wattle, O. and Pollitt, C.C. (2004) Lamellar metabolism. *Clinical techniques in equine practice* **4**, 22-33.
- Watts, K.A. and Chatterton, N.J. (2004) A review of factors affecting carbohydrate levels in forage. *J. Equine Vet. Sci.* **24**, 84-86.

Appendix 1: Farrier Supplies

Clarke Horseshoes Pty Ltd

10 Dennes St
Wingham
NSW 2429
Ph: (02) 65534559
Fax: (02) 65570441
E-mail: clarkehs@midcoast.com.au

Combined Farrier Supplies

485 Cull Rd
Serpentine
WA 6125
Ph: (08) 95252478
Fax: (08) 95252906
E-mail: combinedfarriers@iprimus.com.au

Grinter Wholesale Trading Pty Ltd

PO Box 312
Woodend
VIC 3442
Ph: (03) 54272399
Fax: (03) 54271978
E-mail: grinters@iprimus.com.au

Hooftech Pty Ltd

111 Main St
Hahndorf
SA 5245
Ph: (08) 81881188
Fax: (08) 81881199
E-mail: hooftech@chariot.com.au

Independent Farrier Supplies Pty Ltd

20/104 Old Pittwater Rd
Brookvale
NSW 2100
Ph: (02) 99381400
Fax: (02) 99055908
E-mail: Horseshoe.com@bigpond.com

O'Dwyer Horseshoe Aust Pty Ltd

10 Willowmavin Rd
Kilmore
VIC 3764
Ph: (03) 57821313
Fax: (03) 57822399
E-mail: sales@odwyers.com.au
Web: www.odwyers.com.au

Saddlery Wholesalers Pty Ltd

14 Carbine St
Belmont
WA 6104
Ph: (08) 92772624
Fax: (08) 94782904
E-mail: saddlery@one.net.au

Stockmans Supplies Pty Ltd

Unit 2/193 Hedley Ave
Hendra,
Brisbane
QLD 4011
Ph: (07) 32686400
Fax: (07) 32682685
E-mail: stockman@eis.net.au

Appendix 2: RMAX (manufacturer of beaded polystyrene foam products)

Addresses of suppliers:

Webpage www.rmax.com.au

Bundaberg: Steptoe St., 4670. Phone (07) 4152 6866. Fax (07) 4152 6796.

Queensland: 236 Musgrave Rd., Coopers Plains, 4108. Phone (07) 3277 4522. Fax (07) 3277 7761.

New South Wales: 27 Chifley St., Smithfield, 2164. Phone (02) 9609 6088. Fax (02) 9604 7747.

Victoria: Mephan St., Footscray, 3011. Phone (03) 9318 4422. Fax (03) 9317 7888.

South Australia: Peachey Rd., Elizabeth West, 5113. Phone (08) 8255 8022. Fax (08) 8255 7939.

Western Australia: 5 Balwin St., Kewdale, 6105. Phone (08) 9353 1000. Fax (08) 9353 2002.

New Zealand: Barnes Plastics, 368 Church St., Penrose, Auckland 6. Phone (09) 579 9725. Fax (09) 579 0472.

Halas Dental Ltd (Coltene Lab Putty)

Ph: **1300 65 88 22** Fax: **1300 65 88 10** email: info@henryschein.com.au

Addresses and phone/fax numbers of suppliers:

New South Wales: 44 O'Dea Ave., Waterloo, 2017. Phone (02) 9697 6288. Fax (02) 9697 6250.

Queensland: Cnr Merivale & Tribune St., South Brisbane 4104. Phone (07) 3844 2591. Fax (07) 3844 4726

Victoria: 423 Smith St, Fitzroy 3065. Phone (03) 8417 6300. Fax (03) 9416 3853

South Australia: 124-126 Fullarton Rd, Norwood 5067. Phone (08) 8431 4344. Fax (08) 8364 0995.

Western Australia: 154 Edward St., Perth 6000. Phone (08) 9328 1644. Fax (08) 9328 8806.

Tasmania: Phone (03) 6267 1163. Fax (03) 6267 1163

Cryotherapy Supplies

Heat exchange apparatus: Thermoline Scientific. Northgate, Qld 4013. Australia. <http://www.thermoline.com.au/>.

Equine diaper (Equisan Marketing Pty Ltd., South Melbourne, Vic 3205 Australia. <http://www.equisan.com.au/>

Bigfoot Ice Boot: Contact Pam O'Keefe, Esk, Queensland email pamatesk@hotmail.com <http://www.bigfooticeboots.com/>

Grazing Muzzle

Grazing muzzle (VET2295X): Saddlery Trading Company, 124 Tennyson Memorial Avenue, Tennyson Qld, Australia 4105. www.saddlerytrading.com

Veterinary Drugs

Anti-endotoxin hyperimmune plasma (Equiplas. Plasvacc Pty Ltd, Kalbar Q 4309. <http://www.plasvacc.com>)

Flunixin meglumine (Finadyne), Schering-Plough Animal Health.

Phenylbutazone (Nabudone P (Intravenous), Ilium Veterinary Products.

Phenylbutazone (Butin antiinflammatory oral paste), Parnell Laboratories (Australia) Pty. Ltd.

Isoxuprine hydrochloride (Circulon Paste) , Vetsearch International Pty.Ltd.

Acepromazine (Promex 10 injection), Apex Laboratories Pty. Ltd.

FounderGuard, Virbac Australia, Milperra, NSW 2214, <http://www.virbac.com.au/>

Appendix 3

Publications and presentations associated with this research

ASPLIN K.E., MCGOWAN C.M., POLLITT C.C., CURLEWIS J. and SILLENCE M.N. (2007) Role of insulin in glucose uptake in the equine hoof. Proceedings of the American College of Veterinary Internal Medicine 25th Anniversary Forum, June 2007, Seattle WA USA.

ASPLIN K.E., SILLENCE M.N., POLLITT C.C. and MCGOWAN C.M. (2007) Induction of laminitis with insulin in healthy ponies. Proceedings of the British Equine Veterinary Association Congress, Sept 2007, Edinburgh UK.

ASPLIN K.E., SILLENCE, M.N., POLLITT, C.C., and MCGOWAN C.M. (2007) Induction of laminitis by prolonged hyperinsulinaemia in clinically normal ponies. *Vet J* 174,530-535

MILINOVICH G.J., TROTT D.J., BURRELL, P.C., CROSER E.L., AL JASSIM R.A.M., MORTON, J.M., VAN EPS A.W. and POLLITT C.C. (2007) Fluorescence in situ hybridization analysis of hindgut bacteria associated with the development of equine laminitis. *Environmental Microbiology* 9: 2090-2100.

BELKNAP, J.K.; GIGUÈRE, S.; PETTIGREW, A.; COCHRAN, A.M.; VAN EPS, A.W.; POLLITT C. C. (2007) Lamellar pro-inflammatory cytokine expression patterns in laminitis at the developmental stage and at the onset of lameness: innate vs. adaptive immune response. *Equine vet.J.* 39:42-47.

NOURIAN, A.R., BALDWIN, G. I., VAN EPS A. W. and POLLITT C. C. (2006) Equine laminitis: ultrastructural lesions detected 24–30 hours after induction with oligofructose. *Equine vet. J.* (2007) 39:360-364.

ASPLIN K.E., MCGOWAN C.M., POLLITT C.C., CURLEWIS J. and SILLENCE M.N. (2006) Glucose uptake in the equine hoof. Proceedings of the Australian Equine Science Symposium, June 2006, Gold Coast Qld, Vol. 1, p26.

CROSER E.L. and C.C. POLLITT (2006) Acute Laminitis: Descriptive Evaluation of Serial Hoof Biopsies. Pp. 542-546. In: American Association of Equine Practitioners 52nd Annual Convention Proceedings, Dec 2-6, San Antonio, Texas, U.S.A.

MILINOVICH, G. J., TROTT, D. J, BURRELL, P. C., VAN EPS, A. W., THOEFNER, M. B., BLACKALL, L. L., AL JASSIM, R. A. M., MORTON J. M. and POLLITT, C. C. (2006) Changes in Equine Hindgut Bacterial Populations during Oligofructose-Induced Laminitis. *Environmental Microbiology* 8: 885–898.

KELLER, M. D., GALLOWAY, G. J. and POLLITT, C. C. (2006) Magnetic resonance microscopy of the equine hoof wall. *Equine vet.J.* 38:461-466.

VAN EPS, A and POLLITT, C.C. (2006) Equine laminitis: induction with oligofructose. *Equine vet. J.* 38:203-208.

ASPLIN K.E., BEVAN B.E., MCGOWAN C.M., POLLITT C.C. and SILLENCE M.N. (2005) Glucose uptake in the equine hoof. Proceedings of the Nutrition Society of Australia, Dec 2005, Melbourne Vic., *Asia Pacific Journal of Clinical Nutrition* 14 (Suppl.): S62.

POLLITT, C.C. (2004) Anatomy and physiology of the hoof wall. *Clinical techniques in equine practice.* 4: 3-21.

- POLLITT, C.C. (2004) Equine Laminitis. *Clinical Techniques In Equine Practice*. 4: 34-56.
- VAN EPS, A. W., WALTERS, L.J., BALDWIN, G.I., MCGARRY, M., and POLLITT, C.C. (2004) Distal limb cryotherapy for the prevention of acute laminitis. *Clinical Techniques In Equine Practice*. 4: 64-70.
- WATTLE, O and POLLITT, C. C. (2004) Lamellar metabolism. *Clinical Techniques In Equine Practice*.
- POLLITT, C.C. and DARADKA, M. (2004) Hoof wall wound repair. *Equine vet. J.* 36:210-215.
- KYAW TANNER, M., and POLLITT, C. C. (2004) Equine laminitis: increased transcription of matrix metalloproteinase-2 (MMP-2) occurs during the developmental phase. *Equine vet. J.* 36: 221-225.
- DARADKA, M. & POLLITT, C.C. (2004) Epidermal cell proliferation in the equine hoof wall. *Equine vet.J.* 36: 236-241.
- FRENCH, K.R. and POLLITT, C.C. (2004) Equine laminitis: glucose deprivation and MMP activation induce dermo-epidermal separation in vitro. *Equine vet. J.* 36: 261-266.
- FRENCH, K.R. and POLLITT, C.C. (2004) Equine laminitis: loss of hemidesmosome ultrastructure correlates to dose in an oligofructose induction model. *Equine vet. J.* 36: 230-235.
- FRENCH, K.R. and POLLITT, C.C. (2004) Equine laminitis: cleavage of key hemidesmosome proteins associated with basement membrane dysadhesion. *Equine vet. J.* 36: 242-247.
- FRENCH, K.R. & POLLITT, C.C. (2004) Equine laminitis: congenital, hemidesmosomal plectin deficiency in a Quarter Horse foal. *Equine vet. J.* 36: 299-303.
- POLLITT, C.C. and VAN EPS A.W. (2004). Prolonged, continuous distal limb cryotherapy in the horse. *Equine vet. J.* 36: 216-220
- VAN EPS, A.W. and POLLITT, C.C. (2004) Equine laminitis: cryotherapy reduces the severity of the acute lesion. *Equine vet. J.* 36: 255-260.
- POLLITT, C.C., KYAW-TANNER, M., FRENCH, K.R. VAN EPS, A.R. HENDRIKZ, J.R and DARADKA, M. (2003) Equine Laminitis: American Association of Equine Practitioners 49th Annual Convention Proceedings, Nov 21 – 25, New Orleans, Louisiana U.S.A.
- MUNGALL, B.A. and POLLITT, C.C. (2002) Thermolysin activates equine lamellar hoof matrix metalloproteinases. *J. Comp. Path.* 126: 9-16.
- MUNGALL, B.A. and POLLITT C.C (2001) In situ zymography: topographical considerations. *J.Biochem. Biophys. Methods* 47: 169-176.
- MUNGALL, B.A., KYAW-TANNER, M. and POLLITT.C.C. (2001) In vitro evidence for a bacterial pathogenesis of equine laminitis. *Vet. Microbiol.* 2070: 1-15.
- MUNGALL, B.A., POLLITT C.C and COLLINS, RITA (1998) Localisation of gelatinase activity in epidermal hoof lamellae by in situ zymography. *Histochem. Cell Biol.* 110: 535-540.
- POLLITT, C. C. and DAVIES, C. T. (1998) Equine laminitis: its development post alimentary carbohydrate overload coincides with increased sublamellar bloodflow. *Equine vet. J., Suppl.* 26: 125-132.

PASS, M.A., POLLITT, S. and POLLITT, C.C. (1998) Changes in glucose metabolism: a trigger for laminitis. *Equine vet. J., Suppl.26:* 133-138.

POLLITT, C. C. and DARADKA, M. (1998) Equine laminitis basement membrane pathology: loss of type IV collagen, type VII collagen and laminin immunostaining. *Equine vet. J., Suppl 26:* 139-144.

POLLITT, C.C., PASS, M.A. and POLLITT, S. (1998) Batimastat inhibits matrix metalloproteinases of equine laminitis. *Equine vet. J., Suppl. 26:* 119-124.

POLLITT, C.C. (1996) Basement membrane pathology: a feature of equine laminitis. *Equine vet. J.* 28 (1) 38-46.

MOLYNEUX, G.S., HALLER, C.J., MOGG, K.C. and POLLITT, C.C. (1994) The structure, innervation and location of arteriovenous anastomoses in the equine foot. *Equine vet. J.* 26: 305-312.

POLLITT, C.C. (1994) The basement membrane at the equine hoof dermal epidermal junction. *Equine vet. J.* 26:399-407.

Books and chapters in books

POLLITT, C.C. (2007) "Laminitis" in *Equine Emergencies: Treatment and Procedures*. 3rd Edition Editors; Orsini, JA and Diver, TJ. pp. 627-633. Saunders ISBN: 978-1-4160-3609-8.

POLLITT, C.C. (2007) Chapter 6; Microscopic anatomy and physiology of the hoof. Chapter 15; Laminitis pathophysiology. In: *Equine Podiatry*. Editors; AE Floyd and RA Mansmann. Saunders, St Louis, MO. LCCN 2007921733.

POLLITT, C.C. (2002) Laminitis. In: 1st edition *Diagnosis and Management of Lameness in the Horse*. Editors; M. W. Ross and S. J. Dyson. Saunders. Philadelphia.

POLLITT, C.C. (2001) *Equine Laminitis*. Publication No. 01/129. ISBN 064258346X. ISSN 1440-6845. RIRDC Canberra.

POLLITT, C. C. (1999) Laminitis. In: 5th Edition *Equine Medicine & Surgery*. Edited by Moore, J. and Mayhew, I. Saunders, Philadelphia.

POLLITT, C. C. (1999) *Color Atlas of the Horse's Foot – Japanese translation* by A. Kawano, Japanese equine research institute ISBN 4-901071-04-1.

POLLITT, C. C. (1999) *Farbatlas Huf, Anatomie und Klinik (Color Atlas of the Horse's Foot – German translation* by Klaus-Dieter Budras and Bodo Hertsch). Schlutersche Hannover. ISBN 3-87706-536-8.

POLLITT, C. C. (1999) *El Pie del Caballo, Atlas en color. (Color Atlas of the Horse's Foot – Spanish translation* by Manuel R. Sanchez. sponsored by Mustad Hoofcare S.A. ISBN 84-8174-397-6. Harcourt Brace, Madrid.

POLLITT, C. C. (1995) *Color Atlas of the Horse's Foot*. ISBN 0-7234- 1765 2 Mosby-Wolfe, London. 205 pages.

Equine Laminitis

Current Concepts

by Chris Pollitt

08/062

Laminitis is a painful and devastating disease that can cripple a horse and end its productive life. There has been a considerable amount of research over recent years to try to understand laminitis, but scientists have struggled to reconcile the wide range of apparently unrelated factors which can trigger the condition.

This report describes four research projects that initially focussed on the developmental and acute stages of laminitis. The research teams involved in these projects included microbiologists, molecular biologists, pathologists, electron microscopists, physiologists and endocrinologists, and this unique critical mass has enabled significant contributions to the understanding of laminitis. As new knowledge accrued a successful preventive strategy, employing distal limb cryotherapy, was developed that is now the only scientifically proven laminitis preventive.

The importance of this report is that it provides an overview of laminitis for horse owners, veterinarians and scientists. It describes the anatomy, physiology and ultrastructure of the horse's foot to form a basis for understanding the complex pathology that underpins the disease. It describes the radiology of the horse's foot and introduces the new technique of retrograde venography.

This report is part of RIRDC's Horse R&D Program which aims to assist in developing the Australian horse industry and enhancing its export potential.

Most of our publications are available for viewing, downloading or purchasing online through our website:

www.rirdc.gov.au



Equine Laminitis — Current Concepts